

CASE REPORT

Apathetic syndrome from carotid dissection: a dangerous condition

Carmela Gerace,¹ Fabio Massimo Corsi,² Giovanna Comanducci²

¹Department of Neurology, Azienda Ospedaliera S.Camillo-Forlanini, Roma, Italy
²Department of Neurosciences, Azienda Ospedaliera S.Camillo-Forlanini, Roma, Italy

Correspondence to
 Dr Carmela Gerace,
 c.gerace@tiscali.it

SUMMARY

Isolated behavioural disturbances can mimic psychiatric diseases and delay diagnosis of acute brain disease. We reported the case of a patient with carotid dissection manifesting only with apathetic syndrome that was initially considered as a possible postpartum depression, causing a threatening diagnostic delay.

BACKGROUND

Sometimes acute ischaemic lesions of the brain manifest themselves only with behavioural disturbances. In these cases, a diagnosis can be delayed with dangerous effects for the patient. Apathy is a well known symptom of stroke, but it has been described in patients after the acute phase of the disease. We did not find other case in which it has been the first and sole manifestation in patients with acute ischaemic brain damage.

CASE PRESENTATION

A 27-year-old woman was referred to emergency room for behavioural disturbances. She had delivered a healthy child 12 days before, the delivery went well and it did not last too long. Then she had become indifferent for 3 days, since she had headache for 1 day. Her husband described that she was often quiet, distant, she did not even talk with him naturally, sometimes she answered with strange words to his questions and it appeared she could not explain her behaviour.

Her medical history was unremarkable and she did not take any medicine.

She had no fever and the brain CT and laboratory blood examinations were normal.

A postpartum depressive disorder was supposed based only on behavioural symptoms of the patient and her recent delivery because there were no other social, familiar or psychiatric risk factors for depression. She was referred to a psychiatrist who did not fully agree with diagnosis of depressive disorder. The patient was then visited by a neurologist who noticed a very mild aphasic expressive disorder together with apathetic behaviour and sent the patient to the emergency room for immediate investigations about possible left hemispheric lesion.

INVESTIGATIONS

Brain MRI and MRI angiography, performed after 12 h from patient's arrival in the emergency room, showed acute ischaemic stroke in the head of the left caudate nucleus and left internal carotid artery

(ICA) dissection with apparent loss of flow of middle cerebral artery (MCA; figure 1).

TREATMENT

Anticoagulant treatment and blood pressure monitoring were immediately started.

OUTCOME AND FOLLOW-UP

On the second day after admission to neurology department the patient was alert, responsive, motor and verbal inertia with decreased spontaneous activity were evident, the speech was non-fluent (rare anomias and prolonged latency in responding to questions), with preserved comprehension, repetition while writing and reading. Mini-Mental State Examination was 29/30; no other neurological signs were present. After 1 month the patient was well and there were no symptoms in her daily life activities; only mild inertia was present.

DISCUSSION

ICA dissection is a frequent cause of stroke in young patients.¹ Risk factors that can lead to dissection include a neck injury and diseases of the inner wall of the artery. The reason why dissection occurred in our otherwise healthy young patient is unknown, but we could consider significant, as risk factor, possible neck movements and strains related to her recent delivery. Common symptoms in a carotid dissection are cervical pain and headache, Horner's syndrome, paralysis of the cranial nerves and subsequently cerebral and retinal ischaemia. Carotid artery dissection may be associated with permanent deficits or even fatal outcomes due to central nervous system ischaemia. Multiple lesions are often evident with diffusion-weighted MRI in many patients with carotid dissection. This observation would favour anticoagulation in prevention and treatment of stroke from carotid dissection because it suggests that artery-to-artery embolism rather than haemodynamic compromise is the main underlying mechanism in carotid dissection stroke.² Our patient's MRI angiography showed signs of ICA dissection and apparent loss of flow of MCA while an ischaemic lesion only developed in the caudate head. Possible explanations of this finding are the following:

1. Embolic occlusion, distal to the dissection flap, of the penetrating artery nourishing the caudate head while the MCA is not occluded but the blood flow is markedly lowered and slow, being insufficient to give the 'signal void' in MRI imaging, but enough to avoid ischaemic lesion of MCA territory.

To cite: Gerace C, Corsi FM, Comanducci G. *BMJ Case Rep* Published online: [please include Day Month Year] doi:10.1136/bcr-2013-009686

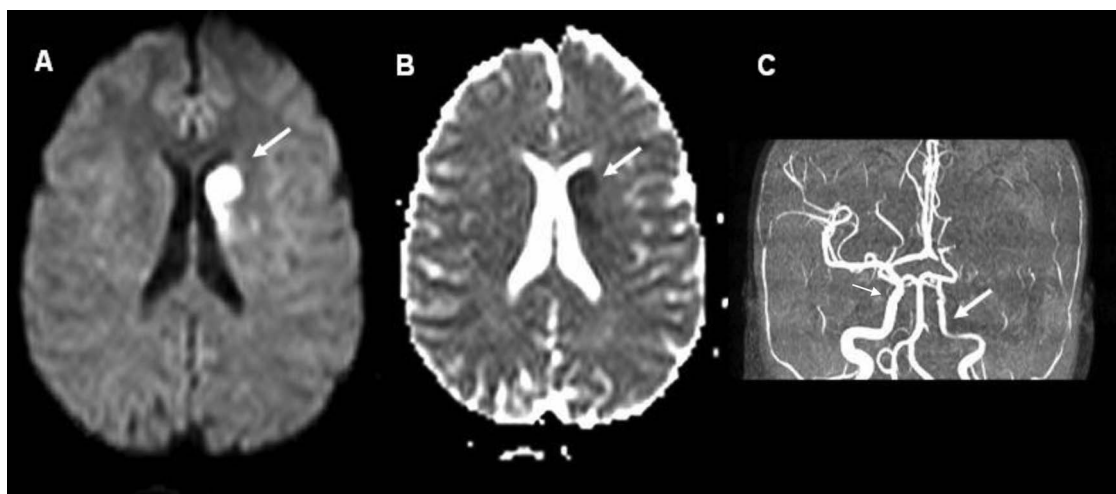


Figure 1 MRI axial diffusion-weighted imaging sequences (A) and apparent diffusion coefficient (B) with acute ischaemic infarct of the head of left caudate nucleus (arrow); MRI angiography (C) with left internal carotid dissection (large arrow) and normal right carotid (small arrow).

2. Global hypoperfusion of the left hemispheric ICA territory with haemodynamic lesion only in caudate head due to local critic unbalance between oxygen and substrate need and blood flow.

The most prominent clinical features of caudate vascular lesions are behavioural and cognitive abnormalities, more often apathy and abulia, characterised by decreased spontaneous activity and prolonged latency in responding to questions and other stimuli. These clinical findings are caused by dysfunction of cortical zones due to loss of striatal efferent projections from the caudate nucleus.³ It has been reported that about half of apathetic patients could remain in this condition for a long time. Apathy can be more evident when associated with older age and cognitive impairment.⁴

Contributors CG gave substantial contribution to the conception and design, acquisition of the data, interpretation of the data and drafting the article. FMC gave substantial contribution in revising manuscript and to the final approval of the version published. GC gave contribution in revising manuscript.

Competing interests None.

Patient consent Obtained.

Provenance and peer review Not commissioned; externally peer reviewed.

REFERENCES

- 1 Rubinstein M, Peerdeman Saskia M, van Tulder Maurits W, *et al*. A systematic review of the risk factors for cervical artery dissection Sidney. *Stroke* 2005;36:1575–80.
- 2 Engelter Stefan T, Brandt T, Debette S, *et al*. For the Cervical Artery Dissection in Ischemic Stroke Patients (CADISP) Study Group. Antiplatelets versus anticoagulation in cervical artery dissection. *Stroke* 2007;38:2605–11.
- 3 Emre K, Dilek E, Kaan B. Acute caudate vascular lesions. *Stroke* 1999;30:100–8.
- 4 Caeiro JL, Ferro JM, Costa J. Apathy secondary to stroke: a systematic review and meta-analysis. *Cerebrovasc Dis* 2013;35:23–39.
- 5 Starkstein SE, Leentjens AFG. The nosological position of apathy in clinical practice. *J Neurol Neurosurg Psychiatry* 2008;79:1088–92.

Learning points

- ▶ Apathy secondary to stroke is a more frequent neuropsychiatric disturbance than depression.
- ▶ Patient history is always very important, especially when a patient manifests behavioural or cognitive disturbances.
- ▶ Although apathic-abulic syndrome can be a symptom of psychiatric disease, it is also very often found in a great variety of neurological and medical conditions.⁵
- ▶ Correct identification of isolated neurological apathy and its causes can be challenging in the emergency department.
- ▶ In this patient diagnostic delay due to misinterpretation of apathetic symptoms could be very dangerous because diagnostic delay of carotid dissection can provoke increased morbidity and mortality.

Copyright 2013 BMJ Publishing Group. All rights reserved. For permission to reuse any of this content visit <http://group.bmj.com/group/rights-licensing/permissions>.
BMJ Case Report Fellows may re-use this article for personal use and teaching without any further permission.

Become a Fellow of BMJ Case Reports today and you can:

- ▶ Submit as many cases as you like
- ▶ Enjoy fast sympathetic peer review and rapid publication of accepted articles
- ▶ Access all the published articles
- ▶ Re-use any of the published material for personal use and teaching without further permission

For information on Institutional Fellowships contact consortiasales@bmjgroup.com

Visit casereports.bmj.com for more articles like this and to become a Fellow