

CASE REPORT

Intact neurological outcome after neurointerventional treatment for intracranial venous thrombosis with straight sinus involvement

M Sidhu,¹ D Footitt,² I Donaldson,³ S Hughes,⁴ S Wuppalapati,⁵ H C A Emsley^{6,7}

¹Department of Clinical and Experimental Epilepsy, UCL/Institute of Neurology, London, UK

²Cumbria Partnership NHS Foundation Trust, Cumbria, UK

³Anaesthetics Directorate, Royal Preston Hospital, Preston, UK

⁴Department of Obstetrics and Gynaecology, Royal Preston Hospital, Preston, UK

⁵Department of Neurointervention, Royal Preston Hospital, Preston, UK

⁶Department of Neurology, Royal Preston Hospital, Preston, UK

⁷University of Manchester, Manchester, UK

Correspondence to

Dr H C A Emsley, hedley.emsley@manchester.ac.uk

SUMMARY

The role of neurointerventional treatment, including local thrombolysis, for intracranial venous thrombosis (ICVT) currently remains uncertain. We describe a case of postpartum ICVT involving the straight sinus, with rapid neurological deterioration and progressive thrombosis, despite anticoagulation. She underwent multimodality neurointerventional treatment involving attempted mechanical clot disruption, microcatheter suction, intrathrombus thrombolysis and microballoon disruption and clot retrieval. The patient achieved a full clinical recovery, with radiological evidence of recanalisation at follow-up.

BACKGROUND

The role of neurointerventional treatment, including local thrombolysis, for intracranial venous thrombosis (ICVT) currently remains uncertain. However, we describe a case with excellent clinical outcome where neurointerventional treatment was given for straight sinus thrombosis because prognosis was likely to be poor despite adequate anticoagulation (AC).

CASE PRESENTATION

A 23-year-old Asian woman with sickle cell trait, and 2 weeks postpartum, developed headache of 5-day duration followed by rapidly evolving vomiting, dysphagia, behavioural change, reduced conscious level, ophthalmoplegia and absent gag reflex.

Her family described a preceding 5-day history of an escalating bifrontal headache. On the morning of her admission, she displayed bizarre behaviour and was described to be 'muddled'. Her right leg was noted to be jerking intermittently. Her initial Glasgow Coma Scale was 10 (E3, V1, M6). She was notably confused and agitated. Pupils were equal and reactive to light. There was a left, 6th nerve palsy. No papilloedema was seen. There was marked sialorrhoea, symmetrical poverty of pharyngeal elevation and an absent gag reflex. Peripherally, she was neurologically intact with flexor plantar responses.

INVESTIGATIONS

The clinical suspicion of ICVT was confirmed on her initial CT scan which showed a cord sign (figure 1). Neurological advice was sought and she was started on intravenous heparin and phenytoin. Given her rapidly deteriorating neurological condition, she was sedated, intubated and transferred the same day to our neurosciences centre, direct to the neurointerventional suite. Given 5 h had elapsed from initial CT, intracerebral haemorrhage (ICH) was excluded on a CT scanogram (figure 2), but this scan did reveal bithalamic low attenuation consistent with venous congestion. Cerebral angiography confirmed thrombus in the cerebral venous system including the straight sinus (figure 3). The straight sinus was not filling on the vertebral and bilateral carotid angiograms. Thrombus was seen in the left transverse sigmoid junction and left medial

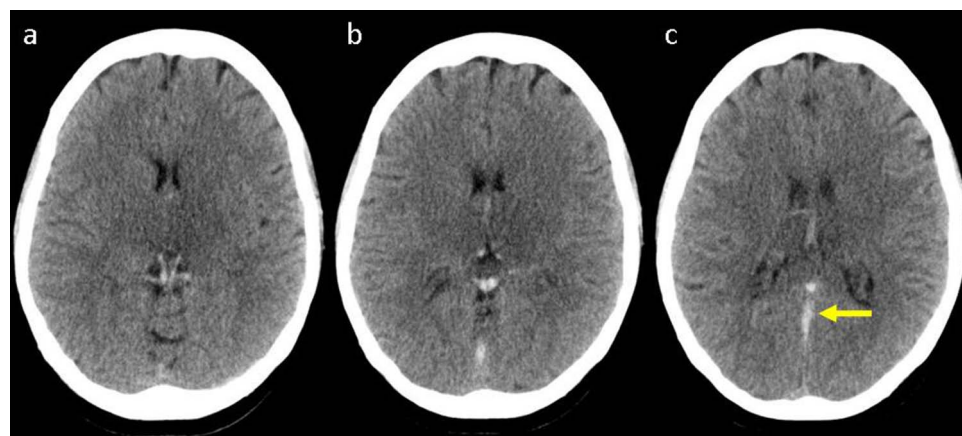


Figure 1 Axial unenhanced CT scans acquired at presentation showing acute thrombus with internal cerebral veins and veins of Rosenthal (A), vein of Galen and straight sinus (B) and straight sinus with cord sign (C, arrowed).

To cite: Sidhu M, Footitt D, Donaldson I, et al. *BMJ Case Rep* Published online: [please include Day Month Year] doi:10.1136/bcr-2013-010242

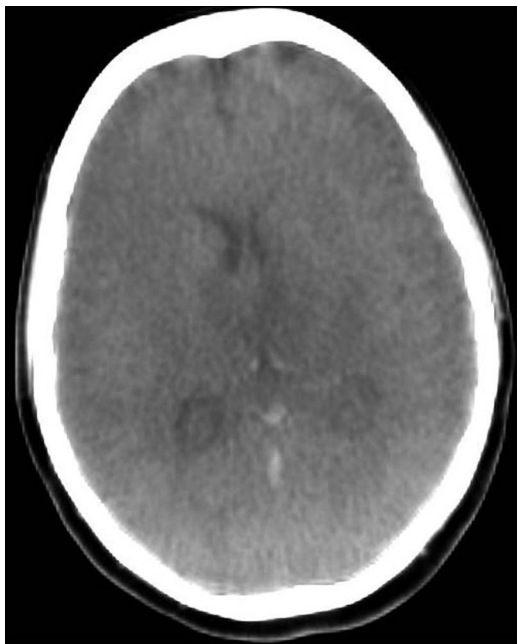


Figure 2 Axial scanogram acquired on a biplane neurovascular X-ray system (Philips Allura XperCT) showing bithalamic low attenuation and cord sign (image degraded by artefact).

transverse sinus. All the veins from thalamostriate to the internal cerebral vein were ‘hanging in space’. The left sylvian vein showed stasis and was not draining adequately. She remained sedated and any further neurological assessment off sedation would have introduced considerable delay. Coupled with her likely poor prognosis without effective recanalisation and radiological features of progressive thrombosis, the decision was taken to proceed with neurointerventional treatment to facilitate recanalisation.

TREATMENT

Following guidewire insertion (Terumo Medical, Somerset, New Jersey, USA; figure 4), mechanical clot disruption and withdrawal was attempted first using a Penumbra System (PS) (Penumbra, Alameda, California, USA) followed by the use of a Solitaire AB stent (ev3 Inc, Irvine, California, USA) with

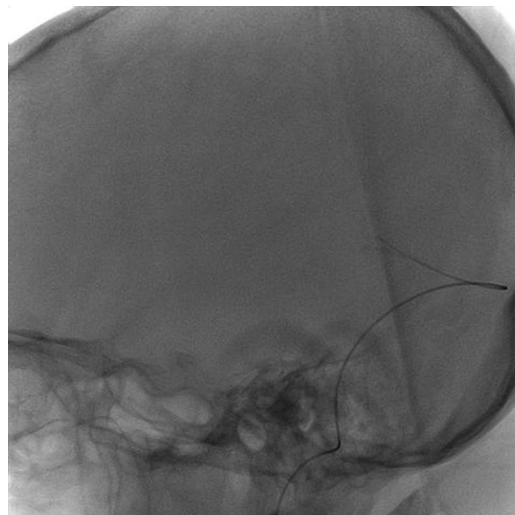


Figure 4 Angiogram showing position of guidewire (tip within straight sinus).

attempted suction through microcatheter (Prowler select plus catheter, Cordis Corporation, Bridgewater, New Jersey, USA). Because these attempts failed to achieve recanalisation (figure 5), intrathrombus recombinant tissue plasminogen activator (r-tPA) was administered through microcatheter. In total 5 mg was administered over 40 mins. This was then followed by microballoon (Eclipse 7, BALT, Montmorency, France) clot disruption/retrieval. There appeared to be partial recanalisation of the straight sinus albeit with evidence of clot migration to the left transverse sinus (figure 6).

OUTCOME AND FOLLOW-UP

A CT venogram 18 h postprocedure confirmed partial recanalisation (figure 7). She was successfully extubated 48 h postneurointervention, neurologically intact and was discharged home a week later on oral AC with warfarin. CT venogram appearances 6 months later were much improved (figure 8).

DISCUSSION

ICVT is a rare but potentially lethal condition that can occur in any age group including neonates. Estimated annual incidence is

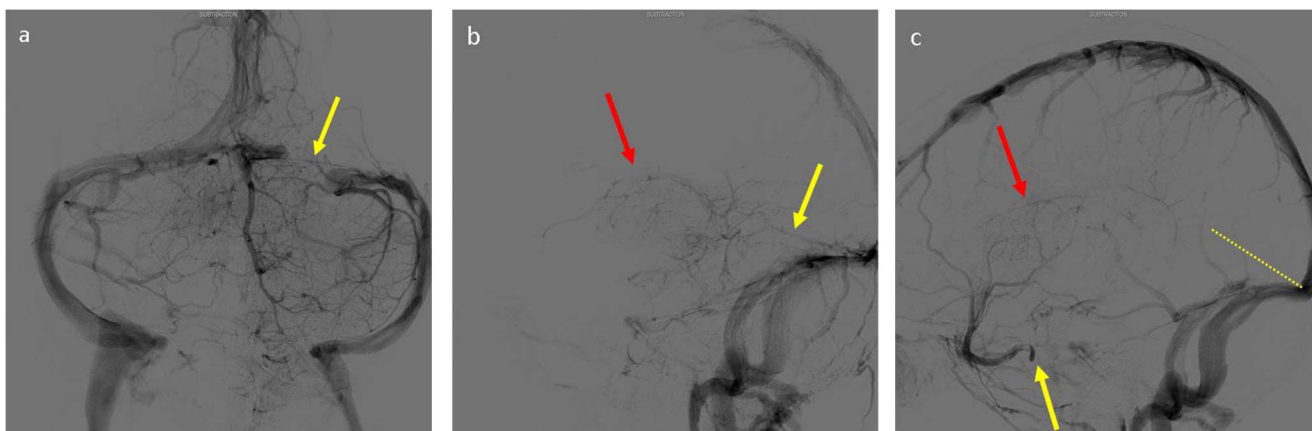


Figure 3 (A) Pretreatment angiogram (left vertebral artery Towne view) showing filling defect within left transverse sinus, arrowed. (B) Pretreatment angiogram (left vertebral artery lateral view) showing absence of straight sinus (arrowed, yellow) and disconnection of internal cerebral veins, seen ‘hanging in space’ (arrowed, red). (C) Pretreatment angiogram (left internal carotid artery lateral view) showing absence of straight sinus (dotted yellow line depicts expected position of straight sinus), disconnection of internal cerebral veins, seen ‘hanging in space’ (arrowed, red) and stagnation in Sylvian vein (arrowed, yellow).

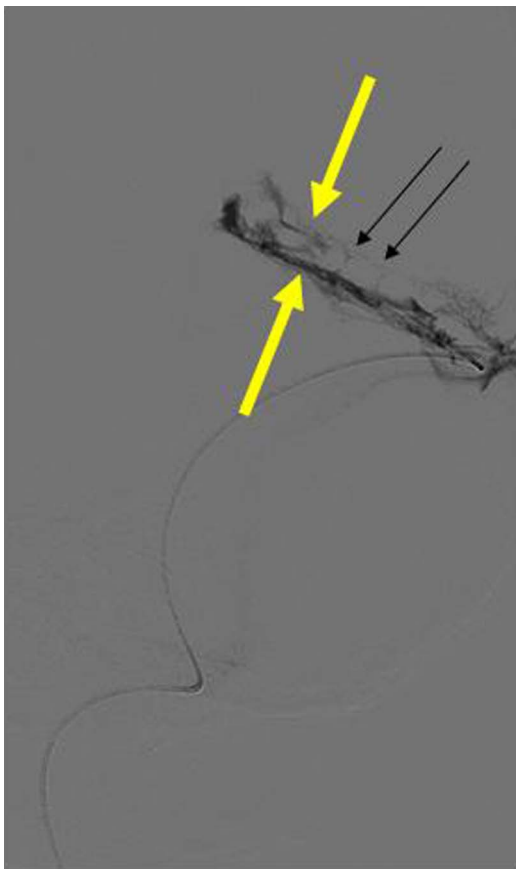


Figure 5 Angiogram showing microcatheter within straight sinus postdeployment of solitary stent and demonstrating extent of remaining thrombus within sinus (yellow arrows indicate inferior and superior margins); contrast seen more prominently towards inferior margin corresponding to area of greatest mechanical clot disruption. Septation of thrombus can also be seen (black arrows).

3–4 cases per 1 million population and up to 7 cases per million among children. About 75% of the adult patients are women.¹ ICVT accounts for <0.5% of cases of all strokes.

Causes of ICVT are extremely variable. In the majority of patients, a factor predisposing to thrombosis can be identified. The greater incidence in women appears to be due to risk factors such as pregnancy, puerperium, the oral contraceptive pill and hormone replacement therapy. Other predisposing factors include infections (eg mastoiditis/sinusitis), hypercoagulable states, inherited prothrombotic tendencies, blood dyscrasias and malignancy. Thromboembolic complications are exceedingly rare in patients with sickle cell trait and nevertheless ICVT has previously been described in this setting.²

Clinical features are varied, including headache (95%), other features of raised intracranial pressure such as vomiting, seizures (47%), altered behaviour, decline in conscious level (39%), papilloedema (43%) and cranial nerve palsies.³ Seizures are generally focal with secondary generalisation and are more commonly seen than in arterial stroke. If the thalami are affected, there may be behavioural symptoms (eg delirium, amnesia and mutism). Venous congestion can lead to venous infarction with or without haemorrhage, cerebral oedema, herniation and death. In a study of 54 patients, poor outcome at 12-week was associated with patients presenting with papilloedema, coma or altered consciousness, age >33 years, diagnostic delay >10 days, ICH and involvement of the straight sinus.³

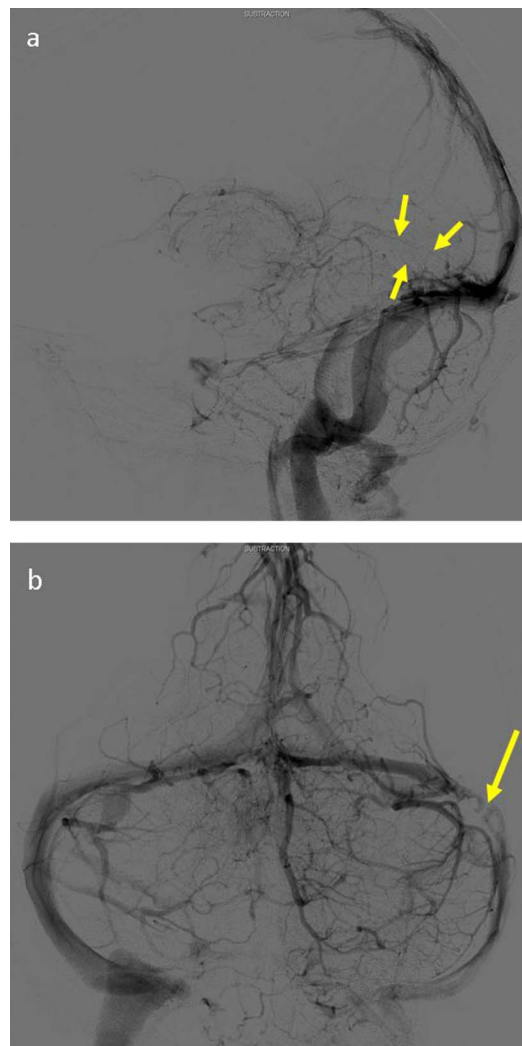


Figure 6 (A) Vertebral angiogram (venous phase) post-thrombolysis showing outline of straight sinus (arrowed). (B) Vertebral angiogram (venous phase) (Towne view) showing partial recanalisation with migration of thrombus within left transverse sinus (arrowed).

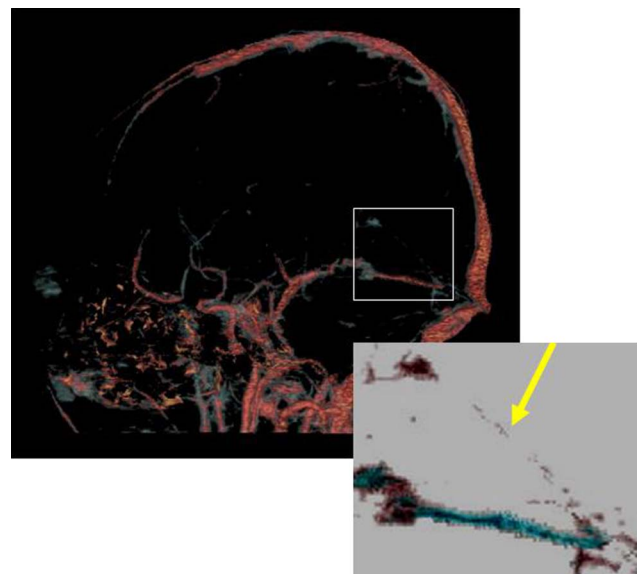


Figure 7 CT venogram 18 h post-treatment showing partial recanalisation of straight sinus (box indicates area of detail shown with inverted colours).

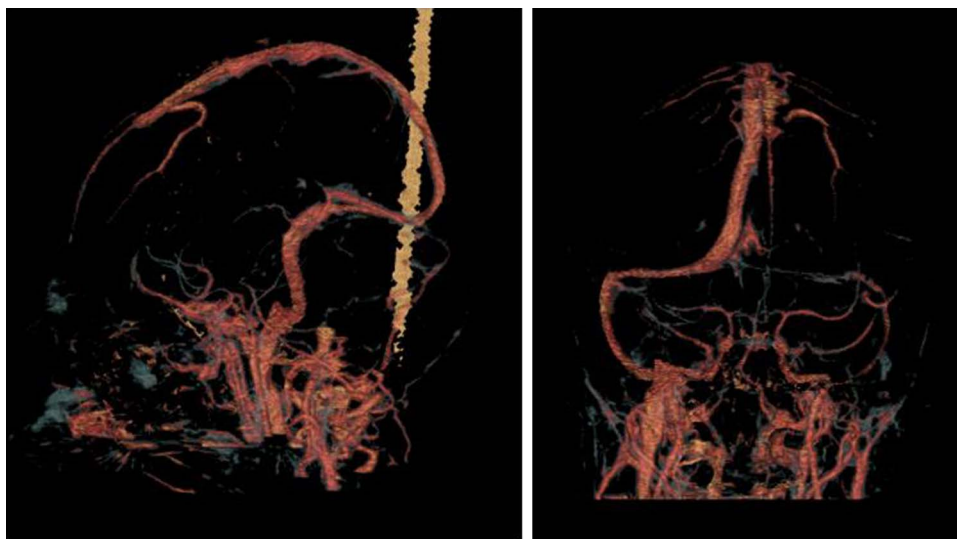


Figure 8 CT venogram 6 months post-treatment showing complete recanalisation of the straight sinus with antegrade flow from the deep veins, and partial recanalisation of the left transverse sinus.

The rationale for treatment is to limit thrombus extension and promote recanalisation. Treatment with AC in the form of subcutaneous low molecular weight heparin or intravenous heparin is widely used.^{4–6} Thrombolysis with urokinase was first used in 1971 with encouraging results.⁷ More recently, r-tPA in combination with heparin has been used due its many theoretical advantages over urokinase: clot selectivity, a short plasma half-life of approximately 5 min and low levels of fibrinogen degradation products. Although there have been promising case reports, there are no randomised controlled trials supporting the use of either local or systemic thrombolysis. Frey *et al* reported a series of 12 patients who received r-tPA at a loading dose of 1 mg/cm as a bolus through a microcatheter along the clot followed by 1–2 mg/h for a mean duration of 29 h delivering a mean dose of 46 mg. Partial or complete flow restoration was seen in nine patients. Recanalisation rates were superior as compared to treatment with heparin alone. Importantly, however, two patients with obvious haemorrhagic infarctions developed haemorrhage extension on the initial doses of treatment.⁸ In a separate study, Kim *et al* used a more aggressive dosing regime that included repeated boluses plus infusion (average dose of 134 mg). Although flow was restored in all (9 patients), major intrapelvic bleeding and minor bleeding from femoral puncture sites were noted.⁹ The European Federation of Neurological Societies guidelines conclude that thrombolysis may be beneficial in patients without ICH or impending herniation from large haemorrhagic infarcts.⁶

We used a similar bolus to that described by Frey *et al* of 1 mg/cm along the length of the clot at intervals of approximately 8 min. Various combinations of endovascular techniques have previously been combined with chemical thrombolysis.^{10–11} Of these reported cases only two patients had straight sinus involvement, both requiring more than one procedure (1 case having 5 procedures had very poor outcome).¹⁰ Recently, the PS was successfully used to treat four cases of ICVT without need for local thrombolysis, although it appears that the straight sinus was not involved in any of these patients.¹² Owing to logistical considerations, it would not have been possible to safely administer a continuous infusion of r-tPA as used by previous groups.

As the angiogram showed recanalisation of the straight sinus post-treatment, we decided to follow-up with intravenous heparin treatment only with an excellent clinical outcome.

Learning points

- ▶ Intracranial venous thrombosis (ICVT) is rare but potentially lethal and rapid, accurate clinicoradiological diagnosis is crucial.
- ▶ Anticoagulation remains the first-line treatment but interventional treatment should be considered for continued neurological deterioration despite adequate anticoagulation.¹³
- ▶ Interventional treatment can facilitate an excellent clinical outcome, including ICVT involving the straight sinus.
- ▶ Multiple interventional treatment modalities may be required during the treatment of a single case.

Contributors MS and HCAE drafted the manuscript; all authors contributed to the content and approved the final version.

Competing interests None.

Patient consent Obtained.

Provenance and peer review Not commissioned; externally peer reviewed.

REFERENCES

- 1 Stam J. Thrombosis of the cerebral veins and sinuses. *N Engl J Med* 2005;352:1791–8.
- 2 Feldenzer JA, Bueche MJ, Venes JL, *et al*. Superior sagittal sinus thrombosis with infarction in sickle cell trait. *Stroke* 1987;18:656–60.
- 3 de Bruin S, de Haan R, Stam J. Clinical features and prognostic factors of cerebral venous sinus thrombosis in a prospective series of 59 patients. *J Neurol Neurosurg Psychiatry* 2001;70:105–8.
- 4 Einhupl KM, Villringer A, Meister W, *et al*. Heparin treatment in sinus venous thrombosis. *Lancet* 1991;338:597–600.
- 5 Stam J, de Bruijn S, deVeber G. Anticoagulation for cerebral sinus thrombosis. *Stroke* 2003;34:1054–5.

- 6 Einhäupl K, Stam J, Bousser MG, *et al.* EFNS guideline on the treatment of cerebral venous and sinus thrombosis in adult patients. *Eur J Neurol* 2010. [Epub ahead of print].
- 7 Vines FS, Davis DO. Clinical and radiological correlation in cerebral venous occlusive disease. *Radiology* 1971;98:9–22.
- 8 Frey JL, Muro GJ, McDougall CG, *et al.* Cerebral venous thrombosis: combined intra-thrombus rtPA and intravenous heparin. *Stroke* 1999;30:489–94.
- 9 Kim SY, Suh JH. Direct endovascular thrombolytic therapy for dural sinus thrombosis: infusion of alteplase. *AJNR Am J Neuroradiol* 1997;18:639–45.
- 10 Baker MD, Opatowsky MJ, Wilson JA, *et al.* Rheolytic catheter and thrombolysis of dural venous sinus thrombosis: a case series. *Neurosurgery* 2001;48:487–93.
- 11 Chaloupka JC, Mangla S, Huddle DC. Use of mechanical thrombolysis via microballoon percutaneous transluminal angioplasty for the treatment of acute dural sinus thrombosis: case presentation and technical report. *Neurosurgery* 1999;45:650–6.
- 12 Choulakian A, Alexander MJ. Mechanical thrombectomy with the penumbra system for treatment of venous sinus thrombosis. *J Neurointerv Surg* 2010;2:153–6.
- 13 Saposnik G, Barinagarrementeria F, Brown RD Jr, *et al.* American Heart Association Stroke Council and the Council on Epidemiology and Prevention. Diagnosis and management of cerebral venous thrombosis: a statement for healthcare professionals from the American Heart Association/American Stroke Association. *Stroke* 2011;42:1158–92.

Copyright 2013 BMJ Publishing Group. All rights reserved. For permission to reuse any of this content visit <http://group.bmj.com/group/rights-licensing/permissions>.
 BMJ Case Report Fellows may re-use this article for personal use and teaching without any further permission.

Become a Fellow of BMJ Case Reports today and you can:

- ▶ Submit as many cases as you like
- ▶ Enjoy fast sympathetic peer review and rapid publication of accepted articles
- ▶ Access all the published articles
- ▶ Re-use any of the published material for personal use and teaching without further permission

For information on Institutional Fellowships contact consortiasales@bmjgroup.com

Visit casereports.bmj.com for more articles like this and to become a Fellow