

References

- Falagas ME, Nikou SA, Siempos II. Infections related to coils used for embolization of arteries: review of the published evidence. *J Vasc Interv Radiol* 2007;**18**:697–701.
- Yen PS, Teo BT, Chen SC, et al. Endovascular treatment for bilateral mycotic intracavernous carotid aneurysms. Case report and review of the literature. *J Neurosurg* 2007;**107**:868–72.
- Cloud GC, Rich PM, Markus HS. Serial MRI of a mycotic aneurysm of the cavernous carotid artery. *Neuroradiology* 2003;**45**:546–9.
- Hanafy KA, Morgan Stuart R, Fernandez L, et al. Cerebral inflammatory response and predictors of admission clinical grade after aneurysmal subarachnoid hemorrhage. *J Clin Neurosci* 2010;**17**:22–5.
- Zhao S, Grotta J, Gonzales N, et al. Hematoma resolution as a therapeutic target: the role of microglia/macrophages. *Stroke* 2009;**40**:S92–4.
- Zurin AA, Ushikoshi S, Houkin K, et al. Cerebral abscess as an unusual complication of coil embolization in a dural arteriovenous fistula: case report. *J Neurosurg* 1997;**87**:109–12.
- AL-Okaili R, Patel SJ. Brain abscess after endovascular coiling of a saccular aneurysm: case report. *AJNR Am J Neuroradiol* 2002;**23**:697–9.

doi:<http://dx.doi.org/10.1016/j.jocn.2012.10.043>

CADASIL presenting with a behavioural variant frontotemporal dementia phenotype



S.K. Alexander^{a,*}, J.M. Brown^a, A. Graham^a, P.J. Nestor^b

^aDepartment of Clinical Neurosciences, Addenbrooke's Hospital, Hills Road, Cambridge CB2 0QQ, UK

^bGerman Center for Neurodegenerative diseases (DZNE), Magdeburg, Germany

ARTICLE INFO

Article history:

Received 29 January 2013

Accepted 2 February 2013

Keywords:

bvFTD

CADASIL

Frontotemporal dementia

Notch3

ABSTRACT

The behavioural variant of frontotemporal dementia (bvFTD) is characterised by personality change with a decline in cognition. We describe two patients with cerebral autosomal dominant arteriopathy with subcortical infarcts and leukencephalopathy (CADASIL) who presented with behavioural phenotypes similar to bvFTD. The first patient presented with progressive personality and behavioural change, had florid white matter hyperintensity, and had a novel missense mutation C366W in exon 7 of the Notch3 gene. The second patient presented with progressive memory impairment and marked personality changes after a transient ischaemic attack. In this second patient, the radiological features were subtle and only the family history of stroke prompted testing for CADASIL using Notch3 genotyping. We present these patients to demonstrate that CADASIL may mimic bvFTD, with little clinical or radiological evidence to distinguish the two. CADASIL may be an under-recognised diagnosis in apparent bvFTD. Screening Notch3 in a substantial and unselected cohort of frontotemporal dementia patients might be appropriate to investigate this possibility.

© 2013 Elsevier Ltd. All rights reserved.

1. Introduction

The behavioural variant of frontotemporal dementia (bvFTD) is characterised by personality change with a decline in cognition.¹ Here, two patients with cerebral autosomal dominant arteriopathy with subcortical infarcts and leukencephalopathy (CADASIL) – one with a novel missense mutation C366W in exon 7 of the Notch3 gene – are presented, whose behavioural phenotype closely resembled that of bvFTD.

2. Case report

2.1. Patient 1

This 68-year-old woman presented to general neurological services following concern from her family and neighbours about progressive personality and behavioural change over the past 2 years. The patient lived alone and was previously independent. Her family's principal concern related to new problems organising personal finances, hoarding of rubbish causing her house to be unsanitary, and increasing reclusiveness. The patient was relatively insightful as to the extent of her difficulties and extremely resistant to the

idea of outside help for housekeeping or self-care. When the possibility of a social work referral was mentioned she became very angry and left the consultation, only persuaded back later by her family. Her autobiographical memory was relatively preserved. She could remember recent novels she had read and discuss their merits, although with a rather fatuous affect. She was distractible and the consultation was interrupted repeatedly by trips to the toilet. There was no past medical history or family history of note, including no history of cerebrovascular disease.

On cognitive examination, the patient's Mini-Mental State Examination score was 24/30 and 65/100 on the Addenbrooke's Cognitive Examination–Revised version, losing points mostly on verbal fluency, and also on memory and semantic knowledge items. MRI demonstrated florid, confluent white matter hyperintensity extending throughout both cerebral hemispheres notably including the rostral temporal lobes (Fig. 1a). Normal investigations included a routine full blood count and biochemistry, anti-nuclear antibodies, anti-neutrophil cytoplasmic antibodies, anti-cardiolipin antibodies, very long-chain fatty acids and white cell enzymes.

Sequencing of Notch3 identified a novel heterozygous missense mutation (C366R) in exon 7, where an arginine was substituted for a conserved cysteine residue. This is a novel mutation for CADASIL, but is in keeping with previously described mutations, which almost invariably involve cysteine mutations in epidermal growth factor repeats.^{2,3} These features strongly support the pathogenicity of this dominant mutation. However, testing for osmophilic

* Corresponding author. Tel.: +44 12 2324 5151.

E-mail address: siankathalexander@gmail.com (S.K. Alexander).

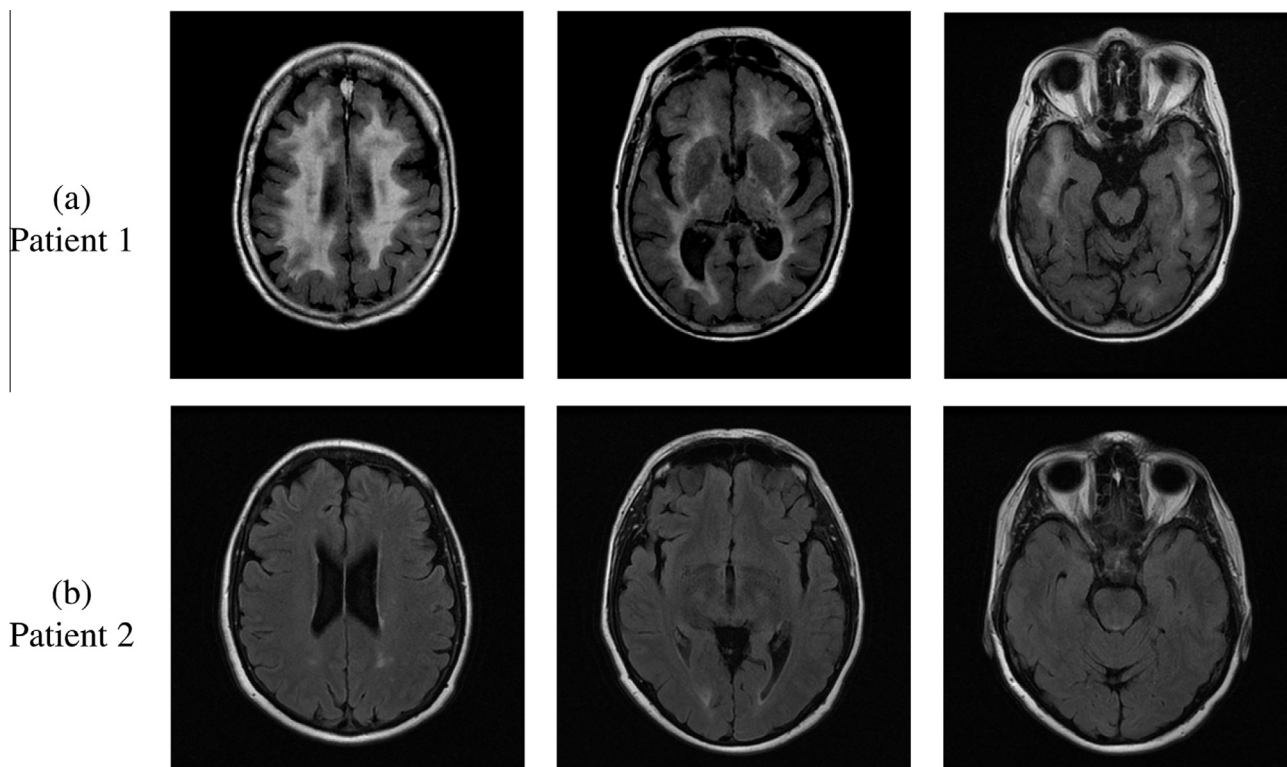


Fig. 1. Transverse fluid attenuated inversion recovery MRI in (a) Patient 1 showing striking and extensive confluent high signal change affecting the white matter of both cerebral hemispheres, and (b) Patient 2 showing more subtle changes, with hyperintense foci in the subcortical and periventricular white matter.

granular material on skin biopsy was not pursued due to the patient's strong views against this.

2.2. Patient 2

This 49-year-old woman presented with sudden-onset paraesthesia and weakness affecting her right arm and leg, which had resolved by the time she reached hospital. She had a past medical history of hypertension, rheumatoid arthritis, and osteoarthritis. She was a non-smoker. Her brother had had a stroke at 49 years of age and her father had been diagnosed with multiple sclerosis. She was diagnosed with a transient ischaemic attack (TIA). Her family reported that she had been developing progressive memory impairment and marked personality changes, particularly apathy, selfishness, rigidity, and childish behaviour. She demonstrated poor planning and judgement when driving. A new and extreme preference for sweet foods had emerged, with significant weight gain. The patient was completely insightful into any of these changes.

On examination, she appeared passive, disinterested, mentally rigid, and cognitively slow. She walked slowly and was mildly unsteady, but there were no focal neurological signs. Marked distractibility made detailed cognitive testing difficult but she did complete a Test Your Memory test scoring 35/50 (control mean: 47/50).⁴

MRI demonstrated only subtle white matter abnormalities (Fig. 1b) in the form of a few discrete high intensity foci in periventricular, parietal, and frontal white matter. None of these foci showed restricted diffusion suggestive of recent subcortical infarction.

Genetic analysis confirmed the patient to be heterozygous for the missense mutation C144Y in exon 4 of the Notch3 gene, a mutation that was previously reported as pathogenic for CADASIL.⁵

3. Discussion

Two patients with genetically-confirmed CADASIL with a phenotype strongly suggestive of bvFTD are presented. CADASIL is a relatively rare disease, usually considered in the context of a young patient suffering a stroke with a family history of cerebrovascular disease. Cognitive sequelae are, however, well-recognised in CADASIL. Previous studies have demonstrated that cognitive decline in CADASIL may precede the first TIA or stroke, although this may be asymptomatic.⁶ Early executive dysfunction and inattention are the most frequently described deficits, with a more global pattern of cognitive impairments in later stages.^{5–7} In most patients, cognitive decline is slowly progressive with additional stepwise deterioration.³ An estimated 75% of mutation carriers will eventually develop dementia and in 90% of patients this is associated with impaired mobility.^{5,7}

The presented patients suggest that a dementia dominated by personality change can occur in CADASIL; in both patients, the informant history and particularly the behaviour of each patient in clinic was strikingly reminiscent of that seen in bvFTD. In Patient 1, a diagnosis of bvFTD was initially suspected but MRI made it immediately apparent that her condition was something other than frontotemporal lobar degeneration – either a leukodystrophy or, particularly in view of the temporal lobe white matter changes, CADASIL. Patient 2, however, highlights that there is a genuine risk that CADASIL could be misdiagnosed as bvFTD even after imaging. In her case, an apparent TIA combined with her family history were the only clues to the diagnosis. The imaging showed negligible white matter involvement that was not beyond the realm of an incidental finding, in turn emphasising that the radiological findings in CADASIL may not be obvious.

Patients with a bvFTD phenotype, especially with a family history of dementia or cerebrovascular disease, warrant

consideration, at least, for genetic testing for CADASIL. This may be particularly important if there is a family history of stroke; given that stroke is so common, this family history could easily be dismissed as irrelevant in the assessment of suspected bvFTD. Finally, Patient 2 also suggests that CADASIL might possibly be an under-recognised diagnosis in apparent bvFTD. Screening Notch3 in a substantial and unselected cohort of FTD patients might be appropriate to investigate this possibility.

Conflict of interest/disclosure

The authors declare that they have no financial or other conflicts of interest in relation to this research and its publication.

References

1. Rascovsky K, Hodges JR, Knopman D, et al. Sensitivity of revised diagnostic criteria for the behavioural variant of frontotemporal dementia. *Brain* 2011;**134**:2456–77. <http://dx.doi.org/10.1093/brain/awr179>.

2. Joutal A, Vahedi K, Corpechot C, et al. Strong clustering and stereotyped nature of Notch3 mutations in CADASIL patients. *Lancet* 1997;**350**:1511–5. [http://dx.doi.org/10.1016/S0140-6736\(97\)08083-5](http://dx.doi.org/10.1016/S0140-6736(97)08083-5).
3. Peters N, Opherk C, Danek A, et al. The pattern of cognitive performance in CADASIL: a monogenic condition leading to subcortical ischemic vascular dementia. *Am J Psychiatry* 2005;**162**:2078–85. <http://dx.doi.org/10.1176/appi.ajp.162.11.2078>.
4. Brown J, Pengas G, Dawson K, et al. Self administered cognitive screening test (TYM) for detection of Alzheimer's disease: cross sectional study. *Br Med J* 2009;**338**:b2030. <http://dx.doi.org/10.1136/bmj.b2030>.
5. Dichgans M, Mayer M, Uttner I, et al. The phenotypic spectrum of CADASIL: clinical findings in 102 cases. *Ann Neurol* 1998;**44**:731–9. <http://dx.doi.org/10.1002/ana.410440506>.
6. Amberla K, Wäljas M, Tuominen S, et al. Insidious cognitive decline in CADASIL. *Stroke* 2004;**35**:1598–602. <http://dx.doi.org/10.1161/01.STR.0000129787.92085.0a>.
7. Opherk C, Peters N, Herzog J, et al. Long-term prognosis and causes of death in CADASIL: a retrospective study in 411 patients. *Brain* 2004;**127**:2533–9. <http://dx.doi.org/10.1093/brain/awh282>.

doi:<http://dx.doi.org/10.1016/j.jocn.2013.02.025>

Spontaneous vertebral arteriovenous fistula causing cervical myelopathy and acute ischemic strokes treated by endovascular balloon-assisted coiling and Onyx embolization



Seby John^{a,*}, Neda Jaffari^b, Mei Lu^b, Muhammad S. Hussain^b, Ferdinand Hui^b

^a Department of Neurology, Cleveland Clinic, 9500 Euclid Avenue, S100-A, Cleveland, OH 44195, USA

^b Cerebrovascular Center, Cleveland Clinic Foundation, Cleveland, OH, USA

ARTICLE INFO

Article history:

Received 30 October 2012

Accepted 7 January 2013

Keywords:

Cervical myelopathy

Coil-assisted Onyx embolization

Embolic ischemic stroke

Vertebral arteriovenous fistulas

ABSTRACT

Vertebral arteriovenous fistulas (VAVF) are infrequent lesions characterized by abnormal communication of the extracranial vertebral artery or one of its branches to the surrounding venous plexuses, without the presence of any intervening vessels. We describe a rare occurrence of a patient with VAVF presenting with acute ischemic stroke, encephalomalacia from multiple prior embolic events, and cervical myelopathy, which was successfully treated by coil-assisted Onyx embolization (ev3 Endovascular, Plymouth, MN, USA) with balloon for flow arrest. Our patient demonstrates that point occlusion with embolization for VAVF can be a feasible, safe, and effective treatment option for complete obliteration of the fistula, with subsequent reduction in the volume of the intra-spinal canal venous plexus. Although it is postulated that thromboembolism is less common because of redirection of flow to the venous side of the fistula, our patient also illustrates the potential for to–fro flow in such a fistula to result in embolic injury to the distal circulation.

© 2013 Elsevier Ltd. All rights reserved.

1. Introduction

Vertebral arteriovenous fistulas (VAVF) are rare lesions characterized by abnormal communication of the extracranial vertebral artery (VA) or one of its branches to the surrounding venous plexuses, without the presence of any intervening vessels or capillaries.¹ They can be either spontaneous or traumatic in origin. Neurological sequelae from vertebral arteriovenous (AV) fistulas can arise from a number of mechanisms including mechanical compression or venous hypertension of the spinal cord and secondary arterial steal. These in turn depend on the pattern of venous drainage, flow velocity, and chronicity of the AV fistula.

Obliteration of the AV fistula with preservation of the parent artery is the primary goal of treatment.

We describe a rare occurrence of a patient with VAVF presenting with acute and chronic ischemic strokes and cervical myelopathy which was successfully treated by coil-assisted Onyx embolization (ev3 Endovascular, Plymouth, MN, USA) with balloon for flow arrest.

2. Case report

A right-handed hypertensive patient in their 60s presented with acute onset vertigo. Examination revealed left-appendicular ataxia, left C5 innervated muscle weakness, decreased left bicep reflex, and hyperreflexia in both legs. A review of systems was positive for pain and hyperesthesia in the left arm for 10 years.

* Corresponding author. Tel.: +1 646 714 5220; fax: +1 216 444 0230.

E-mail address: johns@ccf.org (S. John).