

Discrepancy Between Voluntary Movement and Motor-Evoked Potentials in Evaluation of Motor Function During Clipping of Anterior Circulation Aneurysms

Kengo Suzuki¹, Takeshi Mikami¹, Toshiya Sugino¹, Masahiko Wanibuchi¹, Susumu Miyamoto², Nobuo Hashimoto³, Nobuhiro Mikuni¹

Key words

- Awake craniotomy
- Anterior choroidal artery aneurysm
- Indocyanine green videoangiography
- Motor-evoked potentials

Abbreviations and Acronyms

3D-CTA: three-dimensional computed tomography angiography

AChA: Anterior choroidal artery

ICA: Internal carotid artery

ICG: Indocyanine green

MEP: Motor-evoked potential

PComA: Posterior communicating artery



From the ¹Department of Neurosurgery, Sapporo Medical University, Sapporo; ²Department of Neurosurgery, Kyoto University Graduate School of Medicine, Kyoto; and ³National Cerebral and Cardiovascular Center, Osaka, Japan

To whom correspondence should be addressed: Nobuhiro Mikuni, M.D.

[E-mail: mikunin@sapmed.ac.jp]

Citation: *World Neurosurg.* (2014).

<http://dx.doi.org/10.1016/j.wneu.2013.08.034>

Journal homepage: www.WORLDNEUROSURGERY.org

Available online: www.sciencedirect.com

1878-8750/\$ - see front matter © 2014 Elsevier Inc.

All rights reserved.

INTRODUCTION

The annual rate of cerebral aneurysm rupture is <1%, although this varies with aneurysm size and location (24, 34). The treatment of unruptured cerebral aneurysms is preventive, and should be performed as safely as possible. In particular, the important parenchymal territory supplied by the anterior choroidal artery (AChA), which accounts for 2%–5% of all intracranial aneurysms (7, 8, 14), may make surgical clipping of AChA aneurysms more likely to produce debilitating postoperative ischemic complications. The reported surgical morbidity rate for AChA aneurysm clipping is 10%–12% (8, 14, 16). When clipping AChA aneurysms, the neurosurgeon must be careful not to obliterate or diminish AChA blood flow. Various monitoring modalities have been used during

■ **BACKGROUND:** Various modalities have been used to confirm the blood flow through parent arteries or surrounding perforating arteries during surgical aneurysm clipping, including motor-evoked potentials (MEPs), Doppler ultrasound, and indocyanine green videoangiography. Nonetheless, contralateral hemiparesis due to arterial blood flow insufficiency may arise because of false-positive or false-negative errors. By performing controlled intraoperative awakening during aneurysm clipping, we compared patients' voluntary movements with simultaneous MEP.

■ **METHODS:** Four patients with anterior choroidal artery aneurysms and one patient with a dorsal internal carotid artery aneurysm were included in this study. MEP and intraoperative voluntary movements under awake craniotomy were assessed simultaneously during and after the clipping procedure.

■ **RESULTS:** Aneurysms were safely and successfully clipped in all patients, with no evidence of postoperative neurological deficits. Voluntary movements and MEP findings did not differ from the control state in three patients. In the other two patients, we observed a discrepancy between MEP amplitudes and voluntary movements. In one patient, deterioration and subsequent improvement in voluntary movements were preceded by MEP amplitude reduction during clipping. In the other patient, MEP amplitude did not change although voluntary movement deteriorated during temporary occlusion of the internal carotid artery.

■ **CONCLUSIONS:** Intraoperative neurological assessment during aneurysmal clipping under awake craniotomy is feasible and safe, and should be valuable for the assessment of ischemia, especially in the anterior choroidal artery. From a neurophysiologic viewpoint, MEP may be insufficiently sensitive for evaluating voluntary movement under ischemia.

aneurysm clipping, including motor-evoked potentials (MEPs), Doppler ultrasound, and indocyanine green (ICG) videoangiography, but contralateral hemiparesis due to arterial blood flow insufficiency might arise as a result of either false-positive or false-negative errors. We present illustrative cases of controlled intraoperative awakening during AChA aneurysm clipping, during which we examined patients' voluntary movements with simultaneous MEP, and thus verified whether MEP predicts postoperative preservation of motor function. The discrepancy between MEP and voluntary movement are discussed from a neurophysiologic viewpoint.

METHODS

All procedures were approved by the ethics committee (nos. 23–161), and written informed consent was obtained from all patients.

Patient History

We examined MEP changes and intraoperative voluntary movements under awake craniotomy in five patients with internal carotid artery (ICA) aneurysms. Patient characteristics are summarized in **Table 1**. There were four patients who had AChA aneurysms and one patient with a dorsal ICA aneurysm. The dorsal ICA case also had diffuse astrocytoma (World

Table 1. Patient Characteristics

| Patient Number | Age (years)/ Sex | Size of Aneurysm (mm) | Location of Aneurysm | Associated Conditions | Temporary Arterial Occlusion (minutes) |
|----------------|------------------|-----------------------|----------------------|--|--|
| 1 | 51/F | 3 | AChA | IC terminal An (2 mm) | 0 |
| 2 | 69/F | 4 | AChA | IC-SHA An (2 mm), IC cavernous An (3 mm) | 0 |
| 3 | 53/F | 4 | AChA | | 0 |
| 4 | 60/F | 4 | AChA | IC-PCoMA An (3 mm), IC-oph An (2 mm) | 4 |
| 5 | 42/F | 3 | IC dorsal | Diffuse astrocytoma (grade 2) | 11 |

AChA, anterior choroidal artery; IC, internal carotid artery; SHA, superior hypophyseal artery; An, aneurysm; PComA, posterior communicating artery; oph, ophthalmic.

Health Organization grade II), and the tumor was removed during the same surgery. In three patients, multiple aneurysms were found on the ipsilateral side of the ICA (details are shown in Table 1). All the patients were women, and ranged in age from 42 to 69 years (mean age, 55.0 ± 10.1 years). No patient had preoperative neurological deficits.

Intraoperative Electrical Stimulation

Methods of intraoperative electrical stimulation have been previously described in detail (22). The bilateral abductor pollicis brevis, biceps, brachialis, deltoid, gastrocnemius, quadriceps femoris, and tibialis anterior muscles were selected for electromyographic recording using neurological monitoring (MEE-1232; Nihon Kodan, Tokyo, Japan). General anesthesia was induced and maintained with intravenous infusion of propofol during the craniotomy. Muscle relaxants were administered only for intubation procedures and not during surgery. A peripheral nerve stimulator was used to confirm train-of-four muscle contractions. After dural incision, a 4×5 grid of electrodes (Unique Medical, Tokyo, Japan) was slid into the subdural space of the precentral and postcentral gyri using a navigation system (Figure 1A). To identify the central sulcus, the biggest N20–P20 phase reversal of somatosensory-evoked potentials was recorded. To monitor the motor function of the corticospinal tracts electrophysiologically, the precentral gyrus was stimulated directly to identify a positive control MEP, and to determine the intensity that would be subsequently used to stimulate the subcortical fibers. The intensity for direct cortical stimulation was

increased by 1-mA increments, from 5 mA to a maximum of 15 mA. Although after-discharges were not observed in these patients, if they were induced, the test was repeated with the same current level or with a current level 1 mA lesser. The current level was readjusted under the awake condition. During the subsequent surgical procedure, MEP was monitored every 1 minute.

Surgical Procedure

The surgical procedure is shown in Figure 1. After the laryngeal mask was intubated with general anesthesia, as mentioned previously, the lungs were ventilated mechanically to maintain a partial pressure of arterial carbon dioxide between 35 and 40 mm Hg. A standard frontotemporal craniotomy was performed. After the proximal ICA was

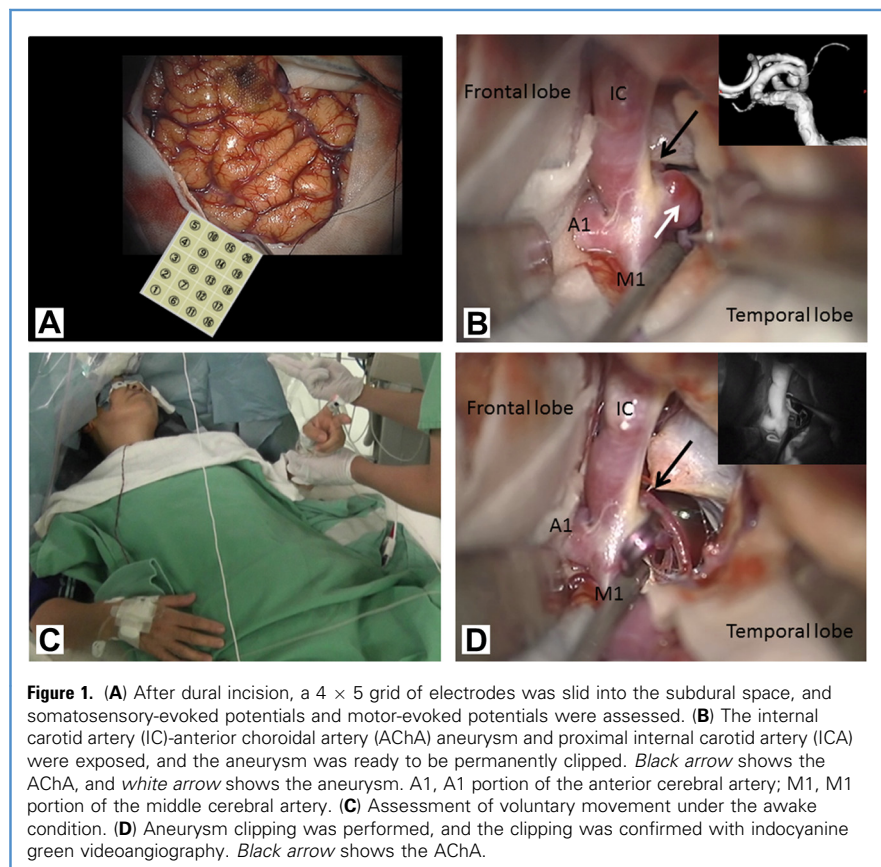
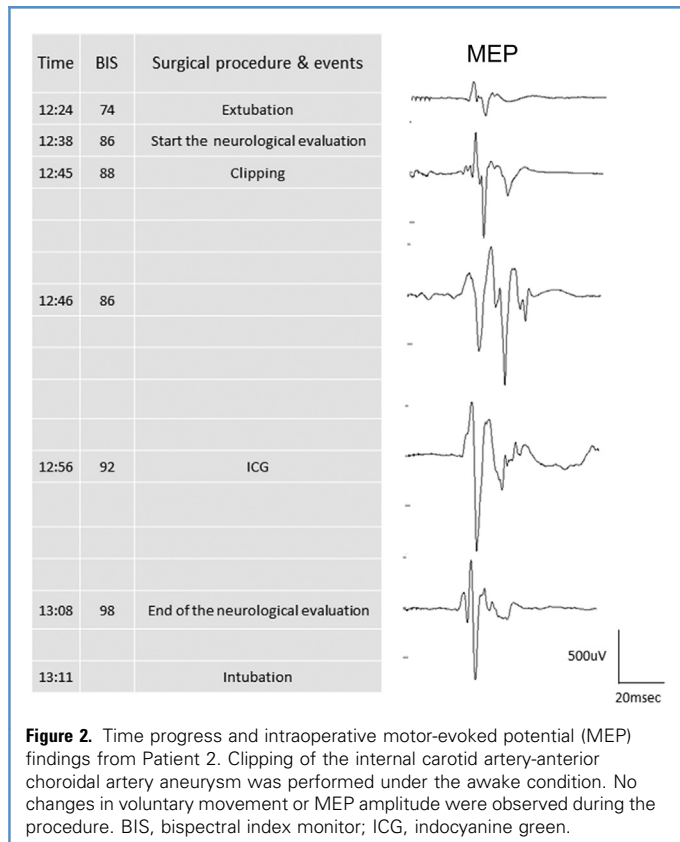


Figure 1. (A) After dural incision, a 4×5 grid of electrodes was slid into the subdural space, and somatosensory-evoked potentials and motor-evoked potentials were assessed. (B) The internal carotid artery (IC)-anterior choroidal artery (AChA) aneurysm and proximal internal carotid artery (ICA) were exposed, and the aneurysm was ready to be permanently clipped. Black arrow shows the AChA, and white arrow shows the aneurysm. A1, A1 portion of the anterior cerebral artery; M1, M1 portion of the middle cerebral artery. (C) Assessment of voluntary movement under the awake condition. (D) Aneurysm clipping was performed, and the clipping was confirmed with indocyanine green videoangiography. Black arrow shows the AChA.



secured and the perianeurysmal structures were exposed, the aneurysm was ready to be permanently clipped (**Figure 1B**). A simulated temporary occlusion of the proximal and distal arteries was also performed, at which time anesthesia was reversed and the laryngeal mask airway was removed, and the procedure was paused until verbal instructions were understood and figure tap movement become possible. Voluntary movement was then assessed in the awake state using the same process as that used in the pre-procedural state (**Figure 1C**). The aneurysm neck was clipped, and the assessment of voluntary movement was continued for 20 minutes. Multiple modalities were used to confirm that the perforating arteries were patent and that the aneurysm was completely occluded after clipping. These modalities included ICG angiography, Doppler ultrasound, and endoscopy (**Figure 1D**). Voluntary movements were confirmed and MEP was assessed until neurological symptoms had

fully returned to the preclipping state. The patient was then reanesthetized with a combination of sevoflurane, remifentanyl, and vecuronium. A bispectral index monitor (Vista A-3000; Covidien, Dublin, Ireland) was used to assess the depth of anesthesia.

RESULTS

In all patients, voluntary movements could be monitored in the awake condition from anesthesia within 10 minutes. No adverse events, including seizures, were observed during monitoring or anesthesia. Patients' pain and body movements were minimal and did not affect the clipping procedure. The awake state made it possible to evaluate fine voluntary movements. The duration of temporary arterial occlusion was 0–11 minutes (mean, 3.0 minutes). Aneurysm clipping was completed in all patients, and associated aneurysms or tumors were treated simultaneously, except in one patient who had a cavernous

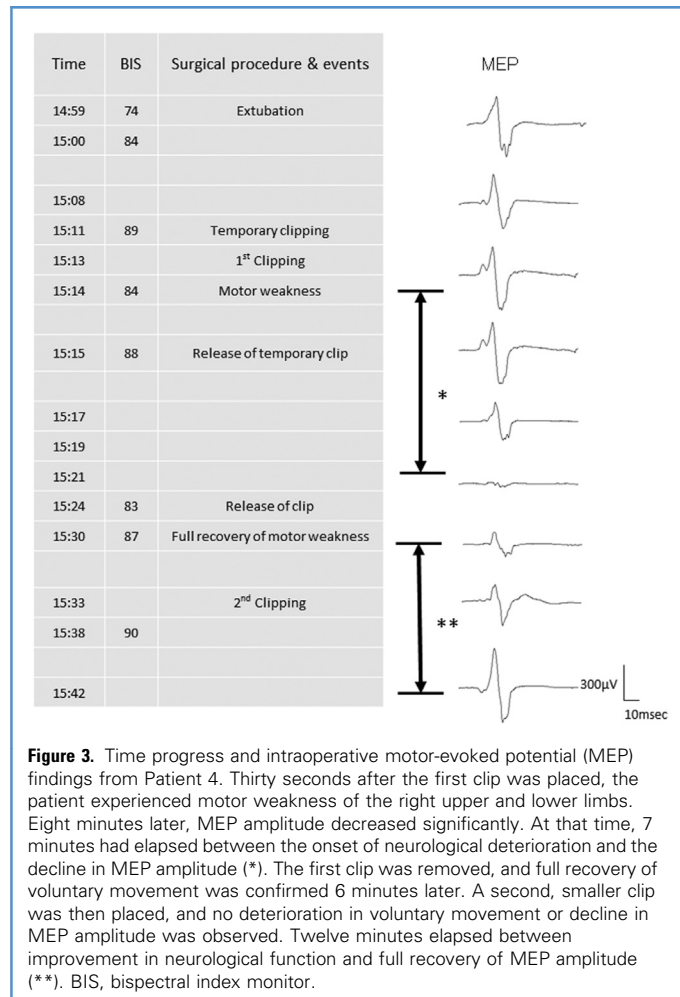
ICA aneurysm. No postoperative neurological deficits were found, and in all patients complete clipping was confirmed by three-dimensional computed tomography angiography (3D-CTA) or digital subtraction angiography. Although it is sometimes difficult to evaluate clipping completeness using 3D-CTA, in the present study this modality was only used for patients in which clipping was performed using titanium products.

In three of the five patients, neither voluntary movement nor MEP changed relative to the control state. The timeline of the procedure in one of these three patients (no. 2) is shown in **Figure 2**. In the other two patients, we observed a discrepancy between changes in MEP amplitude and voluntary movement, with details discussed later.

Illustrative Cases

Patient 4. A 60-year-old right-handed woman was admitted to our hospital because of an unruptured, incidentally found, aneurysm. Her aunt and cousin had medical histories of subarachnoid hemorrhage (details unknown). Magnetic resonance angiography and 3D-CTA demonstrated a 3-mm left ophthalmic artery aneurysm, a 4-mm left AChA aneurysm, and a 3-mm left posterior communicating artery (PCoMA) aneurysm. After informed consent, the patient elected to proceed with surgical treatment using the intraoperative awakening technique to evaluate voluntary movements during aneurysm clipping. The timeline of the procedure is shown in **Figure 3**.

After securing the proximal ICA, the aneurysm was exposed. The AChA was clearly recognized behind the ICA. Anesthesia was then reversed, at which the patient began breathing spontaneously and moving all extremities. After confirming voluntary movement and MEP amplitude, the ICA was temporarily occluded at the proximal portion of the PCoMA. The patient's voluntary movement and MEP amplitude did not change. Two minutes later, a 7.0-mm straight titanium clip (YASARGIL Aneurysm Clip System FT740T; Aesculap, Tuttlingen, Germany) was placed across the neck of the aneurysm. Thirty seconds later, the patient experienced motor weakness of the right upper and lower limbs (manual muscle testing, 2/5). The clip used for



temporary arterial occlusion was removed, and blood flow within the AChA was confirmed by Doppler and ICG angiography. Eight minutes after the neck of the aneurysm was clipped (and 7 minutes after the onset of neurological symptoms), the MEP amplitude decreased significantly. The first permanent clip was removed, and full recovery of voluntary movements was confirmed 6 minutes later. A second, smaller 7.0-mm straight titanium mini-clip (YASARGIL Aneurysm Clip System FT720T; Aesculap) was placed. Replacement of the permanent clip did not lead to either deterioration of voluntary movement or decrease in MEP amplitude, and the patient was reanesthetized. Twelve minutes elapsed between improvement in neurological function and full recovery of MEP amplitude. The duration of intraoperative awakening was 60 minutes, and

the procedure was completed without further complications. The patient was discharged without neurological deficits.

Patient 5. A 42-year-old right-handed woman was admitted to our hospital because of a brain tumor. The tumor was removed under awake craniotomy, with pathology examination demonstrating a grade 2 astrocytoma. A small aneurysm located in the dorsal ICA on the ipsilateral side was clipped during the same operation, and clipping with wrapping was performed. After securing the proximal ICA, the aneurysm was exposed. The timeline of the procedure is shown in **Figure 4**. After confirming voluntary movement and MEP amplitude, the ICA was temporarily occluded at the proximal portion of the PComA. The patient's voluntary movements and MEP amplitude


did not change. Two minutes later the patient developed right-handed clumsiness, and 6 minutes after that, she experienced motor weakness of the right upper and lower limbs (manual muscle testing, 3/5). A small piece of the temporal fascia was wrapped over the entire circumference of the ICA, including the aneurysm, and clipping was completed. The clip used for temporary arterial occlusion was removed 1 minute later, and full recovery of voluntary movement was confirmed 5 minutes afterward. MEP showed no changes during the entire course of the procedure.

DISCUSSION

In this report, we compared patients' voluntary movements with simultaneous MEP. Aneurysms were safely and successfully clipped in all patients, with no evidence of postoperative neurological deficits. Voluntary movements and MEP findings did not differ from the control state in three patients. In the other two patients, we observed a discrepancy between MEP amplitude and voluntary movements. Disturbances in voluntary movement were followed only several minutes later by changes in MEP amplitude in one of these patients, whereas in the other patient MEP amplitude did not change despite hemiparesis.

Clipping of AChA Aneurysms and Electrophysiologic Monitoring

The AChA is divided into the cisternal and plexal segments. The cisternal segment supplies the optic tract, cerebral peduncle, uncus, lateral geniculate body, anterior perforated substance (globus pallidus and posterior limb of the internal capsule), tip of the temporal lobe, hippocampus, dentate gyrus, fornix, and pulvinar (27). The plexal segment in most cases originates as a single branch and then passes through the choroidal fissure to supply the choroid plexus. Along the choroid plexus there are profuse anastomotic communications with the PComA, and somewhat lesser communications with pial branches of the PComA in the region of the lateral geniculate body. Perforating arteries passing through the anterior perforating substance to the globus pallidus and posterior limb of the interior capsule do not receive any significant collateral supply (27). Contemporary



experience with the surgical treatment of AChA aneurysms suggests that blood flow disturbances of the AChA are frequently accompanied by cerebral infarction and permanent neurological deficits (6, 8, 36). To avoid these postoperative complications, the area behind the ICA must be carefully inspected using a micromirror, endoscope, or ICG videoangiography (31). However, these morphologic assessment techniques are not completely reliable, and neurophysiologic assessment with

MEP or other modalities is important for functional completeness (9, 10, 32, 37).

On the other hand, consciousness during MEP monitoring is important because excitability of the cerebral cortex influences MEP threshold (28). Based on our findings, it is possible that MEP under awake surgery is more sensitive to ischemic dysfunction of the corticospinal tract than MEP under general anesthesia. It is difficult to judge the appropriateness of aneurysm clipping based on MEP

amplitude reduction. Corticomuscular MEP provides semiquantitative information, and a reduction in amplitude of 20%–50% is considered to be a warning sign in brain tumor surgery under general anesthesia (15, 25). Little evidence has been reported regarding criteria for amplitude reduction during surgical aneurysm clipping. Subthreshold stimulation is unstable in corticomuscular MEP, and corticospinal MEP has been recommended by some investigators (12, 35). D-waves, measured by corticospinal MEP, are not easily influenced by anesthesia, and can be assessed quantitatively as an index of monitoring (2, 18, 19, 23). Although corticomuscular and corticospinal MEP monitoring approaches are reliable, given sufficient operator experience, they can never perfectly ensure the safety of aneurysm clipping because their findings are only indirect assessments of voluntary motor function. In practice, false-negative errors in MEP monitoring have been reported despite preserved intraoperative MEP (11). Positive predictive values of MEP were reported to be 0.5–1.0, and negative predictive values of MEP were reported to be 0.4–0.92 (37).

Awake Craniotomy and Surgical Treatment of Cerebral Aneurysms

Intraoperative neurological assessment is common during tumor and epilepsy surgeries, and its safety has already been established (1, 3, 13, 21, 33). Our supervisor (N.M.) has had experience with more than 270 cases of awake craniotomy, and the procedure is well established at our institute. However, awake craniotomy is uncommon in aneurysm surgery, and there are few reports on intraoperative awakening for neurological assessment during microsurgical aneurysm clipping. Chen et al. (5) reported intraoperative awakening for visual evaluation during the surgical clipping of an ophthalmic artery aneurysm in which the artery had to be sacrificed. They concluded that intraoperative awakening combined with intraoperative angiography may provide valuable immediate feedback to facilitate a successful functional and anatomic outcome in selected patients. Luders et al. (17) reported three cases of awake craniotomy for microsurgical obliteration of mycotic aneurysms. Awake craniotomy and continuous intraoperative assessment

of voluntary movement were able to detect ischemic signs directly and with high sensitivity. Especially in the case of AChA aneurysms, three or four branches of the AChA might emerge from the ICA behind the aneurysm. Ultimately, awake craniotomy is considered to be one of the more desirable techniques for evaluating actual neurological symptoms intraoperatively. In addition, it has been shown that for carotid endarterectomy, the assessment of voluntary movement under the awake condition is a cost-effective method for the evaluation of ischemia compared with other monitoring techniques under general anesthesia (4). Although the additional cost for awake surgery is not determined in Japan at present, the medical systems of other countries may differ in this regard.

Discrepancy Between Voluntary Movement and MEP Results

In patients nos. 4 and 5, we observed discrepancies between the deterioration of symptoms and MEP amplitude reduction. Impaired voluntary movement under ischemia preceded MEP amplitude reduction, suggesting that evaluation of movement has a higher sensitivity than MEP for some assessments of ischemia. As seen in patient no. 5, global ischemia due to temporary ICA occlusion may occur more readily than when temporal arterial occlusion is not present. In addition, MEP is not a physiologic technique, and the type and domain of an excited neuron differ between MEP and voluntary movement. It is logical that a time discrepancy might occur between MEP amplitude reduction and deterioration of voluntary movement. Basically, corticospinal tract electrical activity originating in the primary motor cortex, whereas the AChA supplies the posterior limb of the internal capsule, which contains tracts from the premotor cortex other than primary motor cortex (20). Therefore, ischemia of the AChA must be evaluated based on tracts other than those originating in the primary motor cortex. On the other hand, permanent hemiparesis also arises with the impediment of the premotor cortex (26, 29). It is difficult to determine whether impaired voluntary movement is caused by ischemia of tracts from the premotor cortex or from the primary motor cortex (30). Thus, intraoperative functional assessment of voluntary

movement should be encouraged in vascular neurosurgical procedures complementary to MEP for evaluating wider areas, including the premotor cortex, especially those involving AChA aneurysms. Of course, it is possible that the patient was not sufficiently awake. Therefore, voluntary movement during the preprocedural state should be assessed and used as a control after the awake state is confirmed, and clipping should then be performed. This step is thought to be particularly important because MEP may be insufficiently sensitive for evaluating voluntary movement under ischemia, although further evidence is needed to confirm these results.

CONCLUSION

Intraoperative neurological assessment, already used safely in tumor and epilepsy surgeries, should be considered for use in monitoring AChA ischemia during aneurysmal clipping. Deterioration and subsequent improvement in voluntary movement during ischemia were found to precede MEP amplitude changes, suggesting that MEP may not precisely measure the neurophysiologic mechanisms involved in motor disturbances.

REFERENCES

- Berger MS, Kincaid J, Ojemann GA, Lettich E: Brain mapping techniques to maximize resection, safety, and seizure control in children with brain tumors. *Neurosurgery* 25:786-792, 1989.
- Bolay H, Gursoy-Ozdemir Y, Unal I, Dalkara T: Altered mechanisms of motor-evoked potential generation after transient focal cerebral ischemia in the rat: implications for transcranial magnetic stimulation. *Brain Res* 873:26-33, 2000.
- Boulton M, Bernstein M: Outpatient brain tumor surgery: innovation in surgical neurooncology. *J Neurosurg* 108:649-654, 2008.
- Calligaro KD, Dougherty MJ: Correlation of carotid artery stump pressure and neurologic changes during 474 carotid endarterectomies performed in awake patients. *J Vasc Surg* 42: 684-689, 2005.
- Chen P, Dunn IF, Aglio LS, Day AL, Frerichs KU, Friedlander RM: Intraoperative awakening for vision examination during ophthalmic artery aneurysm clipping: technical case report. *Neurosurgery* 56:E440 [discussion E440], 2005.
- Cooper IS: Surgical alleviation of Parkinsonism; effects of occlusion of the anterior choroidal artery. *J Am Geriatr Soc* 2:691-718, 1954.
- Drake CG, Vanderlinden RG, Amacher AL: Carotid-choroidal aneurysms. *J Neurosurg* 29: 32-36, 1968.
- Friedman JA, Pichelmann MA, Piepgras DG, Atkinson JL, Maher CO, Meyer FB, Hansen KK: Ischemic complications of surgery for anterior choroidal artery aneurysms. *J Neurosurg* 94: 565-572, 2001.
- Guo L, Gelb AW: The use of motor evoked potential monitoring during cerebral aneurysm surgery to predict pure motor deficits due to subcortical ischemia. *Clin Neurophysiol* 122: 648-655, 2011.
- Hiraishi T, Fukuda M, Oishi M, Nishino K, Shinbo J, Sorimachi T, Ito Y, Fujii Y: Usefulness of motor-evoked potential monitoring during coil embolization of anterior choroidal artery aneurysms: technical reports. *Neurol Res* 33:360-362, 2011.
- Irie T, Yoshitani K, Ohnishi Y, Shinzawa M, Miura N, Kusaka Y, Miyazaki S, Miyamoto S: The efficacy of motor-evoked potentials on cerebral aneurysm surgery and new-onset postoperative motor deficits. *J Neurosurg Anesthesiol* 22: 247-251, 2010.
- Katayama Y, Tsubokawa T, Maejima S, Hirayama T, Yamamoto T: Corticospinal direct response in humans: identification of the motor cortex during intracranial surgery under general anaesthesia. *J Neurol Neurosurg Psychiatry* 51: 50-59, 1988.
- Kayama T: The guidelines for awake craniotomy. Guidelines committee of the Japan awake surgery conference. *Neurologia medico-chirurgica* 52: 119-141, 2012.
- Kim BM, Kim DI, Shin YS, Chung EC, Kim DJ, Suh SH, Kim SY, Park SI, Choi CS, Won YS: Clinical outcome and ischemic complication after treatment of anterior choroidal artery aneurysm: comparison between surgical clipping and endovascular coiling. *AJNR Am J Neuroradiol* 29: 286-290, 2008.
- Kombos T, Suess O, Ciklatekerlio O, Brock M: Monitoring of intraoperative motor evoked potentials to increase the safety of surgery in and around the motor cortex. *J Neurosurg* 95:608-614, 2001.
- Li J, Mukherjee R, Lan Z, Liu Y, He M: Micro-neurosurgical management of anterior choroidal artery aneurysms: a 16-year institutional experience of 102 patients. *Neurol Res* 34:272-280, 2012.
- Luders JC, Steinmetz MP, Mayberg MR: Awake craniotomy for microsurgical obliteration of mycotic aneurysms: technical report of three cases. *Neurosurgery* 56:E201 [discussion E201], 2005.
- Luhmann HJ, Heinemann U: Hypoxia-induced functional alterations in adult rat neocortex. *J Neurophysiol* 67:798-811, 1992.
- Luhmann HJ, Mudrick-Donnon LA, Mittmann T, Heinemann U: Ischaemia-induced long-term hyperexcitability in rat neocortex. *Eur J Neurosci* 7:180-191, 1995.

20. Mathias B, Michael F: Motorisches System. In: Neurologisch-topische Diagnostik. 9 ed. Stuttgart: GeorgThieme Verlag KG; 2009.
21. Mikuni N, Miyamoto S: Surgical treatment for glioma: extent of resection applying functional neurosurgery. *Neurologia medico-chirurgica* 50: 720-726, 2010.
22. Mikuni N, Okada T, Enatsu R, Miki Y, Hanakawa T, Urayama S, Kikuta K, Takahashi JA, Nozaki K, Fukuyama H, Hashimoto N: Clinical impact of integrated functional neuronavigation and subcortical electrical stimulation to preserve motor function during resection of brain tumors. *J Neurosurg* 106:593-598, 2007.
23. Mittmann T, Qu M, Zilles K, Luhmann HJ: Long-term cellular dysfunction after focal cerebral ischemia: in vitro analyses. *Neuroscience* 85:15-27, 1998.
24. Morita A, Kirino T, Hashi K, Aoki N, Fukuhara S, Hashimoto N, Nakayama T, Sakai M, Teramoto A, Tominari S, Yoshimoto T: The natural course of unruptured cerebral aneurysms in a Japanese cohort. *N Engl J Med* 366:2474-2482, 2012.
25. Neuloh G, Pechstein U, Cedzich C, Schramm J: Motor evoked potential monitoring with supratentorial surgery. *Neurosurgery* 54:1061-1070 [discussion 1070-1072], 2004.
26. Peraud A, Meschede M, Eisner W, Ilmberger J, Reulen HJ: Surgical resection of grade II astrocytomas in the superior frontal gyrus. *Neurosurgery* 50:966-975 [discussion 975-977], 2002.
27. Rhoton AL Jr, Fujii K, Fradd B: Microsurgical anatomy of the anterior choroidal artery. *Surg Neurol* 12:171-187, 1979.
28. Rothwell JC, Thompson PD, Day BL, Dick JP, Kachi T, Cowan JM, Marsden CD: Motor cortex stimulation in intact man. 1. General characteristics of EMG responses in different muscles. *Brain* 110 (Pt 5):1173-1190, 1987.
29. Russell SM, Kelly PJ: Incidence and clinical evolution of postoperative deficits after volumetric stereotactic resection of glial neoplasms involving the supplementary motor area. *Neurosurgery* 52: 506-516 [discussion 515-516], 2003.
30. Sala F, Krzan MJ, Jallo G, Epstein FJ, Deletis V: Prognostic value of motor evoked potentials elicited by multipulse magnetic stimulation in a surgically induced transitory lesion of the supplementary motor area: a case report. *J Neurol Neurosurg Psychiatry* 69:828-831, 2000.
31. Sasaki T, Kodama N, Matsumoto M, Suzuki K, Konno Y, Sakuma J, Endo Y, Oinuma M: Blood flow disturbance in perforating arteries attributable to aneurysm surgery. *J Neurosurg* 107:60-67, 2007.
32. Suzuki K, Kodama N, Sasaki T, Matsumoto M, Konno Y, Sakuma J, Oinuma M, Murakawa M: Intraoperative monitoring of blood flow insufficiency in the anterior choroidal artery during aneurysm surgery. *J Neurosurg* 98:507-514, 2003.
33. Taylor MD, Bernstein M: Awake craniotomy with brain mapping as the routine surgical approach to treating patients with supratentorial intraaxial tumors: a prospective trial of 200 cases. *J Neurosurg* 90:35-41, 1999.
34. Wiebers DO, Whisnant JP, Huston J 3rd, Meissner I, Brown RD Jr, Piepgras DG, Forbes GS, Thielens K, Nichols D, O'Fallon WM, Peacock J, Jaeger L, Kassell NF, Kongable-Beckman GL, Torner JC: Unruptured intracranial aneurysms: natural history, clinical outcome, and risks of surgical and endovascular treatment. *Lancet* 362: 103-110, 2003.
35. Yamamoto T, Katayama Y, Nagaoka T, Kobayashi K, Fukaya C: Intraoperative monitoring of the corticospinal motor evoked potential (D-wave): clinical index for postoperative motor function and functional recovery. *Neurologia medico-chirurgica* 44:170-180 [discussion 181-182], 2004.
36. Yasargil MG, Yonas H, Gasser JC: Anterior choroidal artery aneurysms: their anatomy and surgical significance. *Surg Neurol* 9:129-138, 1978.
37. Yeon JY, Seo DW, Hong SC, Kim JS: Transcranial motor evoked potential monitoring during the surgical clipping of unruptured intracranial aneurysms. *J Neurol Sci* 293:29-34, 2010.

Conflict of interest statement: The authors declare that the article content was composed in the absence of any commercial or financial relationships that could be construed as a potential conflict of interest.

Received 17 December 2012; accepted 28 August 2013

Citation: World Neurosurg. (2014).

<http://dx.doi.org/10.1016/j.wneu.2013.08.034>

Journal homepage: www.WORLDNEUROSURGERY.org

Available online: www.sciencedirect.com

1878-8750/\$ - see front matter © 2014 Elsevier Inc.

All rights reserved.