

Gauze-induced granuloma (“gauzoma”): an uncommon complication of gauze reinforcement of berry aneurysms

ISRAEL CHAMBI, M.D., RONALD R. TASKER, M.D., FRED GENTILI, M.D.,
WILLIAM M. LOUGHEED, M.D., HARLEY S. SMYTH, M.D., JOHN MARSHALL, M.D.,
IAIN YOUNG, M.D., JOHN DECK, M.D., AND JANE SHRUBB, R.N.

Division of Neurosurgery (Department of Surgery), Toronto General Hospital and Wellesley Hospital, University of Toronto; Division of Neurosurgery (Department of Surgery) and Department of Pathology, Queen's University; Division of Neuropathology (Department of Pathology), University of Toronto; and Department of Nursing, Toronto General Hospital, Toronto, Ontario, Canada

✓ Incompletely and even adequately clipped berry aneurysms are often reinforced with finely shredded gauze. In seven female patients this practice led to a series of events including headache, pyrexia, seizures, cranial nerve deficits, endocrinopathy, cerebrospinal fluid pleocytosis, and an enhancing mass demonstrated by computerized tomography at the aneurysm site. One patient with blindness, hydrocephalus, and panhypopituitarism died and was examined at autopsy.

Three additional female patients have been identified in the literature with similar case histories. It is suggested that in these patients the gauze induced a foreign-body granuloma, accompanied by progressive occlusion of neighboring small arteries. It would seem prudent to reserve gauze reinforcement for aneurysms that cannot be securely obliterated surgically.

KEY WORDS • foreign-body granuloma • gauze • aneurysm, berry • wrapping

THE consequences of postoperative rupture of an insecurely obliterated berry aneurysm have encouraged surgeons to use every means at their disposal to secure the fundus. One popular strategy consists of cutting a piece of gauze sponge into approximately 1-mm fragments with scissors, suspending it in papaverine hydrochloride injection solution and then applying a thin layer to cover either the neck alone or both the neck and fundus of the aneurysm after clipping. This practice is well established. In 1933, Dott,⁵ in performing the first successful operation on a ruptured aneurysm of the middle cerebral artery (MCA), reported wrapping the aneurysm with muscle hammered into gauze. The patient did well and died from myocardial infarction 12 years later. After introducing routine surgery for the obliteration of berry aneurysms in the 1950's, Botterell, *et al.*,¹ often used either fine strips of gauze or fragments of finely shredded gauze to reinforce clipped aneurysms. Drake and Vanderlinden⁶ used gauze reinforcement when an aneurysm was incompletely clipped. Gillingham⁸ proposed wrapping all MCA aneurysms after completely dissecting the fundus.

Sachs¹¹ showed that wrapping of aneurysms with muscle afforded little reinforcement but that the addi-

tion of cotton was effective. Taylor and Choudhury¹⁵ recommended wrapping aneurysms with postage stamp-sized pieces of gauze on the basis of a 2- to 15-year follow-up study of 35 consecutive patients. One of these patients died of unrelated intracerebral hemorrhage 1 year after wrapping; autopsy revealed the wrapped aneurysm encased in a “thick fibrotic wall.” At the 1986 meeting of the Ontario Medical Association Section of Neurosurgery, where these findings were reviewed, the majority of those present considered such gauze reinforcement routine. However, recurrent bleeding has been reported even when an aneurysm is reinforced with gauze.⁸

This report describes six female patients and alludes to one more, also female. All underwent gauze reinforcement of berry aneurysms after surgical clipping, and all followed an often stuttering clinical course including pyrexia, headache, cranial nerve deficits, endocrinopathy, or epilepsy. One patient died 4 years postoperatively with blindness, hydrocephalus, and panhypopituitarism; the autopsy findings are reported. Three additional cases, also all female, are identified in the literature. The pathogenesis and implications are reviewed.

Case Reports

Case 1

This 63-year-old woman with a long history of migraine was admitted to the Toronto General Hospital on July 26, 1982, with the sudden onset of occipital headache, a 15-minute episode of blurred vision, and meningismus, but no other abnormal neurological symptoms or signs. The cerebrospinal fluid (CSF) was bloody. A computerized tomography (CT) scan revealed blood in the left sylvian fissure and around the left temporal lobe. Four-vessel angiography showed an irregular 15-mm right ophthalmic artery aneurysm and an 8-mm right MCA aneurysm.

At surgery 11 days after admission, the right ophthalmic artery aneurysm, which was adherent to the undersurface of the optic chiasm, was visualized through a right frontal craniotomy after removal of the anterior clinoid process. Just as the aneurysm was being isolated, it ruptured. Bleeding was controlled with two temporary small straight Sugita clips until a large permanent fenestrated Sugita clip could be applied, encircling and flush with the internal carotid artery. The aneurysm was surrounded with shredded gauze which had been suspended in papaverine solution. Immediately postoperatively, the patient complained of an unusually severe headache which persisted, nausea, and vomiting. She developed progressive right ptosis, myosis, and lateral strabismus. A CT scan showed no new abnormality and she was discharged home.

On August 25, 1982, the patient was readmitted and uneventful elective clipping of the unruptured MCA aneurysm was carried out through a pterional approach. Again the aneurysm was surrounded with shredded gauze. By December 14, 1982, although she still had headache and felt tired, the right eye signs had lessened and vision was normal. On January 18, 1983, she had a severe left-sided headache. When examined on June 9, 1983, her headache persisted; her vision was normal, and, although she had stable exotropia, she could fuse the images of the two eyes. On June 14, 1983, she had a 2-hour episode of blurred vision in the right eye following which she was found to have a right superior quadrantanopsia. Repeat CT was unaltered. In July, she experienced an attack of severe right supraorbital pain with bilateral blindness lasting several hours. Afterwards, she was able to perceive only light with the right eye and had the illusion of looking through a veil with the left. Four-vessel angiography on November 25 showed narrowing of the A₁ segment of the right anterior cerebral artery, without evidence of residual aneurysm.

On January 20, 1984, right optic atrophy was noted and, by May 22, vision in the right eye had deteriorated further but the right lateral strabismus and ptosis had not changed. On June 26, after the patient had experienced sudden loss of vision in the left eye while bowling, left optic atrophy and a left temporal field defect were noted. On March 13, 1985, the right eye was found to

be completely blind; there was a temporal hemianopsia on the left. On the same day a CT scan showed an enhancing mass (Fig. 1) surrounding the chiasmatic region, and an arteriogram on April 15 showed elevation of the further narrowed right A₁ segment. On May 9, the optic chiasm was reexplored, revealing a mass of adherent fibrous material which elevated the right optic nerve and chiasm and separated them from the internal carotid artery; it extended posteriorly beyond the chiasm. The mass was partially excised, sacrificing the encased frontopolar artery. The right optic nerve was so distorted and incorporated into the mass that only its inferior border could be identified, whereas the left optic nerve could be partially freed (Fig. 2). The excised material consisted of vascular hyalinized connective

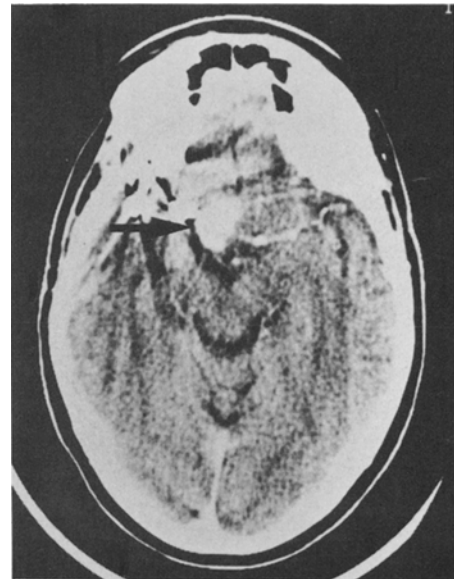

FIG. 1. Case 1. Computerized tomography scan showing enhancing presellar mass (arrow).

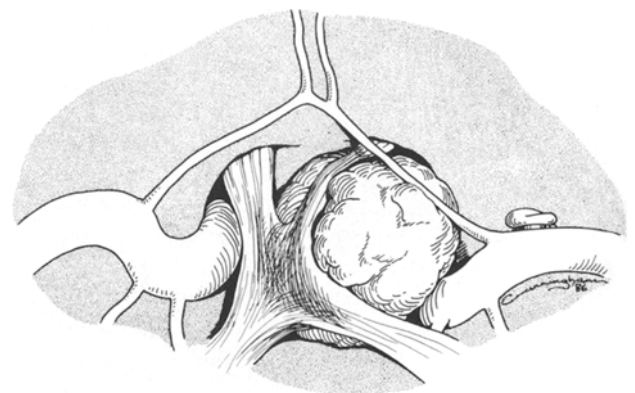


FIG. 2. Case 1. Operative diagram showing marked distortion revealed at surgery of the optic chiasm and nerves by gauze-induced granuloma.

Granuloma from gauze reinforcement of aneurysms

tissue, containing birefringent filamentous foreign material and acute and chronic inflammatory cell infiltrates, with lymphocytes, plasma cells, neutrophils, foamy macrophages, and numerous multinucleated foreign-body giant cells (Fig. 3).

When examined on June 25, 1985, the patient complained of burning dysesthetic pain below both knees. She exhibited excessive weight gain and was found to have distal hypalgesia in all four limbs. She was admitted to a hospital in Kingston, Ontario, in December, 1985, with a 4-month history of confusion, nausea, ataxia, leg weakness, urinary incontinence, and increasing blindness in the left eye in addition to the previous problems. A CT scan revealed hydrocephalus, and a ventriculoperitoneal shunt was inserted on February 19, 1986. Her confusion and ataxia improved but, on May 1, 1986, while awaiting discharge she suddenly lost consciousness for 1 minute, showing fixed dilated pupils, hypotension, and tachycardia. She regained consciousness and became oriented but remained hypoxic. She then had a second similar episode with a cardiac arrest and remained hypotensive and bradycardiac. She regained the ability to move all limbs but was hyperreflexic with upgoing toes. She developed polyuria with a serum osmolality of 320 mOsm/kg and a urine osmolality of 323 mOsm/kg; she was treated with vasopressin. On May 6, 1986, she developed apneic spells and gradually deteriorated, dying on May 12, 1986.

At autopsy, an ovoid mass of dense fibrous tissue measuring 2 cm in greatest dimension surrounded the clip on the right MCA aneurysm. A similar densely adherent mass encircled the right ophthalmic and internal carotid arteries, optic nerve, third nerve, and optic chiasm, and extended to the hypothalamus adjacent to the pituitary stalk. The right MCA and ophthalmic artery masses contained dense fibrous tissue, foci of foreign-body granuloma, and abundant refractile material. The optic chiasm, nerves, and tracts were

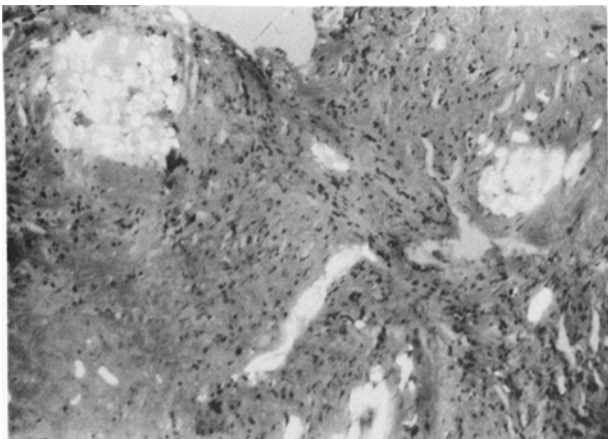


FIG. 3. Case 1. Photomicrograph of the granulomatous mass demonstrating inflammatory reaction produced by gauze containing birefringent material. H & E, $\times 50$.

severely gliotic, fibrotic, and demyelinated. Fibrosis extended into the hypothalamus and pituitary stalk.

Case 2

This 39-year-old woman suddenly developed an occipital headache on December 17, 1984, and was treated with analgesics. Because of persistent headache, she was admitted to the Toronto General Hospital where neurological examination and a CT scan were normal. The CSF was bloody and four-vessel angiography revealed a 1-cm bilobed anterior communicating artery aneurysm without vasospasm. On December 26, 1984, the aneurysm was clipped with a large and a small straight Sugita clip, and its neck was reinforced with finely shredded gauze which had been suspended in papaverine solution.

Postoperatively, the patient complained of generalized headache, attributed to a right-sided 3-mm subdural hematoma demonstrated by CT scan, without mass effect. In July, 1985, she complained of low-grade fever, fuzzy peripheral vision, and "waves of light" in the right eye, worse at night; examination revealed a left upper temporal quadrantanopsia. A CT scan showed an enhancing right suprasellar mass in addition to the small subdural effusion. By January, 1986, although she still complained of hazy vision in the right eye, the visual field defect and other symptoms had resolved.

Case 3

This 71-year-old woman presented to the Toronto General Hospital on May 16, 1982, with sudden fronto-occipital headache, vomiting, drowsiness, hypertension (190/100 mm Hg), and meningismus, but no other neurological deficit. She became fully alert over 48 hours, and four-vessel angiography on the 3rd day showed a 9-mm right posterior communicating artery aneurysm without vasospasm. On May 20, 1982, this was clipped with a straight Sugita clip applied flush with and parallel to the internal carotid artery. Shredded papaverine-soaked gauze was placed around the neck.

In September, 1983, the patient returned with a 2-month history of bifrontal headache and low-grade fever. A CT scan showed an enhancing right suprasellar mass but arteriography revealed no aneurysm. In December, 1983, she began to notice painless right ptosis which progressed over the next 5 months to complete oculomotor palsy and then improved again over the next year until she could partially open her right eye. Paresis of the superior, medial, and inferior rectus muscles persisted. In March, 1985, while brushing her teeth, she lost consciousness briefly without residual neurological or CT changes. A right anterior temporal electroencephalographic (EEG) focus was identified but, under treatment with diphenylhydantoin sodium, she had no further seizures; the third nerve palsy still persisted at her latest follow-up examination in March, 1987.

Case 4

This 31-year-old woman experienced a sudden excruciating fronto-occipital headache and transient loss of consciousness on March 10, 1986. Her CSF was bloody, a CT scan was normal, and angiography was equivocal. Repeated angiography on March 15, 1986, showed a 16-mm left MCA aneurysm. She had persisting headache without other abnormalities. The same day the aneurysm was partially clipped with a curved Sugita clip; two residual small blebs of aneurysm were obliterated with a right-angled fenestrated clip, sparing all parent vessels. The clipping was reinforced with finely shredded papaverine-soaked cefotaxime gauze.

On April 15, 1986, the patient suffered the first of six epileptic events, each lasting less than a minute, during which she smelled "rotten eggs." In May, 1986, she noted a pounding occipitotemporal headache, worse when upright, and intermittent low-grade fever. On June 19, 1986, she was readmitted with a temperature of 38.8°C, but no neurological deficit; a CT scan showed a multiloculated 1 × 2-cm enhancing mass in the left sylvian fissure just above the clips with surrounding edema (Fig. 4). There was a left temporal sharp-wave EEG focus. She was treated with intravenous cloxacillin and cefotaxime, although no infectious organisms were ever identified. Further generalized seizures were controlled, first with diphenylhydantoin sodium, then (because of a skin rash) with carbamazepine. Serial CT scans demonstrated diminution in size of both the edema and the mass. Three months later she was symptom-free.

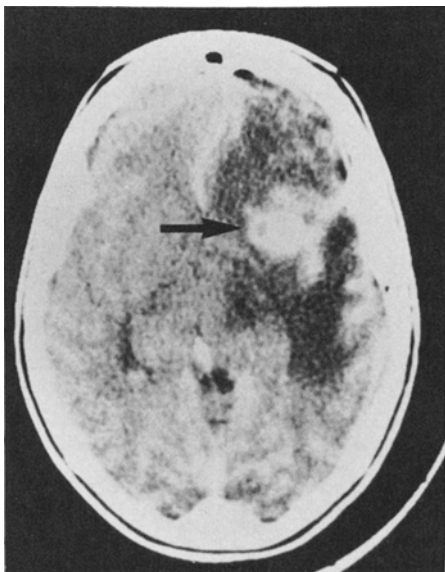


FIG. 4. Case 4. Computerized tomography scan showing an enhancing mass (arrow) in the left sylvian fissure with surrounding edema.

Case 5

This 65-year-old woman presented to the Toronto General Hospital on March 30, 1986, with sudden, intense occipital headache, meningismus, drowsiness, and hypertension (210/100 mm Hg) without other neurological abnormality. A CT scan demonstrated blood in the sylvian fissures, worse on the right, with mild enlargement of the lateral and third ventricles; four-vessel angiography revealed a 20-mm right MCA bifurcation aneurysm. The next day the aneurysm was exposed and dissected through a right superior temporal cortical incision with the help of a temporary clip on the M₁ segment. The neck and proximal portion of the aneurysm were calcified, broad, and ill-defined, so that a clip could not be placed across the neck without compromising the parent vessels. The aneurysm was therefore clipped distally with right-angled fenestrated Sugita clips, sparing all vessels, and the neck was surrounded with shredded papaverine-soaked ceftazidime gauze.

On August 31, 1987, the patient presented with lethargy, confusion, a fever of 38.7°C, malaise, chills, fatigue, headache, photophobia, blurred vision, and urinary frequency, but no focal neurological signs. A CT scan with no contrast enhancement demonstrated moderate hydrocephalus and a low-density right frontotemporal lesion compressing the right frontal horn. Lumbar puncture revealed an opening pressure of 13 mm H₂O and slightly turbid CSF, with 4150 white cells (80% of which were neutrophils), 160 red cells, no organisms, a glucose level of 2.2 mg/dl, and a protein level of 1.36 gm/dl. The patient was treated with intravenous ceftazidime, vancomycin, and tobramycin; her mentation improved within 24 hours and her fever disappeared after 2 days. A follow-up CT scan showed a 2.5 × 1.5-cm enhancing mass above the clip, elevating the right frontal horn and associated with right frontal lobe edema extending into the superior right temporal lobe (Fig. 5). Abscess was suspected so that intravenous Flagyl (metronidazole) with prophylactic diphenylhydantoin sodium was added. Blood cultures showed no growth although urine cultures grew coliform bacteria and *Streptococcus*. In October, 1987, and October, 1988, CT scans showed no change but the patient remained asymptomatic.

Case 6

This 35-year-old woman with three previous bouts of severe headache was admitted to the Wellesley Hospital on May 14, 1987, with photophobia and meningismus. Shortly before, she had suffered the onset of severe generalized headache while playing baseball, when her legs collapsed beneath her. A CT scan showed moderate cisternal and interhemispherical subarachnoid blood, and arteriography demonstrated an unusual aneurysm arising from a wide neck at the origin of an anomalous accessory recurrent MCA branch from the proximal A₁. There was a fusiform change in the left

Granuloma from gauze reinforcement of aneurysms

mirror position. On the 10th day of an intended 14-day presurgery delay, during which she remained in neurological grade 1 and was treated with Amicar (aminocaproic acid, 1 gm/hr), her headache recurred, her temperature and white blood cell count rose, while her blood pressure remained normal. Arteriography on Day 11 demonstrated enlargement of the aneurysm, the appearance of distinct bilobularity, but no spasm. The aneurysm was exposed, dissected, and secured with a curved side-angled Sugita clip through a right pterional craniotomy on the same day. Since it proved impossible to safely secure a residual small thin-walled pulsatile segment 1 mm in length, the latter was covered with papaverine-soaked shredded gauze, and the patient was discharged without neurological deficit 12 days post-operatively. Within 10 days she began to complain of repeated olfactory hallucinations which were controlled with 300 mg diphenylhydantoin sodium.

By August, 1987, the patient gradually became aware of a left-sided defect of the visual field and visual hallucinations in the hemianoptic field in the form of elemental shapeless forms and also highly organized visual material described as "an extension of reality." A smooth concrete walk appeared to her as a distorted surface extending into the hemianoptic field while a lawn appeared like rolled sod in the same area. Examination revealed an almost completely congruous left homonymous hemianopsia; a CT scan was normal. In October, 1987, she complained of further failure of vision in the right eye where she was found to be capable only of finger-counting; vision was 20/30 on the left, associated with a complete left homonymous hemianopsia and a very large right central scotoma. Oligomenorrhea supervened and neuroendocrine investigation revealed a follicle-stimulating hormone (FSH) level

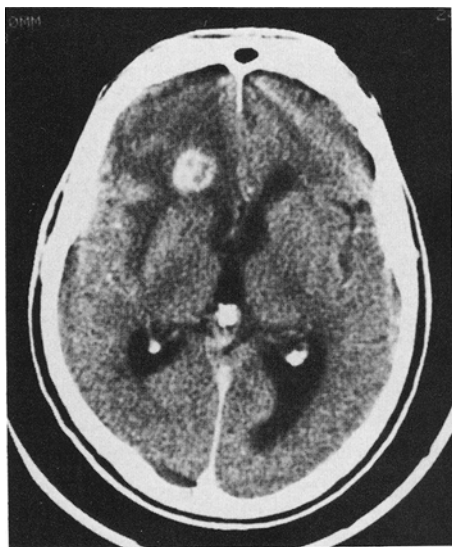


FIG. 5. Case 5. Computerized tomography scan showing an enhancing mass in the right sylvian fissure with surrounding edema.

of 5 IU/liter, a luteinizing hormone (LH) level of less than 3 IU/liter, but normal FSH and LH responses after administration of LH-releasing hormone. Subsequently, normal menses resumed. A CT scan on May 20, 1988, demonstrated a large enhancing right parasellar mass, while right carotid arteriography showed satisfactory clipping of the aneurysm and preservation of the parent vessel. The patient's visual status has remained stable over the subsequent year.

Comment

One further patient, also female, has been brought to our attention. She developed symptoms and a mass was visualized on CT at the site of gauze application to a clipped, ruptured berry aneurysm in another Toronto hospital.

Discussion

Within 17 months after reinforcement of aneurysmal clipping with shredded gauze, seven female patients developed some or all of the following symptoms: headache, low-grade fever, epilepsy, endocrinopathy, CSF pleocytosis, cranial nerve deficit, and a localized enhancing mass on CT. In one patient such a mass was partially removed, although she subsequently died with headache, blindness, hydrocephalus, and panhypopituitarism. Pathological examination of both the surgical and autopsy specimens revealed a dense fibrotic granulomatous foreign-body reaction containing birefringent material at the sites of the gauze implantation.

The only relevant publication appears to be a report by Carney and Oatley² of three women who developed partial blindness 1, 7, and 11 months, respectively, after unruptured aneurysms at three different sites had been clipped and wrapped with gauze. One patient experienced the sudden onset of symptoms. In two cases the deficits improved, one had fever and CSF pleocytosis, and none had masses visible with CT. The authors incriminated an underlying ischemic process with gauze as a possible culprit.

Table 1 summarizes the clinical features of the six patients reported here fully and the three patients of Carney and Oatley² (Cases 7, 8, and 9). The significance of the fact that all were women is unclear. No other risk factor was identified and none of the patients was proved to have infection. The aneurysm site and occurrence of subarachnoid hemorrhage appear irrelevant. The delayed onset of symptoms (up to 17 months) suggests a slowly progressive process. Headache in seven patients, pyrexia in six, CSF pleocytosis in three of the four whose CSF was studied, and an enhancing CT mass in six suggest an inflammatory process with eventual apparent stabilization within the limited follow-up period in eight cases.

Epilepsy in five patients was compatible with a focus near the aneurysm site, while neurological signs could be attributed to involvement of adjacent structures: the optic nerves in six, oculomotor nerves in two, and the

TABLE 1
Clinical summary of nine cases of gauze-induced granuloma*

Case No.	Sex, Age (yrs)	Postop Onset of Symptoms (mos)	Size & Site of Aneurysm	Sudden Onset	Febrile	Cranial Nerve Signs	Epilepsy	CSF Pleocytosis	Head-aches	Other	CT Scan Appearance	Apparent Stabilization‡
1	F, 63	0	ruptured 15 mm, rt ophthalmic; unruptured 8 mm, rt MCA	yes	yes	III, II	yes	yes	yes	hydrocephalus, endocrinopathy, limb hypalgesia, dysesthesia	enhancing mass	no, stepwise progression of symptoms; died 45 mos postop
2	F, 39	6	ruptured 10 mm, anterior communicating	no	yes	II	no	?	yes	no	enhancing mass	yes
3	F, 71	16	ruptured 9 mm, rt posterior communicating	no	yes	III	yes: rt temporal lobe focus	?	yes	no	enhancing mass	yes
4	F, 31	1	ruptured 16 mm, lt MCA	no	yes	no	yes: lt temporal lobe focus	?	yes	no	enhancing mass	yes
5	F, 65	17	ruptured 20 mm, rt MCA	no	yes	no	no	yes	yes	hydrocephalus	enhancing mass	yes
6	F, 35	0.3	ruptured, rt anterior cerebral	no	no	II	yes: temporal lobe	?	no	endocrinopathy	enhancing mass	yes
7†	F, 37	7	15 mm, ICA (no gauze); 4 mm anterior communicating (gauze); both unruptured	no	no	II, rt eye temporal field defect	preop lt temporal lobe	no	yes	no	negative	yes
8†	F, 47	1	3-cm subfrontal meningioma; unruptured 10 mm, rt ICA, not clipped	yes, sudden blindness in rt eye	yes	II, lt eye inferior temporal defect	yes	yes	yes	no	negative	yes
9†	F, 37	11	8 × 5 × 7 mm, lt posterior communicating	no	no	II, lt eye nasal field defect	no	?	no	lt MCA infarct	infarct	yes

* CSF = cerebrospinal fluid; CT = computerized tomography; MCA = middle cerebral artery; ICA = internal carotid artery.

† Cases reported by Carney and Oatley.²

‡ Partial recovery was obtained in all patients except Case 9.

hypothalamus-pituitary axis in two. Pathological examination in one case revealed a granulomatous foreign-body reaction containing birefringent material at the site of gauze implantation.

Onset of symptoms was abrupt in two patients and progressed stepwise in five. At least partial recovery was documented in eight cases, in keeping with an associated vascular pathophysiology. It seems reasonable to conclude that the application of gauze in these nine patients initiated a foreign-body granulomatous reaction, regardless of site or occurrence of subarachnoid hemorrhage. The reaction was self-limiting in all but the fatal case, yet was capable of damaging adjacent structures to produce epilepsy or cranial nerve palsies. Although concomitant bacterial infection might be suspected of being the critical factor initiating the granulomatous response, none was ever proven in the cases described, the reaction appearing to be a sterile one. Choi, *et al.*,³ described masses with similar features

related to retained sponges after four instances of abdominal surgery, noting the CT appearance and describing the presence of cotton fibers and/or birefringent fragments in the lesions. Sturdy, *et al.*,¹³ studied foreign-body granulomas after 32 intraperitoneal, 23 subcutaneous, and six uterine cervical operations and one intra-articular procedure, comparing results with experimental studies in which lint from dry packs, laparotomy sponge, gauze sponge, and starch were placed in the peritoneal cavities of rats. Gross granulomas developed in 52%, 33%, 33%, and 67%, and microscopic granulomas in 72%, 33%, 33%, and 83% of these groups of rats, respectively. They noted typical "Maltese cross" crystals under polarized light in the starch group and variable birefringent patterns in the gauze groups. A similar granuloma was seen after cottonoid had been inadvertently left, presumably in the epidural space, after discotomy. The observations of Sturdy, *et al.*, suggest that bleached cotton, either in

Granuloma from gauze reinforcement of aneurysms

the form of gauze, cottonoid, or laparotomy sponge, can cause foreign-body granulomas containing birefringent material, particularly if lint is plentiful; the failure of granulomas to form in every rat suggests an idiosyncratic reaction.

The incidence of this granulomatous reaction after aneurysm surgery, for which radiologists have coined the word "gauzoma," is unknown. From 1982 to 1986, during which time the five cases occurred at the Toronto General Hospital, 218 aneurysms were clipped by the five staff neurosurgeons, virtually all with gauze reinforcement. However, CT scans were not performed routinely after surgery, so some cases might have been missed. Before a high-quality scanner became available during 1983, CT scans might not have revealed "gauzomas" even in symptomatic cases; thus, asymptomatic lesions would certainly have been missed. On the other hand, enhanced CT scans, carried out for other reasons in patients whose aneurysms are known to have been reinforced with gauze, have thus far not revealed any asymptomatic "gauzomas."

There is no reason to believe that there was anything exceptional about the gauze used in patients who developed granulomas, nor any common factor between the Toronto and Australian cases. The gauze used in Toronto was usually radiomarked and 4 × 4-in. in size, taken off the operating room table. Occasionally, the wrapping material was similarly prepared in advance from 4 × 4-in. unmarked gauze. Both types, obtained from two suppliers, consisted of 100% cotton thread and were stored unsterile in bulk to be counted, packaged, and sterilized as needed. Any unused material was discarded after expiry of sterilization date.

In Toronto, gauze wrapping has been carried out since the early 1950's. Originally, strips of gauze were wrapped around aneurysms and secured with silver clips. The appearance of "gauzomas" only in the 1980's is perhaps explained by the fact that, if this apparently idiosyncratic self-limiting process had appeared before adequate CT scanning, it might either have been overlooked or else attributed to other causes. It remained for our exceptional Case 1 to draw attention to this problem. Neither the composition of the gauze nor the strategy of its use has changed with time. The implications for the surgeon are difficult to define. Although the incidence of "gauzoma" may be low, and the consequences nearly always reversible or self-limiting, nevertheless, wrapping of aneurysms with gauze can lead to remarkable complications, and should likely be avoided when an aneurysm has been satisfactorily obliterated, particularly near cranial nerves. The risk of using gauze for wrapping in other situations should be weighed against the dangers of aneurysmal rebleeding.

Alternatives are elusive. Dutton⁷ introduced the coating of aneurysms with acrylic, and reported an 8% mortality in 106 patients, none of whom rebled. Hoppenstein, *et al.*,¹⁰ however, noted thrombosis of canine arteries 2 mm or less in diameter when methyl-2-cyanoacrylate (commonly used to coat aneurysms) was

used for their anastomosis. Coe and Bondurant⁴ reported a patient who suddenly developed hemiparesis and aphasia 5 weeks after a cerebral aneurysm had been coated with fascia and cyanoacrylate resulting in thrombosis of both the aneurysm and its parent artery. Sachs, *et al.*,¹² reported acute necrosis of the aneurysmal wall leading to a massive hemorrhage 3 days after coating with methyl-2-cyanoacrylate. Yodh and Wright¹⁷ and Handa, *et al.*,⁹ have reported neurotoxic effects from similar compounds. A recent review by Weir¹⁶ has raised not only concern about toxicity but also doubts about long-term effectiveness when plastic adhesive agents are used in an attempt to prevent fatal aneurysmal rebleeding. As an alternative, Sugita¹⁴ has proposed the use of thin layers of Bemsheets with fibrin glue to protect unclippable aneurysms. It will require time and experience to be certain that alternative substances do not produce the same type of delayed inflammatory response that we have identified after use of gauze.

Acknowledgment

The authors thank Ms. Patsy Cunningham of the Sunnybrook Hospital Media Services, Toronto, for the preparation of Fig. 2.

References

1. Botterell EH, Loughheed WM, Morley TP, et al: Hypothermia in the surgical treatment of ruptured intracranial aneurysms. *J Neurosurg* 15:4-18, 1958
2. Carney PG, Oatley PE: Muslin wrapping of aneurysms and delayed visual failure. A report of three cases. *J Clin Neuroophthalmol* 3:91-96, 1983
3. Choi BI, Kim SH, Yu ES, et al: Retained surgical sponge: diagnosis with CT and sonography. *AJR* 150:1047-1050, 1988
4. Coe JE, Bondurant CP Jr: Late thrombosis following the use of autogenous fascia and a cyanoacrylate (Eastman 910 monomer) for the wrapping of an intracranial aneurysm. *J Neurosurg* 21:884-886, 1964
5. Dott NM: Intracranial aneurysms: cerebral arterio-radiography: surgical treatment. *Edinb Med J* 40:219-234, 1933
6. Drake CG, Vanderlinden RG: The late consequences of incomplete surgical treatment of cerebral aneurysms. *J Neurosurg* 27:226-238, 1967
7. Dutton J: Acrylic investment of intracranial aneurysms. A report of 12 years' experience. *J Neurosurg* 31:652-657, 1969
8. Gillingham FJ: The management of ruptured intracranial aneurysm. Hunterian Lecture. *Ann R Coll Surg Engl* 23:89-117, 1958
9. Handa H, Ohta T, Kamijyo Y: Encasement of intracranial aneurysms with plastic compounds. *Prog Neurol Surg* 3:149-192, 1969
10. Hoppenstein R, Weissberg D, Goetz RH: Fusiform dilatation and thrombosis of arteries following the application of methyl 2-cyanoacrylate (Eastman 910 monomer). *J Neurosurg* 23:556-564, 1965
11. Sachs E Jr: The fate of muscle and cotton wrapped about intracranial carotid arteries and aneurysms. A laboratory

- and clinico-pathological study. *Acta Neurochir* **26**: 121-137, 1972
12. Sachs E Jr, Erbenig A, Margolis G, et al: Fatality from ruptured intracranial aneurysm after coating with methyl 2-cyanoacrylate (Eastman 910 monomer, M2 C-1). Case report. *J Neurosurg* **24**:889-891, 1966
 13. Sturdy JH, Baird RM, Green AN: Surgical sponges cause of granuloma and adhesion formation. *Ann Surg* **165**: 128-134, 1967
 14. Sugita K: *Microsurgical Atlas*. Berlin: Springer-Verlag, 1985
 15. Taylor JC, Choudhury AR: Reinforcement with gauze wrapping for ruptured aneurysms of the middle cerebral artery. *J Neurosurg* **47**:828-832, 1977
 16. Weir B: *Aneurysms Affecting the Nervous System*. Baltimore: Williams & Wilkins, 1987, pp 419-423
 17. Yodh SB, Wright RL: Experimental evaluation of four synthetic adhesives for possible treatment of aneurysms. *J Neurosurg* **26**:504-510, 1968

Manuscript received May 11, 1988.

Accepted in final form July 19, 1989.

This work was exhibited in a poster presentation at the Annual Meeting of the American Association of Neurological Surgeons, Toronto, Ontario, Canada, April 24-28, 1988.

Address reprint requests to: Ronald R. Tasker, M.D., F.R.C.S.(C), Room 215, 14th Floor, Eaton Wing, Toronto General Hospital, 200 Elizabeth Street, Toronto, Ontario M5G 2C4, Canada.