

# Ictal asystole: A rare cause of cardiac arrest

Douglas S. Larsen, PA-C; Azeemuddin Ahmed, MD, MBA

## ABSTRACT

Ictal asystole, a rare cause of transient cardiac arrest, is triggered by seizure activity. Long-term seizure control and pacemaker implantation can reduce the risk of this complication.

**Keywords:** ictal asystole, cardiac arrest, epilepsy, seizure, parasympathetic output

## CASE

A 66-year-old woman with stroke-like symptoms and a history of hypertension and breast cancer was brought to the ED by ambulance. Earlier in the day, she was having difficulty playing her piano, so she stopped for the day. Her symptoms spontaneously resolved until about 30 minutes before ED arrival, when she noted acute-onset tremor in her right upper and lower extremities.

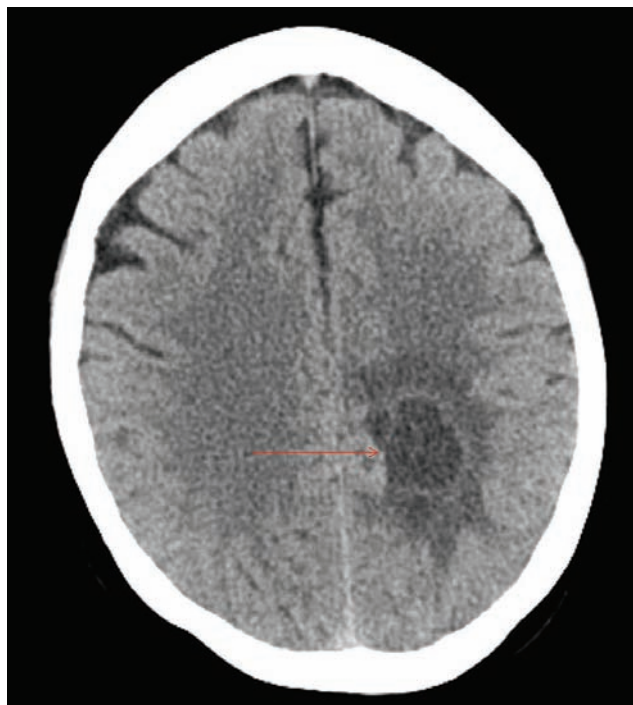
The emergency medical service providers observed the shaking movements in her extremities on the right side and reported that she was able to verbally communicate and follow commands on scene with good strength in all extremities. During the 8-minute transport to the ED, she became increasingly unable to speak but remained conscious and alert. Upon arrival in the ED, she was completely aphasic, at which point a stroke alert was initiated.

**Physical examination** The patient was examined in the supine position. Her vital signs on arrival showed her to be afebrile with a BP of 90/56 mm Hg; pulse, 96; respirations, 20; and SpO<sub>2</sub> of 100% on room air. Her blood glucose was 119 mg/dL. The head and neck exam was normal, her heart rate and rhythm were regular with no murmurs, and her lungs were clear bilaterally. Her abdominal examination was benign, and her skin was well-perfused with no rashes noted. The neurologic exam was abnormal as she was awake and alert but unable to state her name or repeat sentences. Her cranial nerve exam was normal as was her strength in all four extremities. The plantar responses were upgoing bilaterally.

**Douglas Larsen** practices emergency medicine at the University of Iowa Hospitals and Clinics in Iowa City. **Azeemuddin Ahmed** is vice chair and clinical associate professor of emergency medicine at the University of Iowa's Carver College of Medicine in Iowa City. The authors have indicated no relationships to disclose relating to the content of this article.

DOI: 10.1097/01.JAA.0000433900.22000.f0

Copyright © 2013 American Academy of Physician Assistants



**FIGURE 1.** Non-contrast brain CT showing lobulated hypodensity in the left frontal region with surrounding moderate edema

**Imaging studies and testing** ECG showed a normal sinus rhythm without QT prolongation or ischemic changes. Pertinent laboratory studies included potassium, 3.1 mEq/L; blood urea nitrogen (BUN), 25 mg/dL; creatinine, 1.2 mg/dL; white blood cell (WBC) count, 7,200 cells/mm<sup>3</sup>; hemoglobin, 12.1 g/dL; and platelets, 295,000 cells/mm<sup>3</sup>. Her troponin level and international normalized ratio were normal.

An emergent non-contrast brain computed tomography (CT) scan showed a 3.5 x 2.2 cm lobulated hypodensity in the left frontal region that appeared to have a possible small focus of hemorrhage versus calcification. A moderate amount of edema surrounded this area (Figure 1).

While reviewing the CT with the radiologist, the patient's clinicians were summoned to the patient's room via overhead page. On arrival, they found the patient to be asystolic with CPR in progress. The nurse reported that the patient had suffered a seizure that lasted about 30 seconds, which caused bradycardia and eventual cardiac arrest. After about 20 seconds of CPR only without the administration of any medications, the patient regained consciousness and was completely alert and able to speak, with a normal heart rate in sinus rhythm. Pacer pads were placed and the patient

was given 10 mg of dexamethasone IV and 1,500 mg phenytoin equivalents of fosphenytoin IV to help reduce the edema surrounding the brain lesion and to prevent further seizure activity.

A neurologist arrived in the ED to evaluate the patient. During the interview, the patient stated that she “felt funny,” at which point she suffered a generalized tonic clonic seizure with her eyes deviating to the right side; she subsequently became bradycardic and then asystolic. After 30 seconds of CPR only, without the administration of any medications, the patient again regained pulses and became awake and alert.

As the neurologist resumed the examination, a cardiologist was emergently consulted regarding the asystolic episodes. The cardiologist quickly arrived in the ED to assess the patient. Shortly after the cardiologist’s arrival, the patient said, “It’s going to happen again,” and had a seizure and third episode of asystole. CPR was initiated once again and after about 30 seconds of asystole, the patient regained consciousness and alertness without the administration of any medications (Figure 2). At this point, the patient was intubated with rapid-sequence induction technique for airway protection and was admitted to the medical ICU.

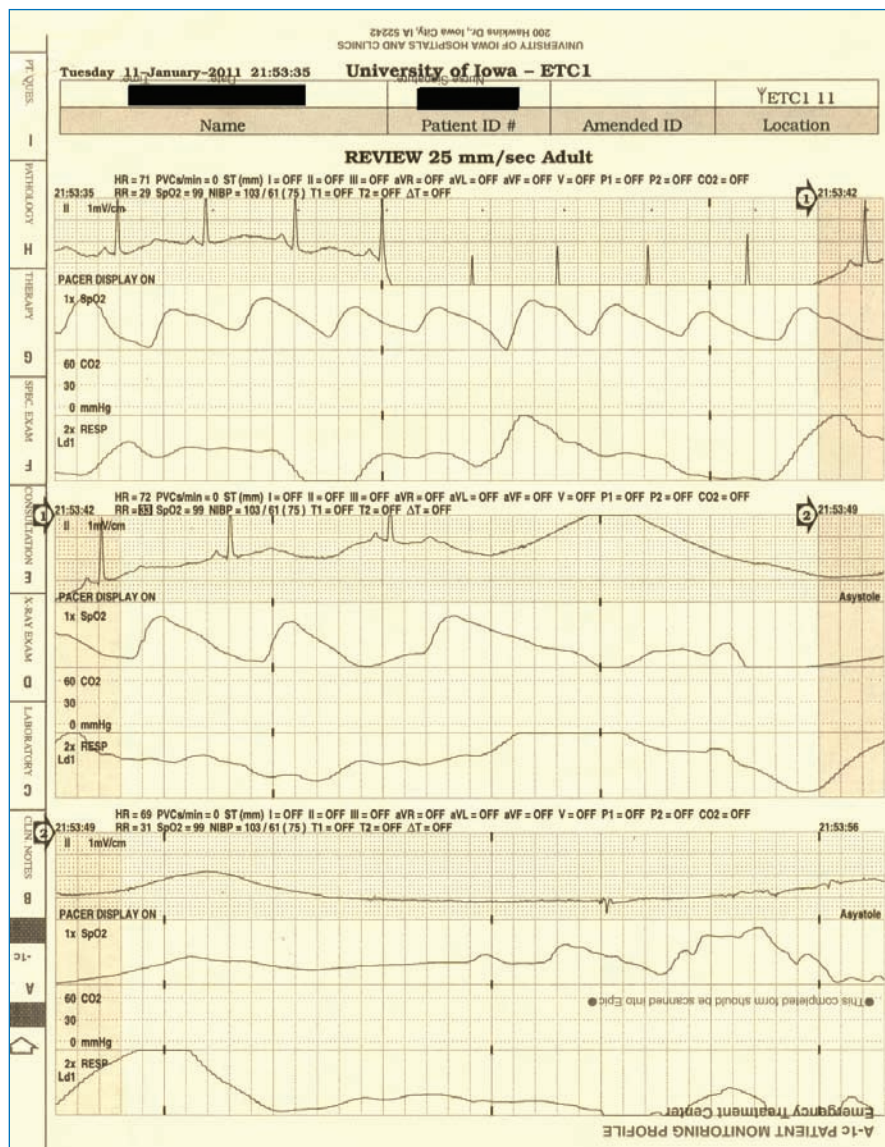
During her hospitalization, she was treated primarily with antiepileptic medications and received a left-sided dual-chamber pacemaker. The intracranial lesion causing her seizures was felt to be a metastasis of her breast cancer. After her clinical condition stabilized, she underwent resection of the lesion and continued radiation and chemotherapy.

## DISCUSSION

Ictal asystole is a rare cause of transient cardiac arrest secondary to seizure activity. Ictal asystole can occur in any form of epileptic activity, often occurring in patients with normally conducting hearts, and is thought to be a component of sudden unexpected death in epilepsy.<sup>1-4</sup> The incidence of sudden unexpected death in epilepsy varies and is thought to be 0.09 per 1,000 patient years in patients newly diagnosed with epilepsy and 9 per 1,000 patient years in patients who are candidates for epileptic surgery (in which the seizure

focus is surgically isolated or resected from the brain).<sup>5</sup>

In one study, only 7 of 2,003 patients undergoing long-term EEG monitoring had ictal asystole. All occurrences were associated with temporal lobe epileptic activity.<sup>1</sup> In another study of 81 patients undergoing long-term EEG monitoring, only one patient had ictal asystole.<sup>6</sup> Little investigation outside of chronic epilepsy has been conducted into the frequency of ictal asystole. The condition appears to be most common in patients with chronic epilepsy, especially from the temporal lobe and insular regions. In any clinical scenario that might cause epileptic activity in the temporal or insular regions (brain tumor, brain hemorrhage, head trauma), ictal asystole may be a concern, despite the relative risk of these mechanisms not having been quantified in the current literature.



**FIGURE 2.** The cardiac rhythm strips show progressive bradycardia deteriorating into asystole. Return of normal sinus rhythm correlated with the patient’s onset, progression, and termination of seizure activity.

**Key points**

- Ictal asystole is a cardiac event associated with a large parasympathetic output triggered by seizure activity.
- Standard laboratory and imaging evaluation is needed to evaluate for neurological, cardiac and electrolyte-associated causes of the cardiac event.
- Immediate actions needed to treat someone suffering from suspected ictal asystole are standard ACLS therapy as well as emergent seizure control.
- Urgent neurology and cardiology consultations are recommended.
- Patients will require long-term seizure control and possible implanted pacemaker for long-term care.

**Cause** Ictal asystole is a result of a large parasympathetic output triggered by the seizure, which results in bradycardia to the point of asystole. The phenomenon was first described by Russel in 1906 and is part of a wide range of arrhythmias that can occur as a result of any type of seizure activity, although it most often occurs due to partial seizures.<sup>7</sup> Men are much more commonly affected than women, and seizures emanating from the temporal lobe (specifically the left insular cortex) are most often implicated.<sup>8</sup>

**Clinical presentation** Patients with ictal asystole present with signs and symptoms of a partial seizure as well as loss of muscle tone.<sup>9</sup> This can also be confused with a transient ischemic attack or stroke as in our patient. Patients who have ECG monitoring during their seizures will first have bradycardia and then asystole with no palpable pulse, which spontaneously resolves with the abortion of the seizure activity.

**Diagnosis** If the patient has a known history of epilepsy, then the diagnosis may be more straightforward. However, in our patient with previously unknown brain mass, this was not clear, and there was confusion about whether the patient had had a stroke complicated by a seizure or whether a primary cardiac event was causing the recurrent episodes of asystole. A thorough history and physical examination followed by comprehensive electrolyte panel, complete blood cell count, troponin level, urine drug screen, ECG, and non-contrast brain CT are important elements of the initial evaluation. Neurology and cardiology consultations should be obtained if the diagnosis of ictal asystole is being entertained.

**Treatment** In the undifferentiated patient, asystole should be treated using standard advanced cardiovascular life support (ACLS) algorithms, which may be supplemented with endotracheal intubation if needed. In patients with high suspicion for ictal asystole, the same primary maneuvers (including IV access, fluids, and appropriate monitoring) should be conducted followed by quick initiation of antiepileptic therapy. Benzodiazepines can be used to abort the seizure (but should be used with caution in bradycardic patients). The patient should then receive an antiepileptic medication such as leve-

tiracetam or divalproex sodium. Care must be ensured not to use antiepileptic drugs such as phenytoin, which affect the mechanism of action of cardiac conductive tissue.<sup>7</sup> In addition, any correctable electrolyte abnormalities should be addressed to optimize cardiac conduction.

The control of seizures is the single most important factor in the prevention of ictal asystole. Long-term treatment includes chronic antiepileptic medications or epileptic surgery as well as an implanted cardiac pacemaker.<sup>2,8,10</sup> Pacemaker implantation decreases the number of syncopal episodes and their associated trauma as well as the risk of ictal asystole.<sup>11-13</sup> Patients also need long-term follow-up with a neurologist and cardiologist.

**CONCLUSION**

Ictal asystole is a rare cause of cardiac arrest. All patients in cardiac arrest should be treated according to current ACLS guidelines. If return of spontaneous circulation is achieved, a thorough evaluation should be conducted to evaluate for possible causes of cardiac arrest, including ictal asystole. Once the diagnosis of ictal asystole is strongly considered, the patient should receive standard supportive care, antiepileptic therapy, and evaluation by a neurologist and cardiologist for long-term seizure control therapy and consideration for an implanted cardiac pacemaker. **JAAPA**

**REFERENCES**

1. Lanz M, Oehl B, Brandt A, Schulze-Bonhage A. Seizure induced cardiac asystole in epilepsy patients undergoing long term video-EEG monitoring. *Seizure*. 2011;20(2):167-172.
2. Nei M. Cardiac effects of seizure. *Epilepsy Curr*. 2009;9(4):91-95.
3. Ryvlin P, Montavont A, Kahane P. Sudden unexpected death in epilepsy: from mechanisms to prevention. *Curr Opin Neurol*. 2006;19(2):194-199.
4. Wolber T, Namdar M, Duru F. Heart obeys the brain: seizure ceases cardiac rhythm. *Pacing Clin Electrophysiol*. 2010;33(8):e72-e75.
5. Tomson T, Nashef L, Ryvlin P. Sudden unexpected death in epilepsy: current knowledge and future directions. *Lancet Neurol*. 2008;7(11):1021-1031.
6. Zijimans M, Flanagan D, Gotman J. Heart rate changes and ECG abnormalities during epileptic seizures: prevalence and definition of and objective clinical signs. *Epilepsia*. 2002;43(8):847-854.
7. Erle CH Lim, Shih-Hui Lim, Einar Wilder-Smith. Brain seizures, heart ceases: a case of ictal asystole. *J Neurol Neurosurg Psychiatry*. 2000;69:557-559.
8. Carvalho KS, Salanova V, Markand ON. Cardiac asystole during a temporal lobe seizure. *Seizure*. 2004;8(8):595-599.
9. Ghearing GR, Munger TM, Jaffe AS, et al. Clinical cues for detecting asystole. *Clin Auton Res*. 2007;17(4):221-226.
10. Novy J, Carruzzo A, Pascale P, et al. Ictal bradycardia and asystole: an uncommon cause of syncope. *Int J Cardiol*. 2009;133(3):e90-e93.
11. Moseley BD, Ghearing GR, Munger TM, Britton JW. The treatment of ictal asystole with cardiac pacing. *Epilepsia*. 2011;52(4):e16-e19.
12. Strzelczyk A, Cenusa M, Bauer S, et al. Management and long term outcome in patients presenting with ictal asystole or bradycardia. *Epilepsia*. 2011;52(6):1160-1167.
13. Zubair S, Arshad AB, Saeed B, et al. Ictal asystole—late manifestation of partial epilepsy and importance of cardiac pacemaker. *Seizure*. 2009;18(6):457-461.