

A case of acute traumatic subdural hematoma in a child with previous bilateral encephaloduroarteriosynangiosis

Merlin Curry · Nathaniel Whitney · Neil Roundy ·
Nathan R. Selden

Received: 11 July 2013 / Accepted: 17 September 2013 / Published online: 1 October 2013
© Springer-Verlag Berlin Heidelberg 2013

Abstract The authors report the case of a 5-year-old female with right-sided hemiparesis and aphasia secondary to moyamoya disease, who had previously undergone staged bilateral encephaloduroarteriosynangiosis procedures. A subsequent ground-level fall caused an acute traumatic subdural hematoma with mass effect and neurological decline. She underwent emergency hematoma evacuation and decompressive craniectomy, which required interruption of the superficial temporal artery that had been used for indirect bypass, followed later by autologous cranioplasty. There were no acute or long-term ischemic events related to the occurrence or treatment of the traumatic hematoma. Follow-up angiography revealed extensive spontaneous vascular collateralization in the field of the decompressive craniectomy and cranioplasty. The patient returned to her pre-injury neurological baseline.

Keywords Moyamoya · Trauma · Subdural hematoma · EDAS · Angiogenesis · Neovascularization

Introduction

Moyamoya disease is the progressive acquired involution of the anterior cerebral circulation of largely undefined pathophysiology, which results in cerebral ischemia manifested by headache, stroke, hemorrhage, and/or seizures [5]. Moyamoya disease has an annual worldwide incidence of 0.35 to 0.94 per 100,000 population, with a predilection for patients of Asian ancestry and female gender [4]. In children, aspirin therapy and indirect surgical revascularization

using encephaloduroarteriosynangiosis (EDAS) or other techniques are the mainstays of disease treatment [1, 5].

Cranial trauma in children with moyamoya disease poses substantial risk. Chronic neurologic deficits, including weakness and gait disturbance, may increase the risk of falls and lifelong antiplatelet therapy may increase the risk of traumatic hemorrhage. Children who have previously undergone EDAS or other cerebral revascularization procedures may be at additional risk of local injury at the craniotomy site(s).

We report the case of a 5-year-old female who had previously undergone bilateral EDAS procedures for moyamoya disease with successful remission of recurring cerebrovascular ischemia, who then suffered cranial injury due to a ground-level fall resulting in an acute subdural hematoma. To our knowledge, the surgical management of an acute traumatic subdural hematoma in a patient with moyamoya disease status post revascularization has not been previously detailed [6].

Methods

A US National Library of Medicine PubMed search for “EDAS,” “traumatic,” “subdural,” and “moyamoya” was undertaken. The search was not limited. This literature search yielded one case report of a spontaneous acute subdural hematoma in a patient who had undergone EDAS, in which conservative treatment resulted in symptomatic improvement [8], and one case report of a chronic subdural hematoma associated with encephalomyosynangiosis (EMS) published in 1982 [7]. There were no reports of acute traumatic hematomas.

Case report

History and presentation This 5-year-old female with moyamoya disease had previously presented with right-sided

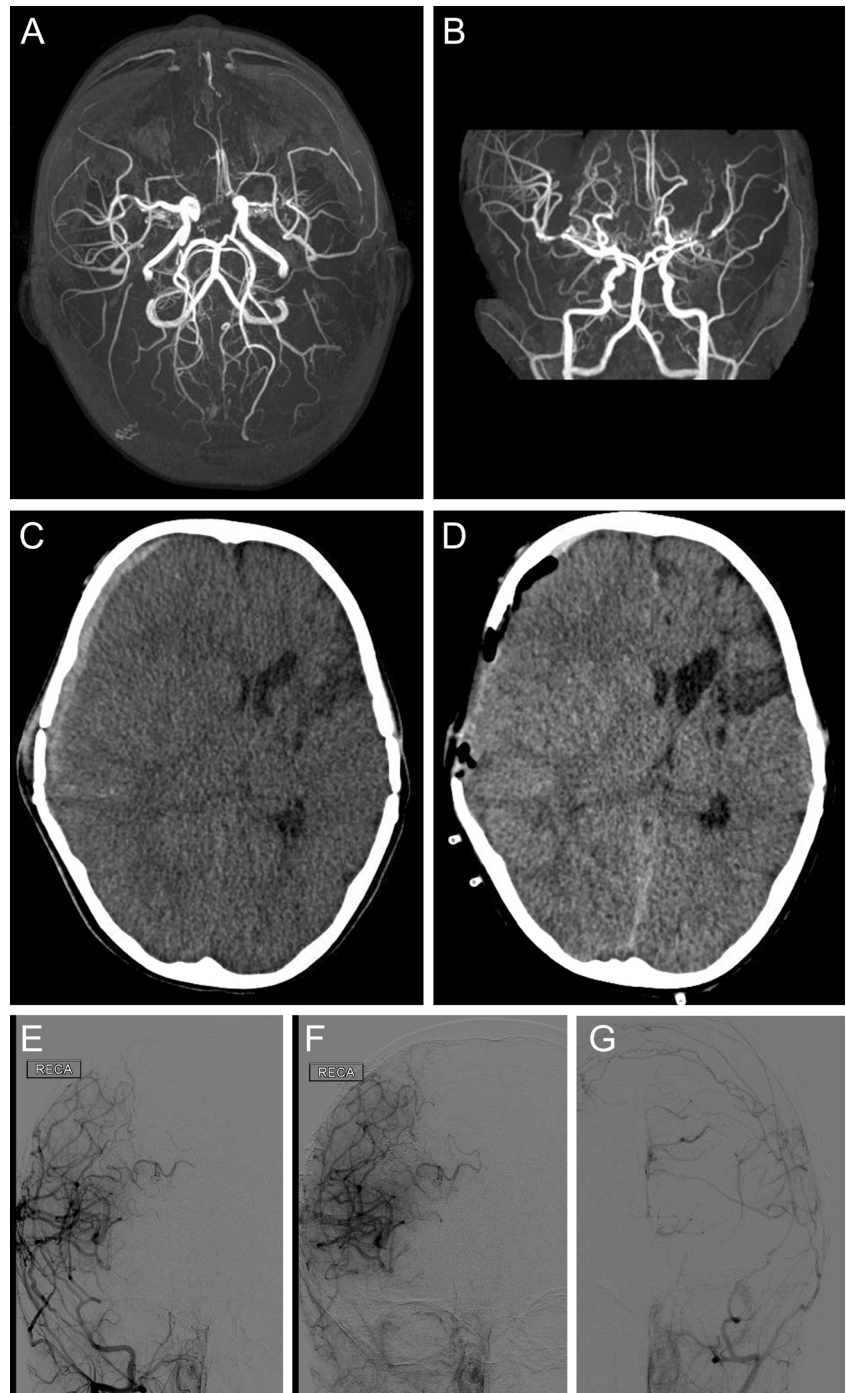
M. Curry · N. Whitney · N. Roundy · N. R. Selden (✉)
Department of Neurological Surgery, Oregon Health & Science
University, Mail Code CH8N, 3303 SW Bond Ave, Portland,
OR 97239, USA
e-mail: seldenn@ohsu.edu

hemiparesis and aphasia from a left-sided anterior circulation ischemic stroke. The patient underwent staged left and then right EDAS procedures, each supplemented by frontal burr holes for indirect revascularization, approximately 3 months apart (Fig. 1a, b). The patient was maintained on daily, orally administered aspirin (81.5 mg) and oral hydration.

Two months after the second right-sided EDAS procedure, she experienced a witnessed ground-level fall not associated

with a seizure or other neurological prodrome, during which she struck her right frontotemporal region on the edge of a tub. Following the injury, she suffered a rapid neurological decline, obtundation, and vomiting. She was evaluated at a nearby hospital where brain computed tomography (CT) revealed a large acute subdural hematoma with substantial midline shift (Fig. 1c). She was intubated and transferred emergently to our center for further evaluation and definitive neurosurgical management.

Fig. 1 Patient imaging at multiple time points. **a, b** MR angiogram after EDAS showing successful indirect anastomosis of the STA and MCA circulations. **c** CT of the brain showing acute right-sided subdural hematoma with substantial midline shift; cisternal effacement was also present (not shown). **d** CT of the brain after emergent hematoma evacuation and frontotemporal craniectomy. **e, f** Digital subtraction angiography 12 months after injury demonstrates spontaneous revascularization in the area of the previous craniectomy and subsequent autologous cranioplasty reconstruction, **g** as well as intact indirect revascularization on the left side, unaffected by trauma



Operation On arrival, the patient was intubated and sedated, with a GCS of 13 (E2 V5 M6), left greater than right hemiparesis, and obtundation, but no cranial nerve palsy. She underwent emergency hematoma evacuation and decompressive craniectomy (Fig. 1d), with cryopreservation of the cranial bone flap. The irregular, linear frontotemporal incision from the EDAS procedure, which followed the course of the superficial temporal artery (STA), was incorporated into the scalp flap for the trauma craniectomy, limiting the extent of decompression, especially posteriorly, although the brain was slack at the time of duraplasty and closure. The STA, which did not yet have substantial direct brain collaterals, was necessarily sacrificed. The dura, which, at the time of EDAS surgery, had been multiply opened in an irregular pattern sparing the middle meningeal artery (MMA), was now widely opened with sacrifice of the MMA. Platelets and cryoprecipitate were administered during the surgical procedure.

Postoperative course The patient made a rapid neurological recovery, returning substantially towards pre-injury baseline during the primary hospitalization. Seventeen days later, she underwent autologous cranioplasty using titanium microplates and screws to secure the bone flap, without any additional intentional indirect revascularization to replace the STA [3]. The dura was loosely reapproximated and supplemented with DuraGen (Integra LifeSciences Corp., Plainsboro, NJ) in the epidural space. Daily aspirin therapy was restarted 1 month after the autologous cranioplasty.

Magnetic resonance (MR) imaging 7 months after the injury, decompression, and cranioplasty revealed no additional areas of ischemia, pathological fluid collection, hydrocephalus, or other complication of injury, decompressive craniectomy, or reconstructive surgery. Her neurological examination returned to her pre-injury baseline. Surprisingly, the patient had a strong STA pulse on the injured and reconstructed right side. Digital subtraction angiography 12 months after reconstruction demonstrated robust spontaneous revascularization from the right external carotid artery circulation throughout the area of decompressive and reconstructive surgery (which incorporated the original ipsilateral frontal burr hole), despite the fact that the only intentional indirect vascular graft (the STA) had been interrupted at the time of those operations (Fig. 1e, f). Robust collaterals were also present at the previous contralateral EDAS and frontal burr hole sites.

Discussion

We present the case of a 5-year-old female status post bilateral EDAS procedures for moyamoya disease who suffered an acute traumatic subdural hematoma while on daily aspirin therapy. She recovered well from her injury after emergency

hematoma evacuation and decompressive craniectomy, with the development of extensive spontaneous collaterals in the area of the decompressive craniotomy and reconstruction used to treat the traumatic injury.

Published reports of cranial trauma after surgical revascularization for moyamoya disease are rare. Takeuchi and colleagues described a 17-year-old male status post bilateral EDAS procedures for moyamoya disease who developed a chronic subdural hematoma after a ground-level fall, resulting in reduced flow through the spontaneous vascular anastomoses [8].

Some centers have abandoned the EDAS procedure, and particularly STA dissection and subdural transposition, in the treatment of moyamoya disease, in favor of spontaneous indirect revascularization through the creation of many burr holes with durotomy [2]. In some cases, this surgical approach yields indirect vascular anastomoses at the burr hole sites that are as or more robust than those seen from indirect STA collaterals. The senior author (NRS) routinely supplements craniotomy for EDAS with frontal and/or parietal burr holes, occasionally observing on angiograms obtained 6 months after surgery that the most robust anastomoses form via the burr hole sites.

In the present case, the creation of wide areas of scalp, bony, and dural opening at the time of the decompressive craniectomy and reconstruction created a similar anatomical milieu on a much larger scale, resulting in spontaneous indirect revascularization as or more extensive on the patient's injured side than on the uninjured one.

Despite the fact that the patient received platelets and cryoprecipitate at the time of surgical management of the injury and was off of daily aspirin therapy for a month to protect against recurrent hematoma, she did not experience any new clinical or radiographic cerebral ischemic events. This is likely because she already had experienced substantial maturation of the EDAS indirect bypass to the more compromised left cerebral hemisphere, which had been revascularized first, prior to the injury.

Conclusion

We report a good neurological outcome from surgical management in the case of a 5-year-old female status post bilateral EDAS procedures for moyamoya disease who suffered an acute traumatic subdural hematoma while taking aspirin daily. To the authors' knowledge, this is the first reported description of surgical management of acute intracranial injury in a moyamoya patient after indirect revascularization, as well as the first to report a good patient outcome after an acute traumatic hematoma following EDAS. Substantial spontaneous indirect cerebral revascularization occurred in the field of the decompressive craniectomy and reconstruction, despite the necessary sacrifice of the STA at the time of the trauma

surgery. The management of traumatic intracranial hemorrhage in patients on antiplatelet therapy and at risk for acute cerebral ischemia is complex and requires careful, individualized management. In this case, the presence of a mature indirect bypass to the cerebral hemisphere most compromised by the underlying moyamoya disease at the time of injury likely contributed to a positive clinical and neurological outcome.

Acknowledgments The authors thank Shirley McCartney, Ph.D., for the editorial assistance and Andy Rekito for the figure preparation.

Conflict of interest The authors report no conflict of interest concerning the materials or methods used in this study or the findings specified in this paper.

References

1. Adelson PD, Scott RM (1995) Pial synangiosis for moyamoya syndrome in children. *Pediatr Neurosurg* 23(1):26–33
2. Kim SK, Cho BK, Phi JH, Lee JY, Chae JH, Kim KJ, Hwang YS, Kim IO, Lee DS, Lee J, Wang KC (2010) Pediatric moyamoya disease: an analysis of 410 consecutive cases. *Ann Neurol* 68(1):92–101. doi:10.1002/ana.21981
3. Piedra MP, Thompson EM, Selden NR, Ragel BT, Guillaume DJ (2012) Optimal timing of autologous cranioplasty after decompressive craniectomy in children. *J Neurosurg Pediatr* 10(4):268–272. doi:10.3171/2012.6.PEDS1268
4. Reis CV, Safavi-Abbasi S, Zabramski JM, Gusmao SN, Spetzler RF, Preul MC (2006) The history of neurosurgical procedures for moyamoya disease. *Neurosurg Focus* 20(6):E7
5. Scott RM, Smith ER (2009) Moyamoya disease and moyamoya syndrome. *N Engl J Med* 360(12):1226–1237. doi:10.1056/NEJMra0804622
6. Scott RM, Smith JL, Robertson RL, Madsen JR, Soriano SG, Rockoff MA (2004) Long-term outcome in children with moyamoya syndrome after cranial revascularization by pial synangiosis. *J Neurosurg* 100(2 Suppl Pediatrics):142–149. doi:10.3171/ped.2004.100.2.0142
7. Sonobe M, Takahashi S, Kubota Y, Shirane R (1982) Chronic subdural hematoma developing after EMS for moyamoya disease. *No Shinkei Geka* 10(8):857–859
8. Takeuchi S, Ichikawa A, Koike T, Tanaka R, Arai H (1992) Acute subdural hematoma in young patient with moyamoya disease—case report. *Neurol Med Chir (Tokyo)* 32(2):80–83