

Complications of Use of the Neodymium:Yttrium-Aluminum-Garnet Laser in Neurosurgery

K. K. Jain, M.D.

University Neurosurgical Clinic, Duesseldorf, Germany

Review of the clinical records of 32 patients who underwent operation for brain tumors with the use of the neodymium:yttrium-aluminum-garnet (Nd:YAG) laser during a 4-month period revealed 5 cases of complications related to laser use. One death was presumed to be due to intratumor explosion (the popcorn effect) after excessive Nd:YAG laser application. The other death was due to heat necrosis of the brain stem after radiation of an ependymoma of the 4th ventricle. Two patients suffered neurological deficits. One had facial palsy after radiation of the site of attachment of a meningioma to the petrous bone. The other suffered aphasia and hemiparesis due to heat damage to the cerebral cortex after laser coagulation of the overlying dura mater. The fifth patient suffered postoperative hemorrhage in a residual necrotic chromophobe adenoma after a transsphenoidal approach using the Nd:YAG laser. These complications are preventable. Suggestions are made for the safe use of this laser. (*Neurosurgery* 16:759-762, 1985)

Key words: Laser coagulation, Laser complication, Laser neurosurgery, Neodymium:yttrium-aluminum-garnet (Nd:YAG) laser, Neurosurgical complication

Lasers are being used with increasing frequency in neurosurgery. The carbon dioxide laser is used most commonly. In the U.S.A., the use of the neodymium:yttrium-aluminum-garnet (Nd:YAG) laser in human surgery is limited by the Food and Drug Administration.

The Nd:YAG laser was introduced into clinical surgery by Kiefhaber et al. in 1975 for the endoscopic control of gastrointestinal hemorrhage (6). The hemostatic properties of this laser attracted the attention of neurosurgeons in Europe, who have used it since. The current uses of this laser for brain tumor surgery as reported in the literature are summarized in Table 1 (1, 2, 4, 5, 7, 9). A few complications of the use of the laser in neurosurgery have been mentioned, but there is no publication dealing specifically with this problem.

Oeckler et al. used the Nd:YAG laser through a transphenoidal or transcranial approach to operate on 30 patients with a variety of intrasellar and suprasellar lesions (7). The complications included 1 postoperative death resulting from cerebrovascular insufficiency secondary to what the authors described as spasm of the internal carotid artery, which was encased by a parasellar meningioma that was radiated by the Nd:YAG laser. The other complication was a postoperative hemorrhage.

CLINICAL MATERIAL

This report is based on five patients who suffered complications resulting from the use of the Nd:YAG laser during neurosurgical procedures (Table 2). These were detected during a review of the clinical records of 32 patients operated on with use of the Nd:YAG laser during a 4-month period. The diagnosis was an intracranial tumor in all cases. The criteria used in listing the cases as complications were: (a) the Nd:YAG laser was used as a major tool for tumor ablation or coagulation during the procedures; (b) the complication was rare with conventional nonlaser techniques used in similar operations carried out by the same surgeons; (c) the recommended safe parameters of laser power and time of application (3) were exceeded in these cases; and (d) evidence of heat damage to normal tissue was obtained at autopsy (Case 5).

We reviewed these complications and suggest possible mechanisms and preventive measures.

Case 1

In this case, postoperative hemorrhage occurred 5 hours after transsphenoidal hypophysectomy. The probable site of the hemorrhage was the residual tumor, which had been rendered necrotic by Nd:YAG laser radiation, but not excised. The laser beam was applied with a hand-held fiberoptic cable under the operating microscope and could thus hit a target beyond the vision of the surgeon. Residual tumor excised during evaluation of the hematoma by a transfrontal approach showed undamaged tumor cells.

Case 2

In this case, high power laser was used to destroy the attachment of meningioma over the petrous bone. No irrigation with cold saline was done. The facial nerve palsy was probably a result of heat damage.

Case 3

In this case, the craniotomy was much larger than the meningioma presenting on the surface of the left hemisphere. The dura mater was radiated with the Nd:YAG laser to obliterate the large dural vessels. The exact power and duration of application were not recorded. When the dura mater was opened, pallor and disruption of the vascular pattern of the underlying cortex was observed. Laser use was discontinued and the tumor was removed with conventional techniques, without any trauma to the surrounding brain. There was no postoperative hemorrhage or edema in the operative area. The aphasia and hemiplegia, which did not improve, are presumed to be due to cortical injury by laser heat that penetrated through the dura mater.

Case 4

In this case, a unilateral suboccipital craniectomy was limited to the surface presentation (2 × 3 cm) of the posterior fossa meningioma. Laser power (40 W) had been applied over

this area continuously for 10 minutes when sudden cardiac arrest and death occurred. There was no clinical explanation of this death. At autopsy, no evidence of air embolism or cerebral edema was found. The tumor contained multiple cavities measuring up to 5 mm in diameter, with surrounding areas of tumor necrosis.

A likely explanation of this death is the "popcorn effect" (Fig. 1), as described by Halldorsson et al. (3). After the application of 40 W of the defocused Nd:YAG laser beam, the superficial surface of the tumor is blanched and not vaporized. Prolonged application of the laser leads to enhanced heat absorption through a zone of coagulated tissue (temperature, 70° C) until a temperature of 100° C is reached at depth. Steam is generated by cell vaporization, and the explosive effect is caused by the closed space without any outlet for the steam. This force is transmitted to the brain through the tumor. In this case, the brain stem could have been compressed by the expansive force of explosion. For devascularizing such a tumor, it is recommended that one use lower powers (not exceeding 20 W) and short bursts lasting 1 to 2 seconds, which are adequate for coagulating the blood vessels and reducing the volume of the tumor.

Case 5

In this case, the Nd:YAG laser was used to ablate a layer of ependymoma over the floor of the 4th ventricle. The power used was not excessive, and short bursts were used. However, the laser was used in a critical part of the brain. Some authors claim that the Nd:YAG laser is absorbed selectively by the

tumor and has a predictable depth effect (2). It is possible to predict the depth of penetration of the Nd:YAG laser in normal brain (10), but it is difficult to do so in cases of tumor with unknown optical properties (Fig. 2). It is difficult to

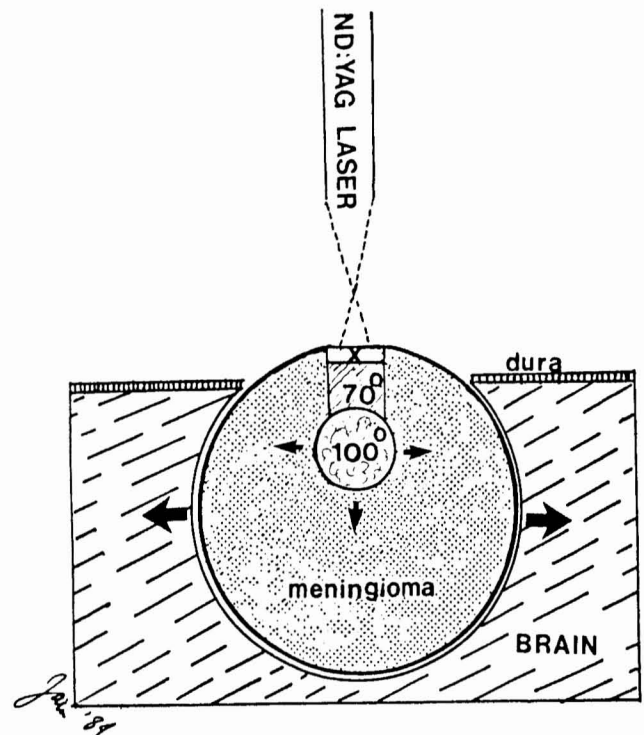


FIG. 1. Popcorn effect. X, the superficial surface of the tumor is blanched after exposure for 15 seconds to 40 W of a defocused Nd:YAG laser beam over a spot size of 1.7 mm (power density of 1500 W/cm²). There is enhanced laser absorption through the zone of coagulation (70°) and steaming with cavitation at depth (100°). The direction of the explosive force is indicated by the arrows.

TABLE 1
Current Uses of the Nd:YAG Laser in the Surgery of Intracranial Tumors

1. Meningiomas—particularly the following types: highly vascular, invading bone, invading venous sinuses, and en plaque
2. Pituitary tumors
3. Tumors of the posterior fossa and craniospinal junction
4. Intraventricular tumors

TABLE 2
Five Cases of Complications Due to the Nd:YAG Laser

Case	Age & Sex	Diagnosis	Clinical Status	Operation	Mode of Use of Nd:YAG Laser	Complication
1	62 M	Chromophobe adenoma	Headache, endocrinological disturbances	Transsphenoidal hypophysectomy	55 W-focused, continuous, spot—0.5 mm	Postoperative hemorrhage, reoperation
2	53 M	Middle fossa meningioma	Headache, no deficit	Craniotomy, tumor excision	50 W-defocused, continuous, on petrous bone	Complete 7th nerve palsy
3	60 F	L parietal meningioma	Focal seizures, no deficit	Craniotomy, radiation of dura with Nd:YAG laser	40 W, continuous, defocused	Heat injury to the cortex, aphasia, R hemiplegia
4	50 F	Posterior fossa (R) meningioma	Papilledema, cerebellar ataxia	Suboccipital craniectomy, radiation of tumor with Nd:YAG laser	40 W, continuous, defocused, spot—1.7 mm, 10 min	Cardiac arrest, death
5	34 F	Ependymoma of the 4th ventricle	Papilledema, neck stiffness, ataxia, nystagmus	Posterior fossa craniotomy, radiation of tumor with Nd:YAG laser	30 W, focused, spot—0.5 mm, intermittent application, 2-3 s	Coma and death 2 d after operation, autopsy showed heat damage to the brain stem

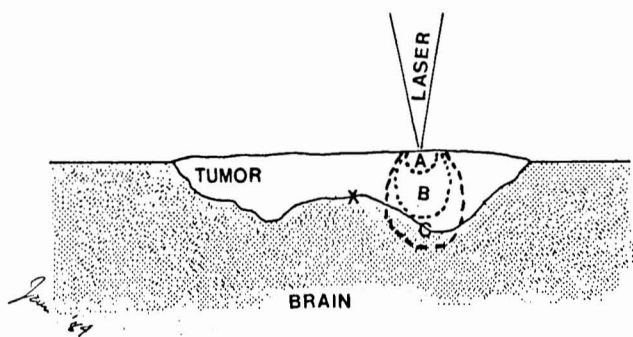


FIG. 2. Nd:YAG laser penetration in a layer of tumor of unknown optical properties. X, boundary between tumor and normal brain tissue, which is not usually well demarcated. Extent of laser-induced tumor destruction and coagulation: A, inadequate; B, ideal; C, excessive, encroaching on normal brain tissue. In practice, it is difficult to achieve B and persistence with Nd:YAG laser application leads to Situation C (Case 5).

TABLE 3

Complications of Use of the Nd:YAG Laser in Neurosurgery

1. Intratumor explosion (popcorn effect)
2. Damage to cranial nerves at skull base from radiation of overlying bone
3. Postoperative hemorrhage in laser-radiated necrotic tumor tissues
4. Damage to normal brain by heat penetration through dura mater or a thin layer of tumor

TABLE 4

Precautions in the Use of the Nd:YAG Laser

1. Do not use this laser on patients without adequate training and laboratory exercise.
2. Use proper laser equipment. Do not use the laser if the power output cannot be monitored intraoperatively.
3. Do not use on tumors in critical locations such as the brain stem and the hypothalamus.
4. Do not use more than 20 W continuously over one spot for more than 2 seconds. Use short, intermittent pulses.
5. Use cold saline irrigation over area of application.
6. Do not use freehand under the operating microscope. Use a micromanipulator.
7. Do not leave laser-necrosed tumor in situ. Remove it.

adjust the laser energy to penetrate the proper depth to the boundary between the tumor and normal brain tissue. Low powers are inadequate and high powers or prolonged application lead to penetration beyond the tumor into normal brain tissue, as happened in this case. The patient did not regain consciousness because of brain stem damage and died. Sections of the brain stem showed heat necrosis extending as far as 2 to 3 mm beneath the area of tumor removal. There was no residual tumor.

DISCUSSION

Potential complications of Nd:YAG laser use, including those that occurred in our patients, are summarized in Table 3. Two deaths in the 32 patients reviewed constitute a mortality of 6.2%. Three neurological complications indicate a morbidity of 9.3%. Other complications and causes of death in these patients that are unrelated to the use of the laser are not included in this report. In none of the 32 cases was the

Nd:YAG laser used for a spinal cord tumor. During the same period, the case records of 43 patients operated on with the use of a CO₂ laser for a variety of brain and spinal cord tumors were also reviewed. No complications related to the use of this laser were encountered. All complications mentioned are preventable.

Use of the Nd:YAG laser in the following situations is risky:

1. Tumors in functionally critical areas of the brain. The CO₂ laser is safer as the tumor is vaporized in thin layers and heat penetration in tissues is only a fraction of a millimetre.
2. Transsphenoidal surgery. It is unnecessary to use the Nd:YAG laser. All of the steps of transsphenoidal hypophysectomy can be performed more safely with the CO₂ laser.
3. Radiation of postoperative brain cavities for hemostasis. Nd:YAG laser penetration adds to brain damage. Capillary oozing can be controlled with the CO₂ laser, which is preferable to lining the cavity with hemostatic substances.

Precautions for the safe use of the Nd:YAG laser are listed in Table 4.

Laser equipment

A Nd:YAG laser with a wavelength of 1064 nm is provided almost exclusively by most manufacturers. A Nd:YAG laser with a wavelength of 1236 nm penetrates deeper into tissues and is considered unsuitable for use in neurosurgery (8). Most of the Nd:YAG units have an output of 70 to 100 W, which is far in excess of that needed by a neurosurgeon. An inexperienced operator is tempted to push the power output to maximum when dealing with a tough meningioma. The usual choice in Nd:YAG lasers is limited to single or continuous application. Most of these problems have been corrected in the Moletron 4000 Nd:YAG laser (Cooper Industries, Santa Clara, California). This laser has a maximal output of 40 W and has a repeat mode of application.

Conclusion

The Nd:YAG laser, with its deep and unpredictable penetration in tissues, can lead to various complications. These complications are preventable if the laser is used properly.

Received for publication, November 1, 1984; accepted, December 30, 1984.

Presented at the Congress on Laser Neurosurgery III, May 7, 1984, Chicago, Illinois.

Reprint requests: K. K. Jain, M.D., Walker Institute, 1964 Westwood Boulevard, Suite 220, Los Angeles, California 90025.

REFERENCES

1. Beck OJ: The use of the Nd:YAG and the CO₂ laser in neurosurgery. *Neurosurg Rev* 3:261-266, 1980.
2. Beck OJ: Nd:YAG laser therapy of tumors in the region of the foramen magnum. *Fortschr Med* 102:41-44, 1984.
3. Halldorsson T, Langerholc J, Senatori L: Thermal action of laser irradiation in biological material. *Appl Opt* 20:822-825, 1981.
4. Jain KK: Nd:YAG laser in neurosurgery. In Jaffe SN (ed): *Neodymium-YAG Laser in Medicine and Surgery*. New York, Elsevier Science Publishing Co, 1983, pp 132-144.
5. Jain KK: *Handbook of Laser Neurosurgery*. Springfield IL, Charles C Thomas, 1983.
6. Kiefhaber P, Nath G, Moritz K: Endoscopic control of massive gastrointestinal hemorrhage by irradiation with a high power Nd:YAG laser. *Prog Surg* 15:140-155, 1977.
7. Oeckler RC, Beck OJ, Frank F: Surgery of sellar region with Nd:YAG laser. *Fortschr Med* 102:218-220, 1984.
8. Stokes LF, Auth DC, Tanaka D, Gray JL, Gulacsik C: Biomedical utility of 1.34 μ m Nd:YAG laser radiation. *IEEE Trans Biomed Eng* 28:297-299, 1981.
9. Takeuchi J, Handa H, Taki W, Yamagami T: The Nd:YAG laser

in neurological surgery. *Surg Neurol* 18:140-142, 1982.

10. Wharen RE, Anderson RE, Scheithauer B, Sundt TM: The Nd:YAG laser in neurosurgery: Part 1. *J Neurosurg* 60:531-539, 1984.

COMMENTS

Because the CO₂ laser is not very hemostatic, the Nd:YAG laser is being considered for use in vascular tumors and malformations. It is a good coagulator because of its relatively low absorption coefficient in tissue that, on the other hand, carries a much higher risk of heat damage to surrounding tissue.

This heat spread was dramatically demonstrated during one of our laser workshops here in Dallas. We coagulated egg whites in a styrofoam cup with a Nd:YAG laser. Sufficient heat was transmitted through the apparently unaffected styrofoam that, when we picked up the cup, the bottom pulled out, having been fused by transmitted heat to the plastic table top beneath. We also saw the "popcorn effect" in the rat vena cava when the vessel exploded, apparently from severe heat buildup in the blood within.

I agree with the author that the application of this laser in clinical neurosurgery should be done very carefully and after quite a bit of study and laboratory evaluation of safe parameters. The Nd:YAG laser has been given an Investigational Device Exception Number by the U.S. Food and Drug Administration. Presently, its use in neurosurgery is limited to licensed investigators under agreement with the manufacturer as sponsor and only after approval of a precise protocol by each hospital's Institutional Review Board.

W. Robert Hudgins, M.D.
Dallas, Texas

As the laser continues to grow in importance as a neurosurgical tool, more wavelengths will be utilized for their particular effects. Although the American experience has concentrated primarily on carbon dioxide (wavelength = 10.6 nm), there has been a great deal of clinical experience in Europe and Japan using Nd:YAG (wavelength = 1.06 nm). Unfortunately, the biophysical effects of one wavelength cannot be extrapolated to another, and this article underscores

that fact in a sobering fashion. The tissue effect of a given wavelength is dependent on a number of physical factors, including absorption, scatter, chromophore/chromophobe ratio, length of application, and power density at the target. To make intelligent use of a given wavelength, the neurosurgeon must take these factors, individual for each, into consideration to direct the "biohazards" into a useful and controlled medical application. Experimental data on the neural effects of the Nd:YAG laser are available (1) and must be considered when one proposes clinical application. The addition of simple logic will allow the surgeon cautiously to extrapolate into the clinical setting. Just as the "errors" that allowed these complications could be deduced in retrospect, the precautions to prevent them could have been anticipated. On the other hand, one should not be so quick to condemn one of a number of variables that influence the eventual outcome of an individual procedure without convincing supportive evidence (Case 1). The importance of this communication is, I believe, in underscoring the potential danger in using this instrument, the most powerful ever placed in the hands of surgeons, without a firm understanding and appreciation of its potential, both positive and negative.

I disagree with Dr. Jain's insistence that the Nd:YAG laser must be used in conjunction with the micromanipulator and wedded to the operating microscope. This, in fact, decreases controllability by forcing a spot size (usually larger than desired) that is a function of the working distance of the surgeon. Because of its ability to pass through an optical cable, the beam can be brought almost directly to the target, reducing the potential for stray light striking nontarget tissue and decreasing the precision of application.

As new wavelengths are proposed for clinical use (e.g., Nd:YAG 1.2 nm), basic laboratory investigations into their individual "footprints" must be obtained. "To err is human, . . . to persist, devilish" (Webster).

Leonard J. Cerullo, M.D.
Chicago, Illinois

1. Burke LP, Rovin RA, Cerullo LJ, Brown JT, Petronio J: YAG lasers in neurosurgery, in Joffe SN, Mukerheide MC, Goldman G (eds): *Nd:YAG Lasers in Medicine and Surgery*. New York, Elsevier Science Publishing Co, Inc, 1983, pp 141-148.