

CASE STUDY

Brain activation during speech perception in a patient with a massive left hemisphere infarction

Juan Sahuquillo^{1,2}, Andreea Rădoi², Bessy Benejam², Carme Junqué³, Davinia Fernández-Espejo^{3,4}, & Maria A. Poca^{1,2}

¹Department of Neurosurgery and ²Neurosurgery and Neurotraumatology Research Unit, Vall d'Hebron University Hospital and Vall d'Hebron Research Institute, Universitat Autònoma de Barcelona, Barcelona, Spain, ³Department of Psychiatry and Clinical Psychobiology, University of Barcelona, Barcelona, Spain, and ⁴The Brain and Mind Institute, Department of Psychology, The University of Western Ontario, London, Ontario, Canada

Abstract

Background: Little is known about the regions involved in recovery from global aphasia in patients with malignant infarction after decompressive hemicraniectomy. This study reports a case of brain activation during speech perception in a right-handed patient with a massive left hemispheric infarction.

Methods: Decompressive hemicraniectomy was performed in a 20-year old woman with space-occupying infarction of the speech dominant hemisphere. Complete anterior, middle and part of the posterior cerebral artery territories of the left hemisphere, as well as posterior regions of the right middle cerebral artery territory, were affected. Neuropsychological testing and functional magnetic resonance imaging (fMRI) during speech perception were performed 10 months after stroke.

Results: The patient was able to walk, go up and down stairs independently and perform simple tasks at home. She was also well able to match visually and orally presented words with their corresponding pictures, despite large bilateral lesions in the posterior regions. fMRI revealed strong activation of the left temporo-occipital and parieto-occipital areas. In the right hemisphere was observed a small area of activation in the posterior part of the superior and middle temporal gyrus.

Conclusions: In aphasic patients, the activation of posterior bilateral associative areas might be used to support language perception.

Keywords

Functional magnetic resonance imaging, language, malignant middle cerebral artery infarction, neuropsychological assessment, stroke

History

Received 6 December 2012

Revised 30 May 2013

Accepted 7 July 2013

Published online 3 October 2013

Introduction

Malignant middle cerebral artery (MCA) infarction is characterized by the formation of massive oedema within and around infarcted brain tissue occurring in the initial phase and exerting a mass effect, which in many patients leads to increased intracranial pressure, transtentorial herniation and death. With conventional conservative treatment based on current standards in stroke management, mortality can be as high as 80%. Decompressive hemicraniectomy (DH) is a surgical technique in which a large bone flap is removed to allow the swollen brain to expand [1]. DH does not treat stroke directly, but a recent meta-analysis of three randomized clinical trials has reported excellent survival rates and an increase in cases of favourable functional outcome—without increasing the risk of persistent vegetative state—after surgical decompression [2, 3]. Controversy remains, however,

as to whether or not the residual disability is acceptable for both the patient and the caregivers [4], despite the fact that most patients and their relatives would retrospectively consent to being treated with DH when asked 6 months to 1 year after surgery [5, 6]. The debate is mostly centred on the one third of patients who survive but are categorized as 4 in the modified Rankin Scale (patients unable to walk and attend to their bodily needs without assistance) [4].

Traditionally, patients with infarctions of the speech-dominant hemisphere who are aphasic have been considered poor candidates for life-saving procedures such as DH due to the expectation—from neurosurgeons, neurologists, patients and their relatives—of severe disability and therefore poor patient-reported outcomes in terms of disability and quality-of-life [7]. Unexpected recovery from aphasia has been reported for years and the long-term outcome of aphasia is in many cases uncertain and unpredictable. Kastrau et al. [8] reported significant improvements in 13 out of 14 patients with left-dominant malignant infarctions and suggested that aphasic patients could also be candidates for and benefit from DH. The mechanisms involved in recovery from left hemispheric stroke are still highly speculative, but most of them

Correspondence: J. Sahuquillo, Department of Neurosurgery, Neurosurgery and Neurotraumatology Research Unit, Vall d'Hebron University Hospital, Passeig Vall d'Hebron 119-129, 08035 Barcelona, Spain. Tel: +34-932746213. Fax: +34-933931930. Email: sahuquillo@neurotrauma.net

are focused more on the activation of perilesional ('penumbra') brain tissue and less on the involvement of the contralateral hemisphere [9, 10]. Language recovery in massive hemispheric infarctions has not yet been described and little is known regarding the mechanisms of functional recovery from aphasia in patients with massive damage of the dominant hemisphere. The study of these patients presents a unique opportunity to study the mechanisms of recovery of the language systems in other less severe lesions. The aim of this study is to describe language impairment and functional outcome associated with nearly complete left hemispheric ischaemic stroke involving territories supplied by the middle and posterior cerebral arteries. This study characterized brain activation patterns using functional magnetic resonance imaging (fMRI) 10 months after a DH was performed in a patient with massive lesions in language areas. This information could prove relevant for both researchers of the neural mechanisms involved in aphasia recovery when most of the dominant hemisphere has been damaged and the clinician who must inform the patient's relatives. In the clinical scenario of malignant stroke, when the patient's will is not known, next-of-kin usually take the decision to proceed to surgery because the capability of these patients to understand and interact is severely impaired.

Report of a case

A 20-year old right-handed woman was admitted to Vall d'Hebron University Hospital in January 2007 because of

sudden onset of aphasia and hemiplegia. An initial computed tomography (CT) scan showed a low density area in the left MCA and left anterior cerebral artery (ACA) territories without midline shift. The patient had no risk factors except for oral contraceptive use. The National Institute of Health Stroke Scale (NIHSS) score was 21. The patient was transferred to the neurology department 7.5 hours after stroke onset. Forty-eight hours after stroke onset, her neurological status rapidly declined. A CT scan was repeated and disclosed an increased area of ischaemic tissue and cerebral oedema, causing a mass effect and a midline shift of 12 mm. The patient underwent urgent left frontal-temporo-parietal hemicraniectomy with duraplasty. Five weeks later, she underwent replacement of bone flap and 1 week after surgery she was discharged to an inpatient rehabilitation facility to start occupational, physical and speech therapies.

Ten months after stroke onset the patient was examined with standardized neuropsychological tests and an fMRI was performed to study the reorganization of speech comprehension. MRI showed lesions involving practically the entire left hemisphere and the posterior temporo-parietal regions of the right hemisphere (in the temporo-parietal junction) (Figure 1).

Neuropsychological assessment

The Boston Diagnostic Aphasia Exam (BDAE) and the Token Test were administered to assess the extent of language impairment (Table I). The patient showed non-fluent spontaneous speech restricted to stereotypic utterances.

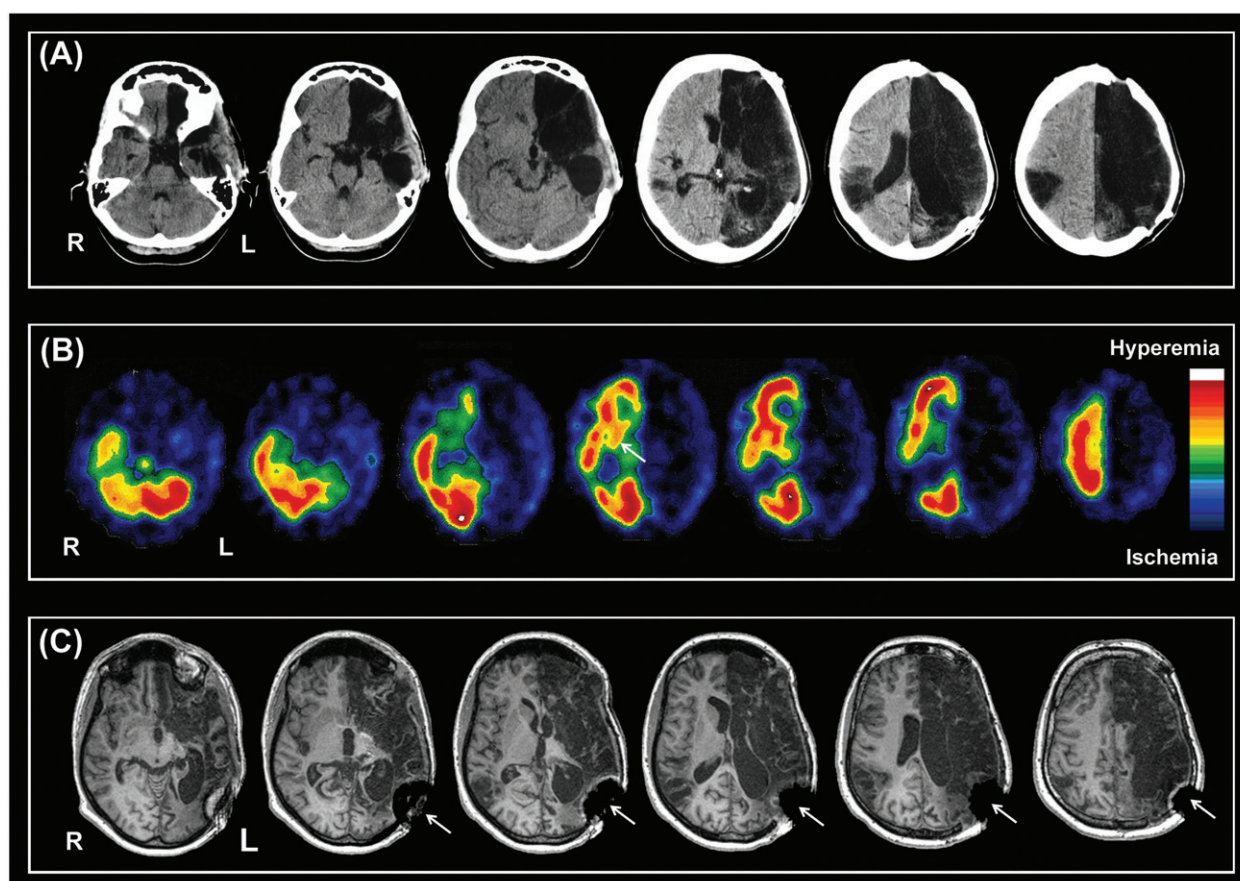


Figure 1. Neuroimaging studies (A: CT scan, B: Single-photon emission computed tomography (SPECT), C: MRI) performed 10 months after the stroke showing the extent of cerebral infarcts. Complete left anterior cerebral artery and middle cerebral artery territories were infarcted. The posterior temporo-parietal region of the right middle cerebral artery was also infarcted. R: Right hemisphere. L: Left hemisphere. Small arrows indicate MR artifact due to a metallic fixation implant.

She was unable to name any of the 60 visual pictures of the Boston Naming Test. Her auditory verbal comprehension was impaired for sequential commands. Even though the Token test score was 8, indicating severely impaired comprehension, she was surprisingly able to match spoken and written words with their corresponding drawings for nouns and verbs. Her repetition, oral reading and writing remained severely impaired. These results indicated global aphasia. The patient’s visuo-spatial and visuoconstructive functions were also impaired. Her performance on visual perceptual tasks was within the normal range. On examination, the patient was able to walk, go up and down stairs independently and perform simple tasks at home. She was categorized within the ‘lower severe disability’ range in the Extended Glasgow Outcome Scale and scored between 61–90 on the Barthel Index and 4 on the Modified Rankin Scale.

Table I. Neuropsychological test results.

Functions assessed	Test scores
Language	
Boston Diagnostic Aphasia Examination	
Boston naming test	0/60
Comprehension of Sequential Commands	6/15
Word-picture matching	8/10
Word repetition	0/10
Word reading	0/10
Word writing	4/15
Token Test	8/36
Visuo-spatial functions	
Judgement of Line Orientation	18/30
Visuo-constructive functions	
Rey Complex Figure Test (copy)	17/36
Visual perceptual functions	
Visual Form Discrimination Test (Benton)	12/16
Facial Recognition Test (Benton)	21/27

Functional magnetic resonance imaging

The patient underwent an fMRI test similar to that used by Fernández-Espejo et al. [11], including eight spoken narratives delivered in normal (making sense) and reversed (nonsense) speech, alternated with periods of silence. The fMRI dataset was acquired on a 3 T MRI scanner (Magnetom Trio Tim, Siemens Medical Systems, Germany) with the following parameters: TR (repetition time)=2000 ms; TE (echo time)=29 ms; percentage phase field of view=100; matrix size=128 × 128; slice thickness=3 mm; interslice gap=3.75 mm; flip angle=90°. This study also acquired a high-resolution 3D structural image with the following parameters: TR=2300 ms, TE=2.98 ms, TI (inversion time)=900; FOV (field of view)=100 × 100 cm; matrix size=256 × 256; flip angle=9°; slice thickness=1.

Data pre-processing and analysis was performed using SPM5 (Statistical Parametric Mapping, Wellcome Department of Cognitive Neurology, University College London, London, UK (<http://www.fil.ion.ucl.ac.uk/spm>) running in Matlab 6.5 (MathWorks, Natick, MA)). Cerebral response to speech was assessed by the contrast between narratives played normally and played in reverse. Figure 2 provides a visual summary of the cerebral regions showing significant activation in the contrast assessed statistical threshold of $p < 0.05$ corrected using the false discovery rate (FDR) procedure. This patient activated a network of posterior regions in the occipito-temporal and parietal areas, including the fusiform gyrus bilaterally, the right lingual gyrus, the right inferior occipital gyrus and the left precuneus and cingulated gyrus. In the right hemisphere, activations were observed in the posterior middle temporal gyrus and in a small area of the anterior part of the middle frontal gyrus (Table II).

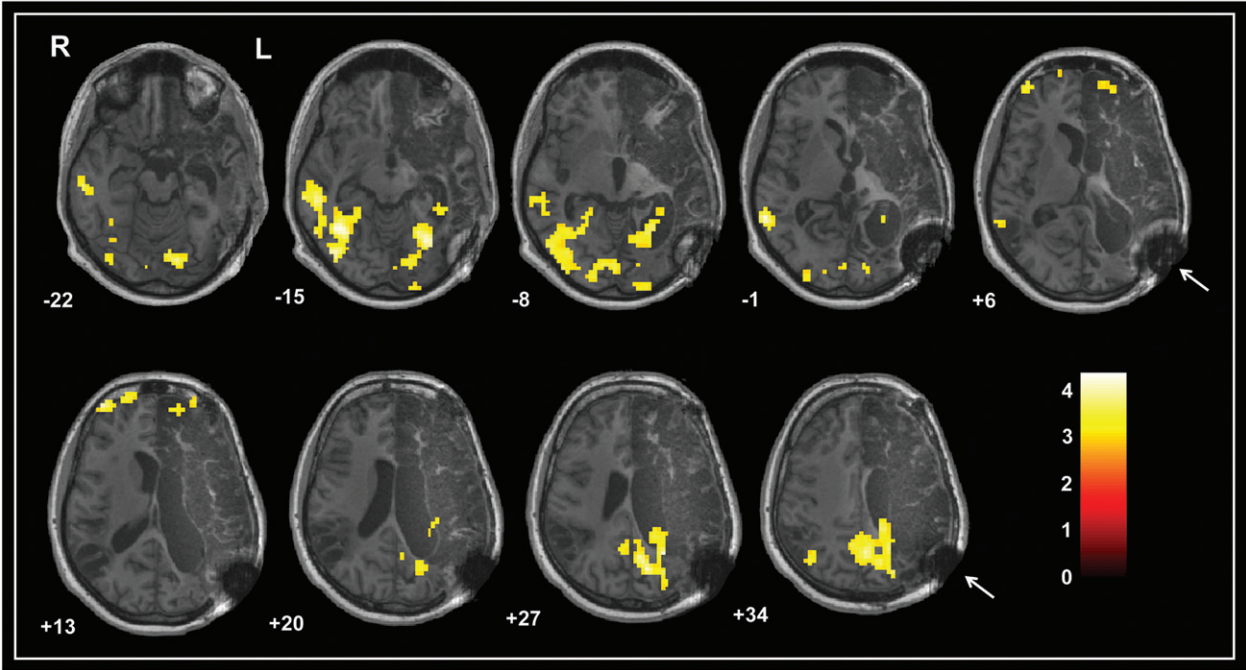


Figure 2. Axial section of images illustrating areas showing significant activation in the contrast between narratives played forward (intelligible speech) and backward (unintelligible speech). Results are displayed at an FDR (false discovery rate)-corrected $p < 0.05$. The colour bar represents the t scores. R: Right hemisphere. L: Left hemisphere. Small arrows indicate MR artifact due to a metallic fixation implant.

Table II. Areas of significant activation during speech perception.

Brain structure	BA	k	Co-ordinate			z-Value
			x	y	z	
Right hemisphere						
Lingual gyrus	17,18	77	3	−84	−6	4.27
Inferior occipital gyrus, Middle temporal gyrus, Fusiform gyrus	19, 21, 37	504	39	−57	−15	4.19
Middle frontal gyrus	10	58	42	57	9	4.15
Left hemisphere						
Precuneus, cingulated gyrus	7, 31	415	−9	−72	30	4.24
Fusiform gyrus, Left cerebellum	19	276	−27	−66	−15	4.12

Co-ordinate, z-value and *p*-value refer to the main peak of activation into the cluster; Co-ordinates are presented according to Montreal Neurological Institute. Results thresholded at *p* < 0.05 FDR (false discovery rate)-corrected; BA, Brodmann areas; k, cluster size.

Discussion

At present, there is Class I evidence to support aggressive treatment in patients with malignant cerebral infarctions, even those affected in the dominant hemisphere [3]. Moreover, some authors have demonstrated unexpectedly good functional results using surgical decompression (decompressive hemicraniectomy), especially in young people. This has been observed in motor function in particular. However, little is known about the pattern of functional reorganization of comprehension in patients recovering from massive cerebral infarction. To the authors’ knowledge, this is the first description of functional recovery in a patient with a left-sided ischaemic stroke treated with hemicraniectomy. Aphasic patients with brain damage to the left hemisphere may use two ways to cope with language impairment. Mechanisms of reorganization may use left hemisphere (LH) language areas spared by the infarction or recruit right hemisphere (RH) areas involved in speech [12–14].

This patient showed severe damage of all brain areas supporting language functions in the LH. Even so, she partially preserved the ability for semantic processing of auditory and visually presented words. fMRI showed clear activation in the superior and middle temporal gyrus of the right hemisphere, reflecting a redistribution of activity within contralateral regions. Some authors have reported that such reorganization occurs in a pre-existing network of RH regions known to have some innate capacity for auditory-word comprehension [14, 15].

A stronger activation pattern was observed in the posterior bilateral occipito-temporal cortex and medial parieto-occipital areas. The ventral temporal cortex and occipital regions are involved in visual imagery processes [16–21]. Strong interactions exist between language and visual imagery that allow easy transfer from one representation mode to the other. A mental image can easily be built from a verbal description or an oral description of a mental image can be given [20]. Büchel et al. [16] reported that the posterior basal temporal lobe regions (Brodmann area (BA) 37) have an important role in integrating inputs of different sensory modalities (visual, auditory and tactile) with linguistic knowledge. The preserved ability of this patient to match written and orally presented words with their corresponding pictures could be explained by the participation of these occipito-temporal areas. The ventral temporal cortex has been implicated in the storage of sensory representations of objects. These areas are

activated during the generation of visual images or during memory retrieval [18]. In this patient, the parahippocampal gyrus, a region that plays a role in encoding and storing memories of events, also showed strong activation [22].

In addition, significant activation was also seen in a medial parietal brain area, the precuneus, a region that has been implicated in retrieval of episodic memory during memory-related imagery [23]. This region is a key part of the neural substrate of visual imagery which occurs when ‘conscious’ memory recall processes take place. Furthermore, a small area of activation was found in the anterior part of the middle and superior frontal gyrus. The parietal and frontal regions form part of a network of working memory processes, mediating the retrieval of object representations from long-term memory, holding this representation in a working memory buffer through visual imagery and providing the attention required to generate these mental images [18, 24]. In view of these results, one can speculate that this patient might have been using visual imagery to support her understanding of sentences. It is important to point out that, although visual cueing has been considered to play a crucial role in improving verbal production and language comprehension in the rehabilitation of aphasia [25], the description of a single case report is limited because it cannot help in elucidating the role of visual cuing in language.

In conclusion, aggressive treatment of patients with malignant brain infarction is a life-saving procedure. In addition, the question of whether or not patients with stroke in the dominant hemisphere are neurologically devastated has to be reconsidered. When conducting this procedure in patients with dominant hemispheric stroke, unexpectedly good results may be found, including in language function. However, this single-case report does not allow one to conclude that this is the norm and not an exception. Additional fMRI studies of patients with massive left hemisphere damage are required to understand the neural mechanisms underlying recovery in patients with massive brain damage and aphasia.

Acknowledgements

This study was supported by the *Fondo de Investigaciones Sanitarias de la Seguridad Social* (FIS, 08/0480 given to Dr J. Sahuquillo). Bessy Benejam was awarded a predoctoral research grant from the *Institut Fundació de Recerca Vall d’Hebron*.

Brain Inj Downloaded from informahealthcare.com by University of Alaska Anchorage on 10/30/14
For personal use only.

Declaration of interest

The authors report no conflicts of interest. The authors alone are responsible for the content and writing of the paper.

References

- Simard JM, Sahuquillo J, Sheth KN, Kahle KT, Walcott BP. Managing malignant cerebral infarction. *Current Treatment Options in Neurology* 2011;13:217–229.
- Staykov D, Gupta R. Hemispherectomy in malignant middle cerebral artery infarction. *Stroke* 2011;42:513–516.
- Vahedi K, Hofmeijer J, Juettler E, Vicaut E, George B, Algra A, Amelink GJ, Schmiedeck P, Schwab S, Bousser MG, et al. Early decompressive surgery in malignant infarction of the middle cerebral artery: A pooled analysis of three randomised controlled trials. *Lancet Neurology* 2007;6:215–222.
- Rahme R, Zuccarello M, Kleindorfer D, Adeoye OM, Ringer AJ. Decompressive hemicraniectomy for malignant middle cerebral artery territory infarction: Is life worth living? *Journal of Neurosurgery* 2012;117:749–754.
- Benejam B, Sahuquillo J, Poca MA, Frasccheri L, Solana E, Delgado P, Junqué C. Quality of life and neurobehavioral changes in survivors of malignant middle cerebral artery infarction. *Journal of Neurology* 2009;256:1126–1133.
- Foerch C, Lang JM, Krause J, Raabe A, Sitzer M, Seifert V, Steinmetz H, Kessler KR. Functional impairment, disability, and quality of life outcome after decompressive hemicraniectomy in malignant middle cerebral artery infarction. *Journal of Neurosurgery* 2004;101:248–254.
- Leonhardt G, Wilhelm H, Doerfler A, Ehrenfeld CE, Schoch B, Rauhut F, Hufnagel A, Diener HC. Clinical outcome and neuropsychological deficits after right decompressive hemicraniectomy in MCA infarction. *Journal of Neurology* 2002;249:1433–1440.
- Kastrau F, Wolter M, Huber W, Block F. Recovery from aphasia after hemicraniectomy for infarction of the speech-dominant hemisphere. *Stroke* 2005;36:825–829.
- Warburton E, Price CJ, Swinburn K, Wise RJ. Mechanisms of recovery from aphasia: Evidence from positron emission tomography studies. *Journal of Neurology, Neurosurgery & Psychiatry* 1999;66:155–161.
- Crinion JT, Leff AP. Recovery and treatment of aphasia after stroke: Functional imaging studies. *Current Opinion in Neurology* 2007;20:667–673.
- Fernandez-Espejo D, Junque C, Vendrell P, Bernabeu M, Roig T, Bargallo N, Mercader JM. Cerebral response to speech in vegetative and minimally conscious states after traumatic brain injury. *Brain Injury* 2008;22:882–890.
- Mimura M, Kato M, Kato M, Sano Y, Kojima T, Naeser M, Kashima H. Prospective and retrospective studies of recovery in aphasia. Changes in cerebral blood flow and language functions. *Brain* 1998;121:2083–2094.
- Thulborn KR, Carpenter PA, Just MA. Plasticity of language-related brain function during recovery from stroke. *Stroke* 1999;30:749–754.
- Weiller C, Isensee C, Rijntjes M, Huber W, Muller S, Bier D, Dutschka K, Woods RP, Noth J, Diener HC. Recovery from Wernicke's aphasia: A positron emission tomographic study. *Annals of Neurology* 1995;37:723–732.
- Gold BT, Kertesz A. Right hemisphere semantic processing of visual words in an aphasic patient: An fMRI study. *Brain and Language* 2000;73:456–465.
- Buchel C, Price C, Friston K. A multimodal language region in the ventral visual pathway. *Nature* 1998;394:274–277.
- D'Esposito M, Detre JA, Aguirre GK, Stallcup M, Alsop DC, Tippet LJ, Farah MJ. A functional MRI study of mental image generation. *Neuropsychologia* 1997;35:725–730.
- Ishai A, Ungerleider LG, Haxby JV. Distributed neural systems for the generation of visual images. *Neuron* 2000;28:979–990.
- Kosslyn SM, Thompson WL, Kim IJ, Alpert NM. Topographical representations of mental images in primary visual cortex. *Nature* 1995;378:496–498.
- Mellet E, Tzourio N, Denis M, Mazoyer B. Cortical anatomy of mental imagery of concrete nouns based on their dictionary definition. *Neuroreport* 1998;9:803–808.
- Ungerleider LG, Mishkin M. Two cortical visual systems. In: Ingle D, Goodale M, Mansfield R, editors. *Analysis of visual behaviour*. Cambridge: MIT Press; 1982. pp 549–586.
- Wagner AD, Schacter DL, Rotte M, Koutstaal W, Maril A, Dale AM, Rosen BR, Buckner RL. Building memories: Remembering and forgetting of verbal experiences as predicted by brain activity. *Science* 1998;281:1188–1191.
- Fletcher PC, Frith CD, Baker SC, Shallice T, Frackowiak RS, Dolan RJ. The mind's eye—precuneus activation in memory-related imagery. *Neuroimage* 1995;2:195–200.
- Haxby JV, Petit L, Ungerleider LG, Courtney SM. Distinguishing the functional roles of multiple regions in distributed neural systems for visual working memory. *Neuroimage* 2000;11:145–156.
- Choe Y, Stanton K. The effect of visual cues provided by computerised aphasia treatment. *Aphasiology* 2011;25:983–997.