

# Reversible Cerebral Vasoconstriction Syndrome with Multivessel Cervical Artery Dissections and a Double Aortic Arch

Amre Nouh, MD,\* Sean Ruland, DO,\* Michael J. Schneck, MD,\*†  
David Pasquale, MD,†‡ and José Biller, MD\*†

---

Reversible cerebral vasoconstriction syndrome (RCVS) has been associated with exposure to vasoactive substances and few reports with cervical arterial dissections (CADs). We evaluated a 32-year-old woman with history of depression, migraines without aura, and cannabis use who presented with a thunderclap headache unresponsive to triptans. She was found to have bilateral occipital infarcts, bilateral extracranial vertebral artery dissections, bilateral internal carotid artery dissecting aneurysms, and extensive distal multifocal segmental narrowing of the anterior and posterior intracranial circulation with a “sausage on a string-like appearance” suggestive of RCVS. Subsequently, she was found to have a distal thrombus of the basilar artery, was anticoagulated, and discharged home with no residual deficits. We highlight the potential association of CADs and RCVS. The association of RCVS and a double aortic arch has not been previously reported. **Key Words:** Reversible cerebral vasoconstriction syndrome—cervical artery dissections—double aortic arch—cannabis—triptans.

© 2014 by National Stroke Association

---

## Case Report

A 32-year-old woman with migraines without aura and depression presented to an emergency department with a thunderclap headache unresponsive to triptans. She

was on paroxetine and smoked cannabis before onset of headache. After a severe bout of coughing, she experienced severe persistent bilateral posterior neck pain.

Neurologic examination was initially unremarkable. She was discharged home after receiving analgesics. A week later, she returned with unrelenting headaches and posterior neck pain. Examination showed a right inferior homonymous quadrantanopsia. Magnetic resonance imaging demonstrated restricted diffusion in both occipital lobes. Magnetic resonance angiography and subsequent catheter cerebral angiography of the head and neck are shown in [Figure 1](#), A,B, respectively.

Cerebrospinal fluid analysis showed a white blood cell count of 2 cells/ $\mu$ L, protein of 36 mg/dL, and a glucose of 58 mg/dL. Serum inflammatory markers and hypercoagulable panel were unremarkable. Before transfer, she received prednisone, verapamil, and aspirin. On arrival to our hospital, steroids were discontinued and verapamil switched to nimodipine. Follow-up catheter cerebral

---

From the \*Department of Neurology, Loyola University Chicago, Stritch School of Medicine, Maywood, Illinois; †Department of Neurosurgery, Loyola University Chicago, Stritch School of Medicine, Maywood, Illinois; and ‡Division of Neuroradiology, Department of Radiology, Loyola University Chicago, Stritch School of Medicine, Maywood, Illinois.

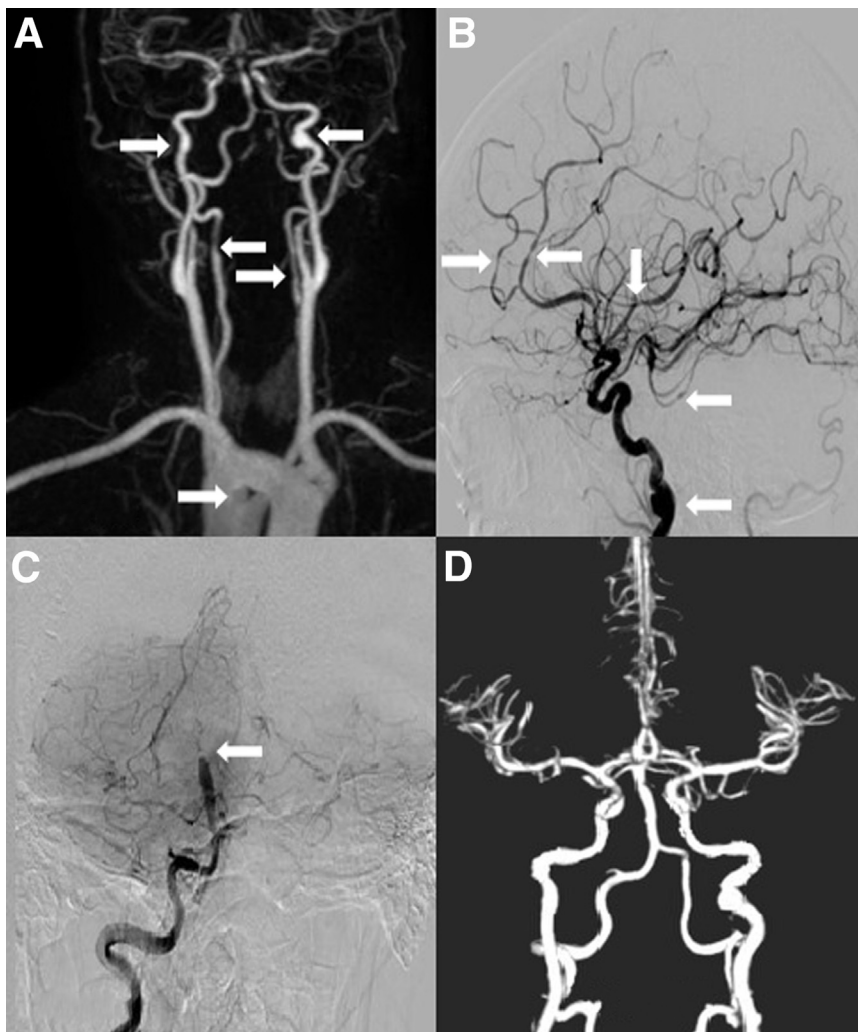
Received August 6, 2013; revision received August 20, 2013; accepted August 21, 2013.

Address correspondence to Amre Nouh, MD, Department of Neurology, Loyola University Chicago, Stritch School of Medicine, 2160 S 1st Ave, Bldg 105, Room 2700, Maywood, IL 60153. E-mail: [amnouh@lumc.edu](mailto:amnouh@lumc.edu).

1052-3057/\$ - see front matter

© 2014 by National Stroke Association

<http://dx.doi.org/10.1016/j.jstrokecerebrovasdis.2013.08.013>



**Figure 1.** (A) Magnetic resonance angiography demonstrating saccular dilatation of the distal cervical segment of the left internal carotid artery (ICA) and a smaller fusiform aneurysmal dilation of the right ICA consistent with dissecting aneurysms (top arrows), irregular contour and narrowing of the left and right vertebral arteries consistent with bilateral vertebral artery dissections (middle arrows), and a double aortic arch (bottom arrow). (B) Catheter cerebral angiogram with “sausage on a string appearance” involving the anterior and posterior circulation (top and middle arrows) and an ICA dissecting aneurysm (bottom arrow). (C) Distal basilar artery thrombus (arrow). (D) Computed tomography angiogram with decrease in intracranial vasoconstrictive changes and restoration of anterograde flow of the basilar artery.

angiogram showed multivessel cervical arterial dissections (CADs), multifocal intracranial arterial vasoconstriction, and a near-occlusive distal basilar artery thrombus (Fig 1, C). She received intravenous unfractionated heparin followed by warfarin bridging.

Follow-up computed tomography angiography obtained 1 week later demonstrated improvement of the intracranial vasoconstriction and near resolution of the basilar thrombus (Fig 1, D). The appearance of the CADs was unchanged. She was discharged home in stable condition on warfarin.

## Discussion

Reversible cerebral vasoconstriction syndrome (RCVS) is characterized by thunderclap headache with or without focal neurologic deficits and angiographic findings of reversible, intracranial, multifocal segmental vasoconstriction usually within 12 weeks from clinical onset.<sup>1</sup> Differentiating RCVS from primary angiitis of the central nervous system (PACNS) can be challenging. Distinguishing features of RCVS are thunderclap headache at presentation, watershed

pattern of infarctions, association with cortical subarachnoid hemorrhages, lobar hemorrhages, or reversible edema.<sup>1,2</sup> Conversely, PACNS often has an insidious onset, scattered small vessel distribution infarct pattern, and is seldom accompanied with subarachnoid or lobar hemorrhages. Angiography is frequently normal in PACNS, whereas by definition should be abnormal to establish a diagnosis of RCVS.<sup>3</sup> Moreover, RCVS has a monophasic course with usually better prognosis than PACNS.<sup>4</sup> Cannabis use has been associated with RCVS alone and in combination with other vasoactive drugs.<sup>5</sup> Intracerebral hemorrhages have been associated with RCVS. Female gender and history of migraines have been reported to be independent risk factors for hemorrhage with RCVS.<sup>6</sup>

CADs can occur with minor trauma, including severe coughing.<sup>7</sup> Patients with underlying collagen vascular disease or fibromuscular dysplasia (FMD) may be at higher risk for CADs.<sup>7</sup>

Our patient reported a severe bout of coughing followed by neck pain. This event could have triggered the CADs. The angiographic appearance of her cervical vessels did not suggest FMD. However, renal artery imaging

was not performed, and we are unable to fully exclude the possibility of pre-existing FMD.

Historically, isolated cases of RCVS associated with CADs have been reported. However, a more recent series of patients with CADs and RCVS identified 20 cases. Only one of those patients had 4 vessel dissections similar to our patient.<sup>8</sup> Furthermore, postpartum CADs have been reported to coexist more commonly with RCVS.<sup>9</sup> However, our patient was neither pregnant nor postpartum.

Calcium channel blockers, namely nimodipine and verapamil, have been the mainstay of RCVS treatment. Magnesium sulfate has also been used, and in severe cases, intra-arterial administration of milrinone, nimodipine, papaverine, epoprostenol, and/or balloon angioplasty have been proposed.<sup>3</sup> The role of corticosteroids is unclear, although worse outcomes have been reported with its use.<sup>10</sup>

The optimal antithrombotic therapy for CADs is not yet established. An ongoing study evaluating risks and benefits of antithrombotics in this setting is underway.<sup>11</sup> Despite the known association between RCVS and intracerebral hemorrhage, our patient was anticoagulated because of the presence of thrombus within the distal basilar artery.

## Conclusion

More cases of RCVS with CADs are being identified. Our case further suggests that the coexistence of these findings are unlikely coincidental. The double aortic arch was an intriguing finding; however, its significance is unknown. Further research is required to evaluate the

pathophysiological association between RCVS and CADs.

## References

1. Calabrese LH, Dodick DW, Schwedt TJ, et al. Narrative review: reversible cerebral vasoconstriction syndromes. *Ann Intern Med* 2007;146:34-44.
2. Singhal AB. Cerebral vasoconstriction syndromes. *Top Stroke Rehabil* 2004;11:1-6.
3. Ducros A. Reversible cerebral vasoconstriction syndrome. *Lancet Neurol* 2012;11:906-917.
4. Hajj-Ali RA, Singhal AB, Benseler S. Primary angiitis of the CNS. *Lancet Neurol* 2011;10:561-572.
5. Ducros A, Boukobza M, Porcher R, et al. The clinical and radiological spectrum of reversible cerebral vasoconstriction syndrome. A prospective series of 67 patients. *Brain* 2007;130(Pt 12):3091-3101.
6. Ducros A, Fiedler U, Porcher R. Hemorrhagic manifestations of reversible cerebral vasoconstriction syndrome: frequency, features, and risk factors. *Stroke* 2010;41:2505-2511.
7. Debette S, Leys D. Cervical-artery dissections: predisposing factors, diagnosis, and outcome. *Lancet Neurol* 2009;8:668-678.
8. Mawet J, Boukobza M, Franc J. Reversible cerebral vasoconstriction syndrome and cervical artery dissection in 20 patients. *Neurology* 2013;81:821-824.
9. Arnold M, Camus-Jacqmin M, Stapf C, et al. Postpartum cervicocephalic artery dissection. *Stroke* 2008;39:2377-2379.
10. Singhal AB, Hajj-Ali RA, Topcuoglu MA, et al. Reversible cerebral vasoconstriction syndromes: analysis of 139 cases. *Arch Neurol* 2011;68:1005-1012.
11. Cervical Artery Dissection in Stroke Study (CADISS) feasibility phase, Professor Hugh Markus, St George's Healthcare NHS Trust. Available at: <http://www.sgul.ac.uk/research/centres/sd/ongoing-projects/cadiss>.