

An internal carotid artery aneurysm presenting with dysarthria

PT Davey, I Rychlik, M O'Donnell, R Baker, I Rennie

Belfast Health and Social Care Trust, UK

ABSTRACT

A 72-year-old woman presented to her general practitioner with a 4-week history of right neck swelling. Clinical examination elicited a pulsatile mass consistent with a carotid artery aneurysm. Five days later the patient noticed her tongue movements had become awkward with associated dysarthria. Computed tomography confirmed a 4cm internal carotid artery aneurysm arising just distally to the carotid bifurcation. She proceeded to transfemoral diagnostic carotid angiography. Balloon occlusion of the right internal carotid artery origin was performed for a ten-minute period without any neurological deficit.

The decision was taken to proceed to surgical ligation of the origin of the internal carotid artery. Her symptoms of dysarthria have resolved.

KEYWORDS

Internal carotid artery aneurysm – Dysarthria – Endovascular

Accepted 28 November 2012; published online XXX

CORRESPONDENCE TO

Phil Davey, 34 The Boulevard, Belfast BT7 3LN, UK
T: +44 (0)7764 751 626; E: phildavey@doctors.net.uk

Case history

A 72-year-old woman presented to her general practitioner with a 4-week history of right neck swelling. Clinical examination elicited a pulsatile mass consistent with a carotid artery aneurysm. She had no cardiovascular risk factors and was a non-smoker. There was no history of trauma or previous head and neck surgery. Five days later, the patient noticed her tongue movements had become awkward with associated dysarthria.

At the vascular outpatient clinic, a 4cm non-tender expansile swelling was identified in the right anterior neck triangle (Fig 1). No tongue wasting or deviation was noted. Duplex ultrasonography confirmed a 4cm carotid artery aneurysm while urgent computed tomography (CT) confirmed a 4cm internal carotid artery (ICA) aneurysm arising just distally to the carotid bifurcation with extension to the angle of the mandible (Fig 2). The distal ICA remained patent.

Following discussion at the vascular multidisciplinary meeting, the patient proceeded to transfemoral diagnostic carotid angiography with electroencephalography monitoring under local anaesthesia. Antiplatelet loading with two doses each of 300mg of aspirin and 300mg of clopidogrel was completed. The origin of the ICA aneurysm was confirmed just distally to the carotid bifurcation with normal filling of the right middle cerebral artery (Fig 3). Owing to the diameter differential between the proximal aneurysmal portion and the small calibre distal ICA, cannulation of the distal segment was not attempted. Balloon occlusion of the right ICA origin was performed for a ten-minute pe-

riod without any neurological deficit. Symmetrical flow was demonstrated in both cerebral hemispheres via left carotid angiography. It was felt that a simple destructive procedure was safer than a reconstructive procedure.

The decision was taken to proceed to surgical ligation of the origin of the ICA after control with vascular sloops followed by double ligation with Prolene® (Ethicon, Somerville, NJ, US) sutures (Fig 4). The procedure was performed seven days later without complication. The patient commented that her tongue movements and dysarthria had already appeared to improve on day 2 following surgery. She was discharged home on warfarin therapy for three months. Although the aneurysm was not explored, she has been advised that the swelling may still persist for a few weeks prior to subsequent reduction. At the week 6 outpatient review, she remained well and the swelling had reduced. Her symptoms of dysarthria have resolved. Follow-up carotid duplex ultrasonography demonstrated no flow in the aneurysm sac.

Discussion

Carotid artery aneurysms can be divided into those that are intracranial and extracranial. Extracranial carotid artery aneurysms are rare, with an incidence of 0.5–1% accounting for less than 1% of all peripheral artery aneurysms.^{1,2} Bilateral carotid artery aneurysms may occur in 21% of cases.³ Atherosclerosis is believed to be the primary aetiologic factor² with rarer causes attributed to arterial dysplasia, dissection,⁴ trauma, connective tissue disorders⁵ and mycotic

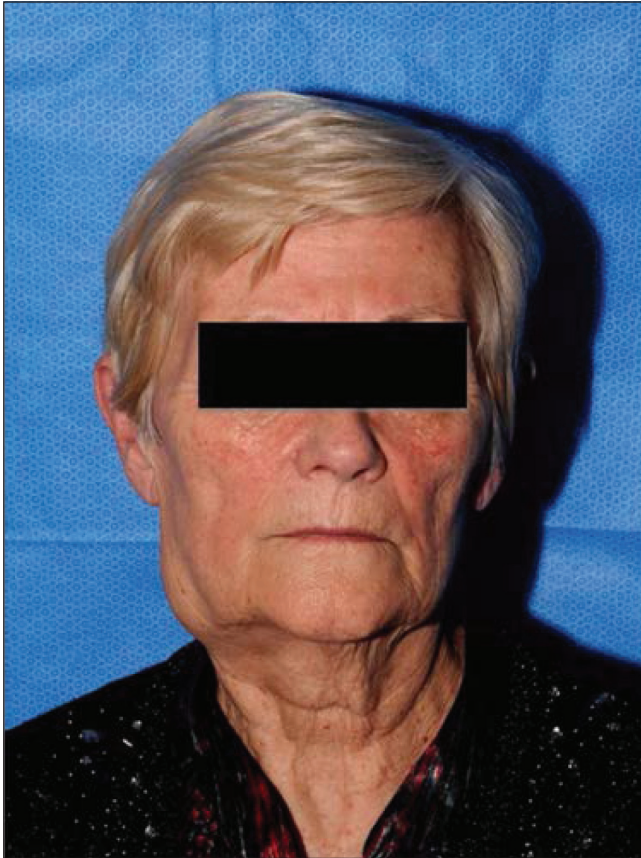

Figure 1 Patient with large pulsatile swelling in right side of neck

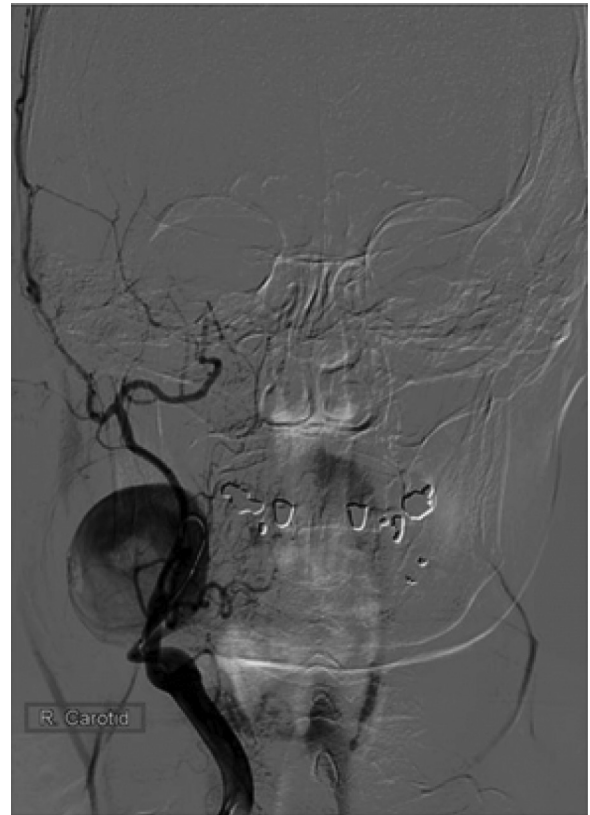


Figure 3 Anteroposterior view angiography demonstrating filling of the right internal carotid artery aneurysm

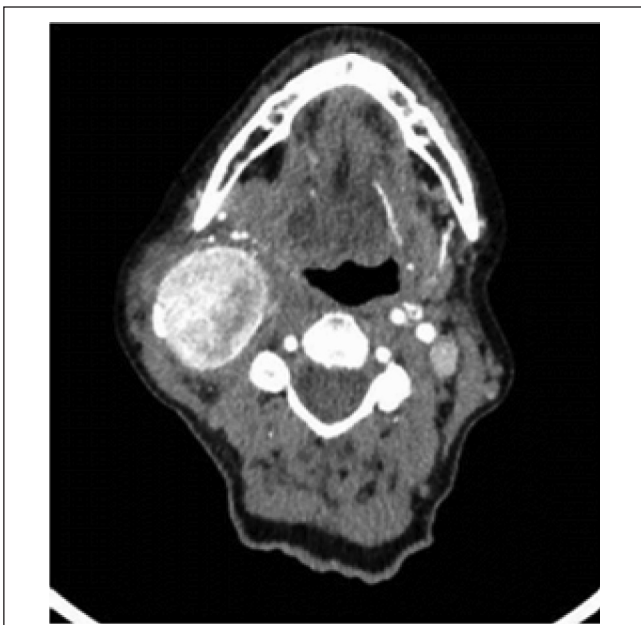


Figure 2 Axial contrast enhanced computed tomography demonstrating the right internal carotid artery aneurysm

infection.⁶ In our case, it was felt that the aetiology of the aneurysm was most likely related to a previously undiagnosed carotid artery dissection.

Clinical presentation ranges from asymptomatic swelling to dysarthria, hoarseness, pain, syncope or transient ischaemic attacks from dislodged thrombi.⁷ The natural progression of extracranial carotid artery aneurysms appears to be benign; the majority remain static or decrease in size. In our case, intervention was required because of rapid progression of neurological symptomatology while its 4cm size increased the risk of both thromboembolic sequelae as well as rupture. Following initial carotid duplex ultrasonography, cross-sectional imaging with both CT and magnetic resonance angiography is warranted prior to intervention. Although both modalities remain important for patient surveillance, Djouhri *et al* described no advantage of one cross-sectional technique over the other.⁸

Since initial carotid artery ligation for aneurysmal disease descriptions by Cooper in 1808,⁹ current surgical modalities now include resection with end-to-end anastomosis if feasible, replacement or intrapositional grafting using either autologous vein graft or synthetic grafts and patch angioplasty. However, primary ligation may still be the most appropriate option, especially in ruptured cases. Conven-

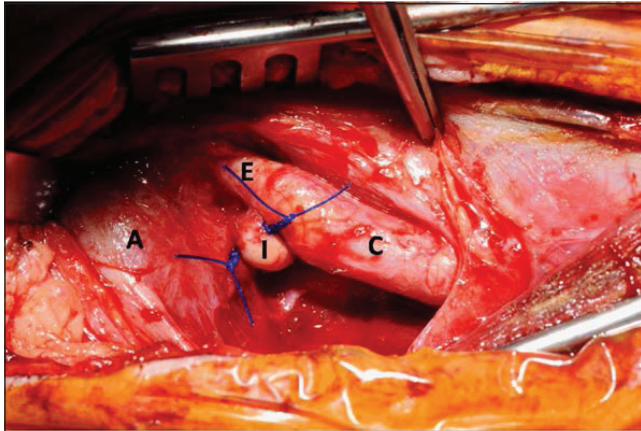


Figure 4 Ligated proximal internal carotid artery (I) with non-explored aneurysm distally (A) and normal common (C) and external carotid arteries (E)

tional surgical treatment confers a 0.9% stroke risk (with a higher risk following primary ligation) while cranial nerve deficits have also been reported in up to 44% of cases.^{5,10}

Endovascular intervention has reported success rates of 92.8% in early case series with estimated stroke and cranial nerve injury rates of 1.8% and 0.5% respectively.¹⁰ Late complications include thrombosis and occlusion. Postoperative anticoagulation following ligation remains unclear following surgical ligation. Warfarin therapy was commenced for three months in our patient to minimise the risk of distal clot propagation through the ICA.

Conclusions

Conservative management of extracranial carotid artery aneurysms is acceptable in certain cases with the best medical therapy including antiplatelet and lipid lowering therapy.¹¹ Although endovascular or conventional surgery is warranted in symptomatic patients, careful multidisciplinary planning is always required, particularly in cases where aneurysmal morphology suggests difficult distal anatomy, where conventional surgery would be more advantageous.

References

1. Srivastava SD, Eagleton MJ, O'Hara P *et al*. Surgical repair of carotid artery aneurysms: a 10-year, single-center experience. *Ann Vasc Surg* 2010; **24**: 100–105.
2. McCollum CH, Wheeler WG, Noon GP, DeBakey ME. Aneurysms of the extracranial carotid artery. Twenty-one years' experience. *Am J Surg* 1979; **137**: 196–200.
3. Lotina S, Davidović L, Kostić D *et al*. Aneurysms of the carotid arteries. *Srp Arh Celok Lek* 1997; **125**: 141–153.
4. Rao AS, Makaroun MS, Marone LK *et al*. Long-term outcomes of internal carotid artery dissection. *J Vasc Surg* 2011; **54**: 370–374.
5. El-Sabrou R, Cooley DA. Extracranial carotid artery aneurysms: Texas Heart Institute experience. *J Vasc Surg* 2000; **31**: 702–712.
6. O'Connell JB, Darcy S, Reil T. Extracranial internal carotid artery mycotic aneurysm: case report and review. *Vasc Endovascular Surg* 2009; **43**: 410–415.
7. Sood S, Timothy J, Anthony R *et al*. Extracranial internal carotid artery pseudoaneurysm. *Am J Otolaryngol* 2000; **21**: 259–262.
8. Djouhri H, Guillon B, Brunereau L *et al*. MR angiography for the long-term follow-up of dissecting aneurysms of the extracranial internal carotid artery. *Am J Roentgenol* 2000; **174**: 1,137–1,140.
9. Cooper A. Account of the first successful operation performed on the common carotid artery for aneurysm in the year 1808 with the postmortem examination in 1821. *Guy's Hosp Rep* 1836; **1**: 53–59.
10. Li Z, Chang G, Yao C *et al*. Endovascular stenting of extracranial carotid artery aneurysm: a systematic review. *Eur J Vasc Endovasc Surg* 2011; **42**: 419–426.
11. Guillon B, Brunereau L, Biousse V *et al*. Long-term follow-up of aneurysms developed during extracranial internal carotid artery dissection. *Neurology* 1999; **53**: 117–122.