

# The coexistence of pleomorphic xanthoastrocytoma and arteriovenous malformation. A case report

Ewa Nagańska<sup>1</sup>, Ewa Matyja<sup>1</sup>, Emanuela Pucko<sup>1</sup>, Mirosław Ząbek<sup>2</sup>

<sup>1</sup>Department of Experimental and Clinical Neuropathology, M. Mossakowski Medical Research Centre, Polish Academy of Sciences,

<sup>2</sup>Department of Neurosurgery, Postgraduate Medical Centre, Bródno Mazovia Hospital, Warsaw, Poland

*Folia Neuropathol* 2013; 51 (3): 269-274

DOI: 10.5114/fn.2013.37712

## Abstract

*Pleomorphic xanthoastrocytoma (PXA) is a rare, low-grade astrocytic tumour corresponding to WHO grade II that is usually diagnosed in adolescents and young adults with epileptic seizures. Pleomorphic xanthoastrocytoma typically appears as a superficial, often cystic mass lesion predominantly affecting the temporal lobe. Cases with typical pathology and total tumour excision have a favourable prognosis. Occasionally, the tumour reveals anaplastic features and behaves more aggressively due to local recurrences or subarachnoid spread. The treatment of PXA includes gross total resection followed by neuroradiological monitoring.*

*The association between vascular malformations and cerebral gliomas is rarely encountered, especially if both such lesions occur as separate parts of the same tumour. The vascular pathology of such changes most often refers to arteriovenous malformation (AVM), less frequently – cavernous angioma. The coexistence of PXA and AVM is extremely rare, especially when dealing with two distinct patterns found within the same tumour mass.*

*We present a 36-year-old woman with tumour of parasagittal localization in the right occipital lobe that was composed of two different and clearly demarcated components: PXA and vascular lesion of AVM morphology. The pathogenesis of such coexistence remains still unclear.*

**Key words:** pleomorphic xanthoastrocytoma, arteriovenous malformation, angioglioma, coexistence.

## Introduction

The association between vascular malformations and cerebral gliomas is unusual, especially if both such lesions occur separately. Most frequently the lesion consists of mixed elements of glial and vascular origin and is determined as angiogliomas [13,19,25,30,41]. The coexistence of vascular malformation with PXA is extremely rare, especially in the context of these two patterns occurring within the same tumour mass. The particular pattern of PXA with angiogliomatous

features has been reported [22] but only one case report refers to the true coincidence of PXA and AVM [28]. We present a 36-year-old woman with PXA of parasagittal localization in the right occipital lobe, which was accompanied by vascular changes fulfilling the morphological criteria of AVM. The extremely rare coexistence of pleomorphic xanthoastrocytoma and arteriovenous malformation (AVM) seems to be of very interest, especially when both such lesions occur as separate parts of one tumour.

## Communicating author:

Ewa Matyja, MD, PhD, Department of Clinical and Experimental Neuropathology, M. Mossakowski Medical Research Centre, Polish Academy of Sciences, 5 Pawińskiego St., 02-106 Warsaw, Poland, e-mail: ematyja@imdik.pan.pl

## Case report

A 36-year-old woman was admitted to the Neurosurgical Department. She had been suffering from headaches, dizziness and vertigo for two years. In neurological examination, left hemianopsia was detected. Magnetic resonance of the brain showed a tumour mass of  $3.5 \times 3.0 \times 2.5$  cm, which was partially solid and partially cystic, localized parasagittally in the front of the right occipital lobe, with no features of oedema and mass effect (Figs. 1A, B). The contrast enhancement in the solid part of the tumour was detected. The solid tumour zone touched closely the cerebral falx. The patient underwent right craniotomy and a gross total resection of the lesion was achieved. The postoperative course was uneventful.

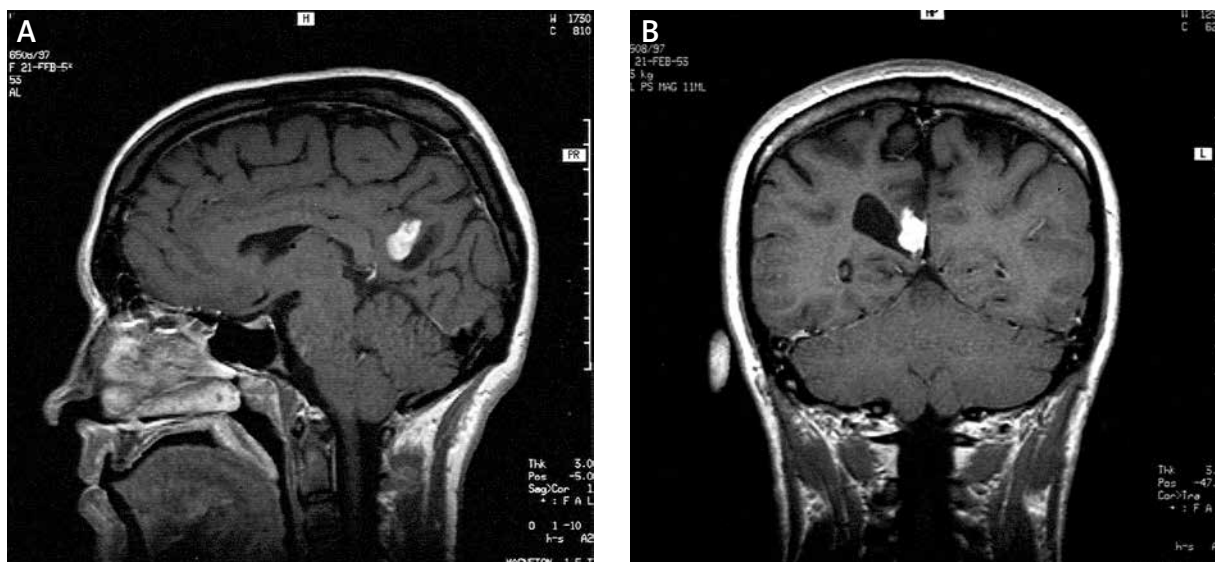
## Material and methods

The resected tissue was fixed in 10% formalin, embedded in paraffin and stained with haematoxylin-eosin (H&E) and Gomori's method. Immunohistochemical studies were performed on paraffin-embedded specimens according to the labelled avidin-biotin complex method (ABC) with DAB as chromogen, using antibodies against glial fibrillary acidic protein (GFAP), synaptophysin and MIB-1 antigen (all antibodies from Dako).

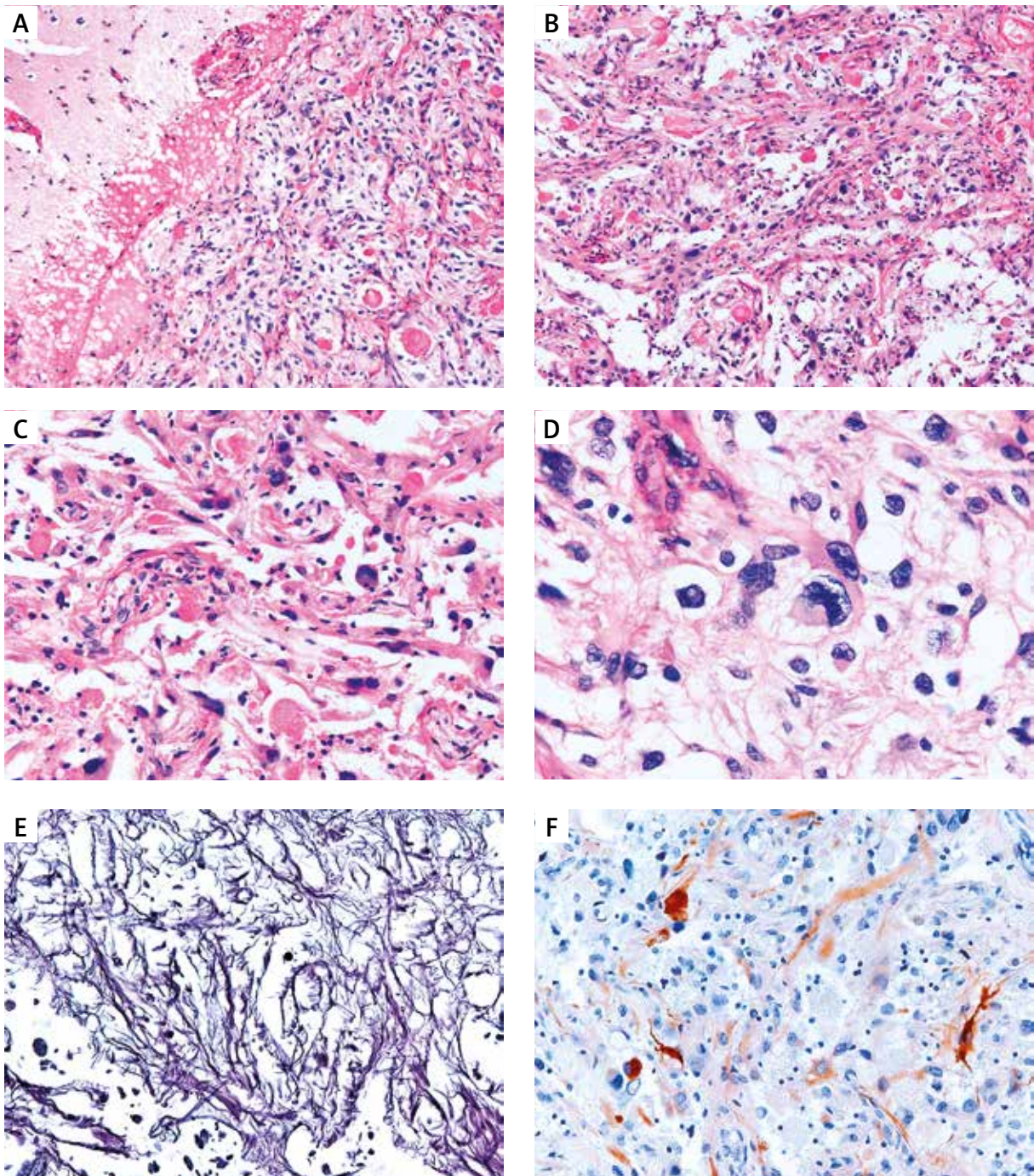
## Neuropathological examination

The surgical specimens consisted of two parts of different histopathological pattern. The neoplastic infiltration was seen in the superficial layers of the cerebral cortex with massive involvement of the leptomeninges (Fig. 2A). The main solid tumour mass, developing in the superficial cortex, showed typical PXA morphology with a moderate cellular polymorphism and varying degree of cytoplasmic lipidization (Figs. 2B-D). The eosinophilic granular bodies and perivascular lymphocytes could be occasionally seen. Focally, the elongated cells exhibited fascicular architecture. The dense reticulin fibers investing the small clusters of neoplastic cells predominated in the superficial part of the tumour (Fig. 2E). The subset of tumour cells stained positively for glial fibrillary acidic protein (GFAP), however the immunoreactivity was rather patchy and weak (Fig. 2F). Individual pleomorphic cells were immunopositive for synaptophysin. MIB-1 labelling index was low, up to 2%.

In the superficial part of the tumour and in the subarachnoid space, a number of abnormal blood vessels with various degree of hyalinization was seen (Fig. 3A). The vascular changes included abnormal, enlarged, often irregular vessels with asymmetrically thickened walls (Figs. 3B, C). The lesion exhibited morphology of arteriovenous malformation and

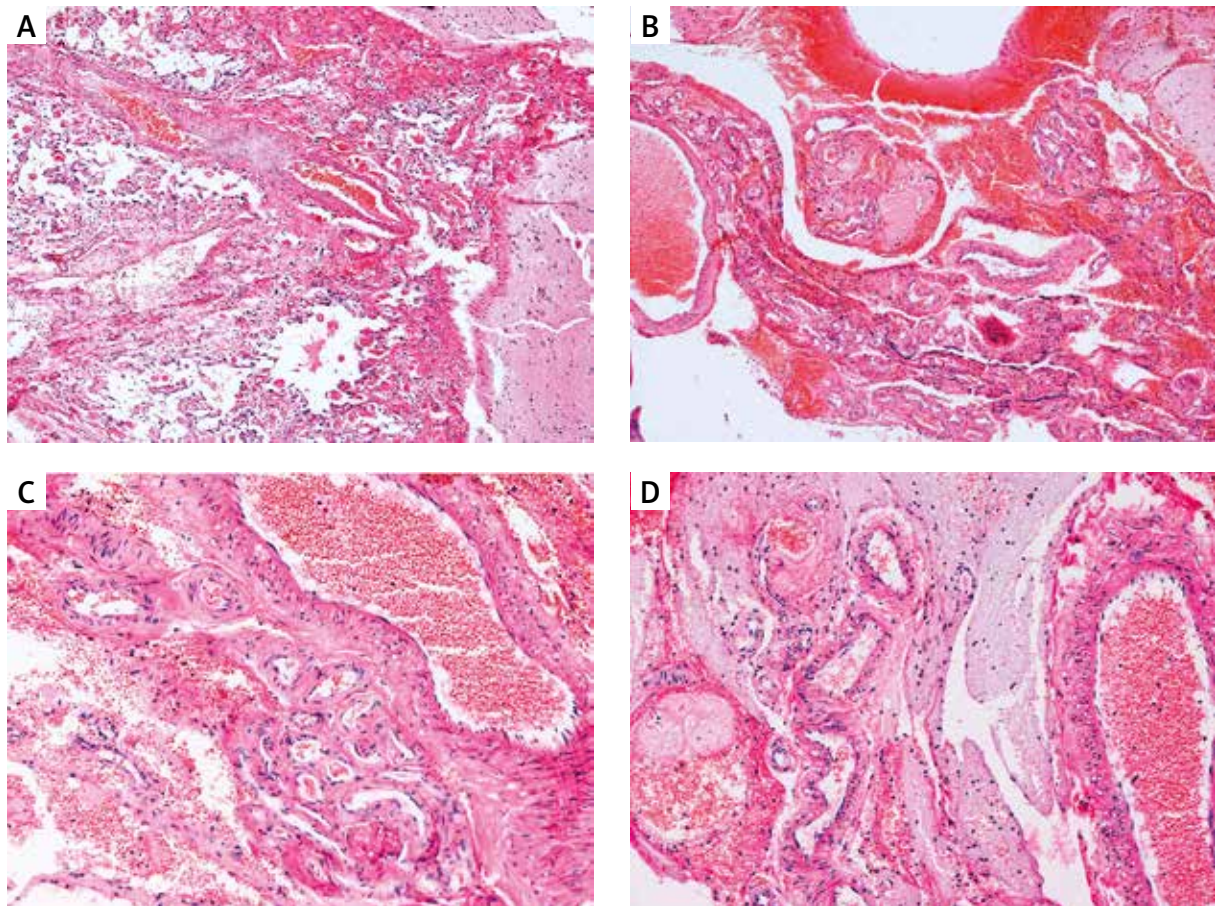


**Fig. 1.** Magnetic resonance of the brain. **A)** Sagittal T1-weighted scan. Partially cystic tumour mass localized parasagittally in the right occipital lobe with no features of mass effect. **B)** Coronal T1-weighted scan. The solid tumour part touching closely the cerebral falx.



**Fig. 2.** Histopathology of PXA. **A)** Neoplastic infiltration in the superficial layer of the cerebral cortex and leptomeninges. H&E. **B)** Typical PXA morphology with a moderate cellular polymorphism. H&E. **C)** Neoplastic tissue with numerous eosinophilic granular bodies. H&E. **D)** Marked cellular pleomorphism with a varying degree of cytoplasmic lipidization. H&E. **E)** Dense reticulin fibers investing the clusters of neoplastic cells. Gomori's method. **F)** Patchy immunoreactivity of tumour cells for GFAP. Original magnification A, B, E –  $\times 100$ , C, F –  $\times 200$ , D –  $\times 400$ .





**Fig. 3.** Vascular pathology of AVM features. **A)** Vascular changes in the superficial part of the tumour and subarachnoid space. H&E. **B, C)** Lesion consisting of arteries and veins of different calibre, including abnormal, enlarged vessels and small vascular channels with advanced hyalinization of their walls. H&E. **D)** Vascular changes embedding in the brain parenchyma. H&E. Original magnification A, B, C, D –  $\times 100$ .

consisted of arteries and veins of different calibre with local attenuation of the walls accompanied by small capillary channels embedded in brain parenchyma (Fig. 3D). The brain tissue surrounding the vascular conglomerates showed reactive fibrous gliosis and presence of hemosiderin deposits.

## Discussion

Pleomorphic xanthoastrocytoma (PXA) was first described by Kepes and co-authors in 1979 [27]. It is a rare, low-grade astrocytic tumour, corresponding to WHO grade II that generally affects children and young adults [26,37,39,43]. This tumour develops predominantly at superficial cortical regions with partial occupation of the leptomeninges, more preferably within the temporal lobe [6,10,27]. PXA usually appears as

a highly cellular astrocytic tumour composed of cells of varying size and shape [26,27,34]. The significant cellular pleomorphism includes spindle cells, mononucleated and multinucleated giant cells and lipid-rich vacuolated ones accompanied by eosinophilic granular cell bodies and reticulin fibers. Necrosis is usually absent. A small number of lymphocytes and plasma cells infiltrations are common. Immunohistochemical studies demonstrate diffuse positivity for glial fibrillary acidic protein (GFAP), vimentin and S-100 protein and occasionally neuronal markers expression [14]. About 70% of cases show positive staining for CD34. PXA belongs to grade II of the WHO histological classification of CNS tumours and therefore is considered as a relatively benign lesion with a favourable prognosis [12]. Most cases show typical pathologic features, nevertheless occasionally the tumour undergoes malig-

nant transformation and behaves more aggressively [7,31,33,44]. Nevertheless, the patients with PXA with anaplastic features have a significantly better overall survival than patients with other malignant gliomas [36]. PXAs may recur and demonstrate aggressive clinical behaviour with a mortality rate between 15% and 20%. Such tumours are usually less pleomorphic and more diffusely infiltrative. The mitotic index and extent of resection appear to be the main predictors of recurrence-free time and overall survival rates. The basic treatment of PXA is its total surgical removal whereas the efficacy of adjuvant radiotherapy or chemotherapy has not been clearly defined [34,42]. In rare cases with evidence of dissemination the repeated stereotactic irradiation might be considered.

The primary brain tumours may be accompanied by vascular malformations and such rare coincidence involves mostly gliomas and meningiomas [2,4,13,16,19,20,23,24,29].

Vascular malformations consisting of abnormal arteries and veins are usually congenital. They can occur at any age, but most often between 20 and 40 years of age. Clinical symptoms of AVM depend on its location. Most frequently, AVM presents with headaches and seizures but at least 15% occur asymptomatic. More than 50% of AVMs present with intracranial haemorrhages that account for about 2% of all haemorrhagic strokes each year [1,8,9,11,21]. AVM-specific treatment may involve endovascular embolization, neurosurgery or radiation therapy [5]. Grading schemes were initially developed as a means to predict the surgical risk during obliteration [17,40]. The most commonly used grading scale is the system described by Spetzler and Martin [38].

The association between vascular malformation and cerebral gliomas is unusual. The lesions, consisting of mixed tumours of glial and vascular origin, particularly of cavernous or arteriovenous type, have been often defined as angiogliomas [3,13,19,25,30,41]. The term “angioglioma” is confusing and according to some authors should not be used to determine the true coincidence of vascular and neoplastic glial lesions. However, the term “angioglioma” appears to be valid for rare cases of the low-grade glioma with a distinct vascular pathology. It has been mostly used for highly vascular low-grade gliomas associated with a favourable prognosis [30,32,35]. The pathogenetic suggestions consider such angiogliomatic lesions as a result of reactive astroglial neoplastic proliferation secondary to a pre-existing vascular malformation and/or haemorrhages. Microscopically, the hemosid-

erin-laden macrophages and reactive gliosis could be observed in the vicinity of the lesion. It is important not to confuse such angiogliomatic lesion with high-grade gliomas displaying malignant neovascularity.

The coexistence of clearly demarcated glioma and vascular malformation is rarely identified [4]. Vascular malformations might be associated with different glial components including benign and anaplastic astrocytoma, oligodendroglioma, mixed oligo-astrocytoma or glioblastoma [4,13,15,16,18,20,35,45]. The majority of vascular pathology in coexistence with gliomas consists of arteriovenous malformation (AVM), less often cavernous angioma. Only a few reports describe the coexistence of PXA and AVM [28]. The current case presents the lesion of two separate components of PXA and AVM, that are closely related and form a common tumour mass. The pathogenesis of such coexistence, being the two parts of one tumour, remains still unclear, and further studies of a series of patients are needed.

## References

1. Al-Shahi R, Warlow C. A systematic review of the frequency and prognosis of arteriovenous malformations of the brain in adults. *Brain* 2001; 124: 1900-1926.
2. Arpino L, Di Nuzzo G, Franco A. Pontine cavernoma and intraventricular meningioma: an unusual association. *J Neurosurg Sci* 2011; 55: 397-398.
3. Bonnin JM, Pena CE, Rubinstein LJ. Mixed capillary hemangioblastoma and glioma. A redefinition of the “angioglioma”. *J Neuropathol Exp Neurol* 1983; 42: 504-516.
4. Borges LR, Malheiros SM, Pelaez MP, Stavale JN, Santos AJ, Carrete H Jr, Nogueira RG, Ferraz FA, Gabbai AA. Arteriovenous malformation-glioma association: study of four cases. *Arq Neuropsiquiatr* 2003; 61: 426-429.
5. Bradac O, Charvat F, Benes V. Treatment for brain arteriovenous malformation in the 1998-2011 period and review of the literature. *Acta Neurochir (Wien)* 2013; 155: 199-209.
6. Cervoni L, Salvati M, Santoro A, Celli P. Pleomorphic xanthoastrocytoma: some observations. *Neurosurg Rev* 1996; 19: 13-16.
7. Chakrabarty A, Mitchell P, Bridges LR, Franks AJ. Malignant transformation in pleomorphic xanthoastrocytoma – a report of two cases. *Br J Neurosurg* 1999; 13: 516-519.
8. Crawford PM, West CR, Chadwick DW, Shaw MD. Arteriovenous malformations of the brain: natural history in unoperated patients. *J Neurol Neurosurg Psychiatry* 1986; 49: 1-10.
9. da Costa L, Wallace MC, Ter Brugge KG, O’Kelly C, Willinsky RA, Tymianski M. The natural history and predictive features of hemorrhage from brain arteriovenous malformations. *Stroke* 2009; 40: 100-105.
10. Davies KG, Maxwell RE, Seljeskog E, Sung JH. Pleomorphic xanthoastrocytoma – report of four cases, with MRI scan appearances and literature review. *Br J Neurosurg* 1994; 8: 681-689.

11. Fults D, Kelly DL Jr. Natural history of arteriovenous malformations of the brain: a clinical study. *Neurosurgery* 1984; 15: 658-662.
12. Gallo P, Cecchi PC, Locatelli F, Rizzo P, Ghimenton C, Gerosa M, Pinna G. Pleomorphic xanthoastrocytoma: Long-term results of surgical treatment and analysis of prognostic factors. *Br J Neurosurg* 2013 Mar 20 [Epub ahead of print].
13. Gazzeri R, De Bonis C, Carotenuto V, Catapano D, d'Angelo V, Galarza M. Association between cavernous angioma and cerebral glioma. Report of two cases and literature review of so-called angiogliomas. *Neurocirugia (Astur)* 2011; 22: 562-566.
14. Giannini C, Scheithauer BW, Lopes MB, Hirose T, Kros JM, VandenBerg SR. Immunophenotype of pleomorphic xanthoastrocytoma. *Am J Surg Pathol* 2002; 26: 479-485.
15. Gmeiner M, Sonnberger M, Wurm G, Weis S. Glioblastoma with the appearance of arteriovenous malformation: pitfalls in diagnosis. *Clin Neurol Neurosurg* 2013; 115: 501-506.
16. Goodkin R, Zaias B, Michelsen WJ. Arteriovenous malformation and glioma: coexistent or sequential? Case report. *J Neurosurg* 1990; 72: 798-805.
17. Hamilton MG, Spetzler RF. The prospective application of a grading system for arteriovenous malformations. *Neurosurgery* 1994; 34: 2-6; discussion 6-7.
18. Harris OA, Chang SD, Harris BT, Adler JR. Acquired cerebral arteriovenous malformation induced by an anaplastic astrocytoma: an interesting case. *Neurol Res* 2000; 22: 473-477.
19. Hasegawa H, Bitoh S, Koshino K, Obashi J, Kobayashi Y, Kobayashi M, Wakasugi C. Mixed cavernous angioma and glioma (angioglioma) in the hypothalamus – case report. *Neurol Med Chir (Tokyo)* 1995; 35: 238-242.
20. Heffner RR Jr., Porro RS, Deck MD. Benign astrocytoma associated with arteriovenous malformation. Case report. *J Neurosurg* 1971; 35: 229-233.
21. Hernesniemi JA, Dashti R, Juvela S, Vaart K, Niemela M, Laakso A. Natural history of brain arteriovenous malformations: a long-term follow-up study of risk of hemorrhage in 238 patients. *Neurosurgery* 2008; 63: 823-829; discussion 829-831.
22. Hessler RB, Kfoury H, Al-Watban J, Hassounah M. Angiomatous pleomorphic xanthoastrocytoma as a component of ganglioglioma. *Ann Saudi Med* 1999; 19: 48-51.
23. Holland AJ, Symon L. Spontaneous haemorrhage in a cavernoma associated with a suprasellar meningioma: an unusual post-operative complication. *Br J Neurosurg* 1994; 8: 109-111.
24. Kamiyama H, Nishimura S, Kaimori M, Watanabe M, Furuno Y, Saito A, Nishijima M. Cavernous angioma associated with arteriovenous malformation of the brain – case report. *Neurol Med Chir (Tokyo)* 2010; 50: 131-134.
25. Kasantikul V, Shuangshoti S, Panichabhongse V, Netsky MG. Combined angioma and glioma (angioglioma). *J Surg Oncol* 1996; 62: 15-21.
26. Kepes JJ. Pleomorphic xanthoastrocytoma: the birth of a diagnosis and a concept. *Brain Pathol* 1993; 3: 269-274.
27. Kepes JJ, Rubinstein LJ, Eng LF. Pleomorphic xanthoastrocytoma: a distinctive meningocerebral glioma of young subjects with relatively favorable prognosis. A study of 12 cases. *Cancer* 1979; 44: 1839-1852.
28. Lee TT, Landy HJ, Bruce JH. Arteriovenous malformation associated with pleomorphic xanthoastrocytoma. *Acta Neurochir (Wien)* 1996; 138: 590-591.
29. Licata C, Pasqualin A, Freschini A, Barone G, Da Pian R. Management of associated primary cerebral neoplasms and vascular malformations: 2. Intracranial arterio-venous malformations. *Acta Neurochir (Wien)* 1986; 83: 38-46.
30. Lombardi D, Scheithauer BW, Piepgras D, Meyer FB, Forbes GS. "Angioglioma" and the arteriovenous malformation-glioma association. *J Neurosurg* 1991; 75: 589-566.
31. Marton E, Feletti A, Orvieto E, Longatti P. Malignant progression in pleomorphic xanthoastrocytoma: personal experience and review of the literature. *J Neurol Sci* 2007; 252: 144-153.
32. Matyja E, Grajkowska W, Taraszewska A, Marchel A, Bojarski P, Nauman P. Advanced reactive astrogliosis associated with hemangioblastoma versus astroglial-vascular neoplasm ("angioglioma"). *Folia Neuropathol* 2007; 45: 120-125.
33. Nakajima T, Kumabe T, Shamoto H, Watanabe M, Suzuki H, Tomimaga T. Malignant transformation of pleomorphic xanthoastrocytoma. *Acta Neurochir (Wien)* 2006; 148: 67-71; discussion 71.
34. Pahapill PA, Ramsay DA, Del Maestro RF. Pleomorphic xanthoastrocytoma: case report and analysis of the literature concerning the efficacy of resection and the significance of necrosis. *Neurosurgery* 1996; 38: 822-828; discussion 828-829.
35. Palma L, Mastronardi L, Celli P, d'Addetta R. Cavernous angioma associated with oligo-astrocytoma-like proliferation. Report of two cases and review of the literature with a reappraisal of the term "angioglioma". *Acta Neurochir (Wien)* 1995; 133: 169-173.
36. Perkins SM, Mitra N, Fei W, Shinohara ET. Patterns of care and outcomes of patients with pleomorphic xanthoastrocytoma: a SEER analysis. *J Neurooncol* 2012; 110: 99-104.
37. Rao AA, Laack NN, Giannini C, Wetmore C. Pleomorphic xanthoastrocytoma in children and adolescents. *Pediatr Blood Cancer* 2010; 55: 290-294.
38. Rodriguez-Hernandez A, Kim H, Pourmohamad T, Young WL, Lawton MT, University of California SFAMSP. Cerebellar arteriovenous malformations: anatomic subtypes, surgical results, and increased predictive accuracy of the supplementary grading system. *Neurosurgery* 2012; 71: 1111-1124.
39. Sharma A, Nand Sharma D, Kumar Julka P, Kishor Rath G. Pleomorphic xanthoastrocytoma – a clinico-pathological review. *Neurol Neurochir Pol* 2011; 45: 379-386.
40. Spetzler RF, Martin NA. A proposed grading system for arteriovenous malformations. *J Neurosurg* 1986; 65: 476-483.
41. Suzuki H, Uenohara H, Utsunomiya A, Kurihara N, Suzuki S, Tadokoro M, Iwasaki Y, Sakurai Y, Takei H, Tezuka F. A case of angioglioma composed of astrocytoma with a papillary growth pattern: immunohistochemical and ultrastructural studies. *Brain Tumor Pathol* 2002; 19: 111-116.
42. Tan TC, Ho LC, Yu CP, Cheung FC. Pleomorphic xanthoastrocytoma: report of two cases and review of the prognostic factors. *J Clin Neurosci* 2004; 11: 203-207.
43. Thomas C, Golden B. Pleomorphic xanthoastrocytoma: report of two cases and brief review of the literature. *Clin Neuropathol* 1993; 12: 97-101.
44. Vu TM, Liubinas SV, Gonzales M, Drummond KJ. Malignant potential of pleomorphic xanthoastrocytoma. *J Clin Neurosci* 2012; 19: 12-20.
45. Zuccarello M, Giordano R, Scanarini M, Mingrino S. Malignant astrocytoma associated with arteriovenous malformation. Case report. *Acta Neurochir (Wien)* 1979; 50: 305-309.