

## CASE REPORT

# Acute carotid stenting for treatment of stuttering transient ischemic attacks after recent carotid endarterectomy

Vinodh T Doss,<sup>1</sup> Adam S Arthur,<sup>2</sup> Clarence Watridge,<sup>2</sup> Lucas Elijovich<sup>1,2</sup>

<sup>1</sup>Department of Neurology, University of Tennessee Health Science Center, Memphis, Tennessee, USA

<sup>2</sup>Department of Neurosurgery, Semmes-Murphey Clinic/ University of Tennessee, Memphis, Tennessee, USA

### Correspondence to

Dr L Elijovich, Department of Neurosurgery, Semmes-Murphey Clinic, 6325 Humphreys Blvd, Memphis, TN 38120, USA; lelijovich@semmes-murphey.com

### SUMMARY

Carotid endarterectomy (CEA) is the established standard to treat occlusive extracranial atherosclerotic carotid disease. Complications of CEA must be recognized and dealt with efficiently due to the potentially catastrophic neurologic sequelae. A 67-year-old African American man was transferred from an outside hospital for an acute stroke. He had initially presented with a small right frontal subcortical infarct and had undergone a right CEA 2 days prior to transfer. He had a fluctuating examination with left-sided hemiplegia to slight hemiparesis and inconsistent neglect. Head CT demonstrated a watershed infarct of the right hemisphere. CT angiography demonstrated high grade stenosis at the distal aspect of the CEA anastomosis. He was promptly taken for angiography and underwent acute stenting of the right internal carotid artery. This case demonstrates that carotid artery stenting is a safe management strategy for the treatment of complications associated with failed distal anastomosis during CEA.

### BACKGROUND

Carotid endarterectomy (CEA) is the standard treatment for atherosclerotic occlusive extracranial carotid disease.<sup>1</sup> Known complications of CEA include cervical hematoma, cranial neuropathy, and rarely but most importantly, acute symptomatic re-occlusion or stenosis of the CEA site. The standard treatment for

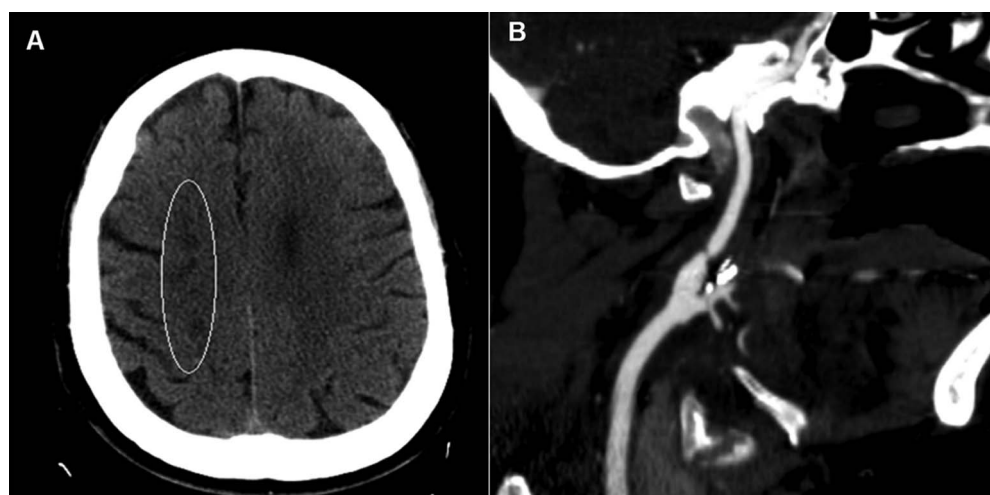
this complication is emergent revision of the CEA.<sup>2,3</sup> In this report we describe the successful endovascular management of a case of acute symptomatic re-stenosis of a CEA with emergent stenting. We discuss the risks and benefits of this approach.

### CASE PRESENTATION

A 67-year-old right-handed African American man with a past medical history of hypertension and hyperlipidemia was emergently transferred from an outside hospital for fluctuating left-sided weakness over a period of 2 h. He had undergone a CEA 2 days previously and was transferred to our hospital when his condition deteriorated. The presenting National Institutes of Health Stroke Scale (NIHSS) score was 12 due to hemiplegia involving the face, arm, and leg on the left, as well as sensory deficits to light touch and hemi-neglect. CT of the head and CT angiography at our institution demonstrated hypodensities in a watershed distribution of the right hemisphere and a small intimal dissection at the distal anastomosis in the cervical right internal carotid artery with associated high grade stenosis. There was no tandem intracranial embolus identified (figure 1).

### TREATMENT

Diagnostic angiography was performed with a 4 Fr JB2 catheter. Right common carotid injection



**Figure 1** (A) Non-contrast head CT demonstrates a watershed infarct in the territory of the right anterior circulation. (B) Volume rendered three-dimensional reconstructed maximum intensity projection CT angiography of the neck demonstrates a high grade stenosis distal to the right internal carotid bulb at the site of the carotid endarterectomy anastomosis.

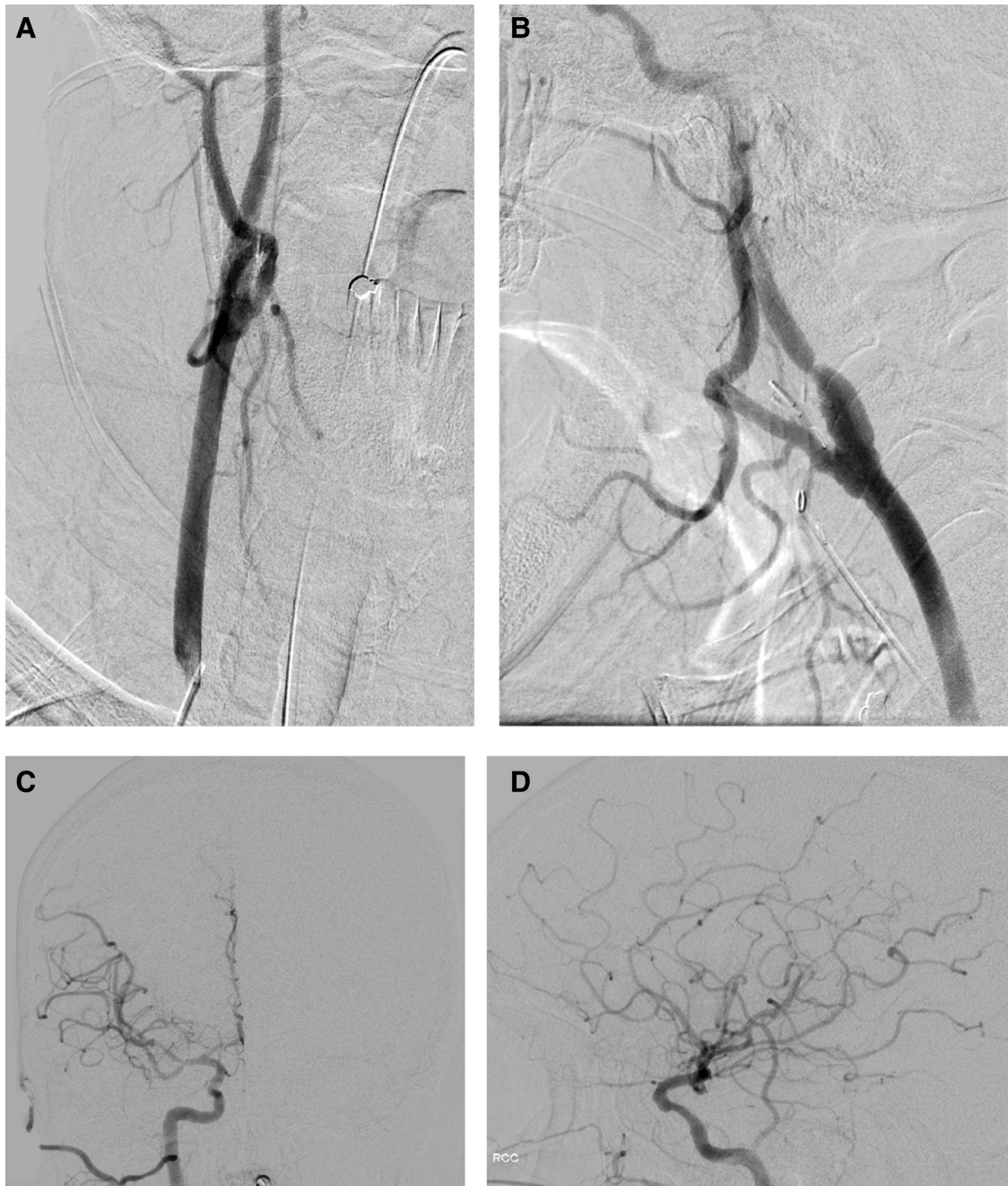
**To cite:** Doss VT, Arthur AS, Watridge C, et al. *BMJ Case Rep* Published online: [please include Day Month Year] doi:10.1136/bcr-2013-010766

confirmed high grade stenosis (76% using the NASCET (North American Symptomatic Carotid Endarterectomy Trial) criteria) with a dissection flap at the distal CEA anastomosis site without intracranial occlusion (figure 2). Stenting was performed under general anesthesia due to concerns regarding the patient's ability to maintain his airway while supine for a prolonged period due to his acute neurologic deterioration. After intubation, the 4 Fr sheath was exchanged for a 6 Fr Shuttle into the descending aorta, and a 6 Fr slip-tip catheter was then advanced coaxially through the Shuttle Sheath and used to select the right common carotid artery over a 0.035 angled guidewire. The patient was loaded with 600 mg of Plavix through a nasogastric tube and

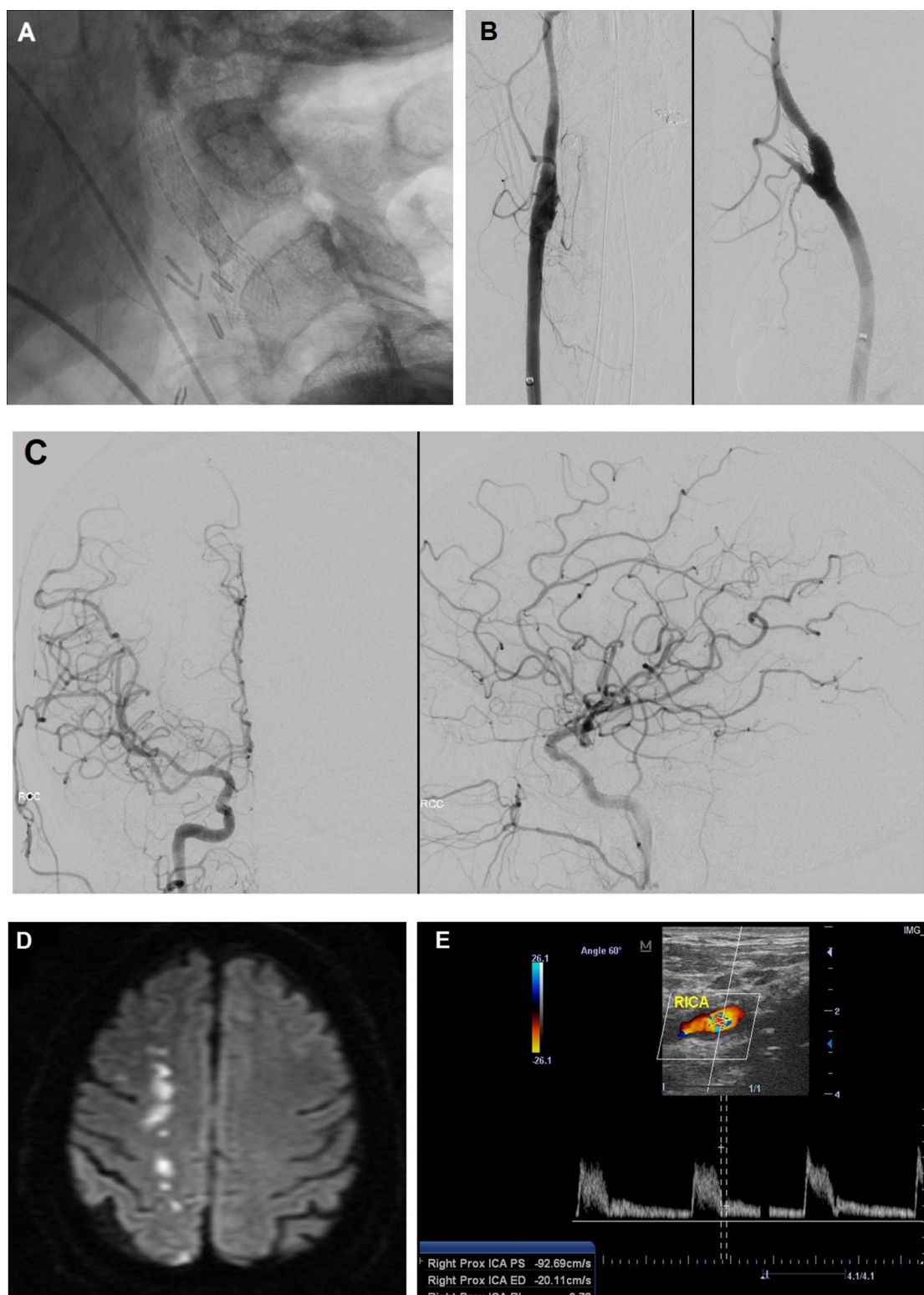
the patient was heparinized to an activated clotting time of over 200.

A distal protection device (a 5 mm Cordis Angioguard emboli capture system) was placed under roadmap guidance into the distal cervical internal carotid artery. The carotid stent (8 mm×30 mm 5 Fr Precise carotid stent) was carefully deployed under fluoroscopy across the area of maximal stenosis. Post stenting angiography demonstrated good apposition of the stent against the arterial wall with correction of the previously noted flap and no residual stenosis (figure 3).

The patient's hospital course was otherwise uncomplicated. He was discharged home 2 days after the procedure with slight facial



**Figure 2** (A) Right common carotid digital subtraction angiography pre-stent placement. (A, B) Cervical anteroposterior (AP) and lateral images demonstrate a patent carotid bulb with high grade stenosis (ie, measures 78% by NASCET (North American Symptomatic Carotid Endarterectomy Trial) criteria) in the proximal internal carotid artery at the site of the carotid endarterectomy anastomosis. (C, D) Head AP and lateral images do not demonstrate any intracranial tandem stenosis or occlusion.



**Figure 3** (A) Native lateral fluoroscopic image demonstrates a fully deployed stent within the right internal carotid artery (RICA). (B) Anteroposterior (AP) and lateral right common carotid digital subtraction angiogram over the cervical region demonstrates relief of the stenosis without any evidence of residual dissection flap. (C) AP and lateral right common carotid digital subtraction angiogram over the head does not demonstrate any intracranial tandem stenosis or occlusion post stenting. (D, E) Diffusion weighted MRI of the brain post stenting with subacute watershed infarct, as seen on the presenting non-contrast head CT (figure 1A) without a new acute infarct. Follow up ultrasound at six months demonstrates long term patency of the carotid stent.

weakness and paresis of his left upper extremity. He had an NIHSS score of 2 and a modified Rankin Scale score of 1. At the 6 month follow-up in the clinic, he was neurologically normal with a modified Rankin Scale score of 0, and had returned to work.

#### DISCUSSION

Acute carotid artery stenting (CAS) after CEA has been previously described in a series of mostly asymptomatic patients. The majority of symptomatic patients were found to have thrombus

at the CEA site while only one was similar to our patient with a flow limiting intimal flap/dissection at the distal CEA anastomosis site.<sup>4</sup> In most cases, CAS is considered in cases of chronic re-stenosis after a CEA. In several studies, CAS is preferred compared to re-operation as complication rates are similar to CEA.<sup>5</sup> In these delayed cases of restenosis, the presence of scar tissue and the potential need for an interposition graft to permit closure of the arterotomy are the technical aspects of redo CEA that can increase the risk of the procedure and make CAS a suitable alternative. Additionally, previous CEA is an established high-risk criterion that has been demonstrated to favor treatment with CAS.<sup>6</sup>

In traumatic or spontaneous cervical arterial dissection, medical management is often the first line therapy because spontaneous healing is common over first 3-to-6 months, and stenosis may resolve in up to 90% of cases.<sup>7-8</sup> Endovascular treatment is reserved for patients with recurrent symptoms on medical management or those with symptomatic hemodynamic failure on presentation.

In our patient, the treatment was emergent and the decision to treat was based on the hemodynamic compromise and new symptoms.<sup>9</sup> Furthermore, the intimal flap at the anastomotic site would likely not have had the benign natural history as the majority of spontaneous or traumatic dissections. This was a technical problem that would not have improved with anticoagulation and would need to be repaired regardless of the symptomatic status. In the past, we have treated these patients with reoperation and often have found that this complication can be either treated or avoided altogether through the usage of circumferential, vertically oriented tack-up sutures using 6-0 prolene at the site where the distal plaque is fractured from the intima.<sup>10-11</sup> The decision on open versus endovascular treatment in this case was both technical and practical. We felt, based on angiography, that the lesion could be safely treated with CAS, and most importantly that an endovascular strategy would be most efficient in limiting total ischemic time. Alternatively, in cases of acute thrombosis at the CEA site reoperation and thrombectomy have been the standard treatment. However, the new generation of endovascular embolectomy devices may present an alternative in some patients who may not tolerate re-operation and/or have occlusion documented after exit from the operating room.

There were several factors that made CAS a suitable treatment option. We were able to pass a distal protection device without pre-dilation, thus mitigating the risk of embolic complications and avoiding possible trauma to a vulnerable recent surgical anastomosis site. The high-risk of procedural stroke (i.e., CEA or CAS) in this situation highlights the unique advantage of endovascular treatment as any tandem intracranial occlusion could be treated at the same setting, thus reducing overall ischemic time. Important considerations prior to stenting include the

obligatory use of dual anti-platelets in the setting of recent surgery and ischemic stroke.

In conclusion, CAS may be considered a safe alternative to redo CEA for acute occlusion or stenosis after acute failure of CEA in properly selected patients.

### Learning points

- ▶ Carotid endarterectomy (CEA) is the standard treatment of atherosclerotic occlusive extracranial carotid disease.
- ▶ One problematic complication of CEA is acute symptomatic re-occlusion or stenosis of the CEA site.
- ▶ Symptomatic acute re-stenosis following CEA can be treated successfully with emergent carotid artery stenting in selected cases.

**Contributors** ASA and LE provided the conception and design. ASA, CW, and LE performed the analysis and interpretation of the data. VTD and LE drafted the manuscript. All authors revised the manuscript critically for important intellectual content, and ASA and LE provided final approval of the version to be published.

**Competing interests** ASA has served as a consultant for Covidien, Johnson and Johnson, Siemens, Stryker, and Terumo, and has received or has grants pending from Siemens and Terumo.

**Patient consent** Obtained.

**Provenance and peer review** Not commissioned; externally peer reviewed.

### REFERENCES

- 1 Ferguson GG, Eliasziw M, Barr HW, *et al.* The North American Symptomatic Carotid Endarterectomy Trial: surgical results in 1415 patients. *Stroke* 1999;30:1751–8.
- 2 Lal BK, Hobson RW II. Management of carotid restenosis. *J Cardiovasc Surg* 2006;47:153–60.
- 3 Gagne PJ, Riles TS, Jacobowitz GR, *et al.* Long-term follow-up of patients undergoing reoperation for recurrent carotid artery disease. *J Vasc Surg* 1993;18:991–8.
- 4 Marone EM, Coppi G, Tshomba Y, *et al.* Eight-year experience with carotid artery stenting for correction of symptomatic and asymptomatic post-endarterectomy defects. *J Vasc Surg* 2010;52:1511–7.
- 5 New G, Roubin GS, Iyer SS, *et al.* Safety, efficacy, and durability of carotid artery stenting for restenosis following carotid endarterectomy: a multicenter study. *J Endovasc Ther* 2000;7:345–52.
- 6 Yadav JS, Wholey MH, Kuntz RE, *et al.* Protected carotid-artery stenting versus endarterectomy in high-risk patients. *N Engl J Med* 2004;351:1493–501.
- 7 Schwartz NE, Vertinsky AT, Hirsch KG, *et al.* Clinical and radiographic natural history of cervical artery dissections. *J Stroke Cerebrovasc Dis* 2009;18:416–23.
- 8 Redekop GJ. Extracranial carotid and vertebral artery dissection: a review. *Can J Neurol Sci* 2008;35:146–52.
- 9 Fava M, Meneses L, Loyola S, *et al.* Carotid artery dissection: endovascular treatment. Report of 12 patients. *Catheter Cardiovasc Interv* 2008;71:694–700.
- 10 Curtis JA, Johansen K. Techniques in carotid artery surgery. *Neurosurg Focus* 2008;24:E18.
- 11 Spetzler RF, Martin N, Hadley MN, *et al.* Microsurgical endarterectomy under barbiturate protection: a prospective study. *Br J Neurosurg* 1986;65:63–73.

Copyright 2013 BMJ Publishing Group. All rights reserved. For permission to reuse any of this content visit <http://group.bmj.com/group/rights-licensing/permissions>.

BMJ Case Report Fellows may re-use this article for personal use and teaching without any further permission.

Become a Fellow of BMJ Case Reports today and you can:

- ▶ Submit as many cases as you like
- ▶ Enjoy fast sympathetic peer review and rapid publication of accepted articles
- ▶ Access all the published articles
- ▶ Re-use any of the published material for personal use and teaching without further permission

For information on Institutional Fellowships contact [consortiasales@bmjgroup.com](mailto:consortiasales@bmjgroup.com)

Visit [casereports.bmj.com](http://casereports.bmj.com) for more articles like this and to become a Fellow