

Loading Dose of Clopidogrel in Combination with Other Antithrombotic Therapy for Capsular Warning Syndrome

Hiroyuki Kawano, MD,*† Makoto Nakajima, MD,‡ Yuichiro Inatomi, MD,†
Toshiro Yonehara, MD,† and Yukio Ando, MD‡

A 66-year-old man had repeated stereotypical transient ischemic attacks (TIAs) of dysarthria and left hemiparesis. His symptoms were considered capsular warning syndrome (CWS), for which the responsible lesion was found on magnetic resonance imaging to be in the right putamen expanding to the corona radiata. Although administration of antithrombotic therapy including aspirin was ineffective, no further TIAs occurred after a loading dose of clopidogrel was added. A loading dose of clopidogrel combined with other antithrombotic therapy might be an effective treatment for CWS. **Key Words:** Antiplatelet—clopidogrel—stroke—transient ischemic attack.

© 2014 by National Stroke Association

Introduction

The capsular warning syndrome (CWS) is defined as recurrent stereotypical episodes of motor and/or sensory dysfunction without cortical symptoms.¹ CWS carries a significant risk of disabling stroke because as many as 42%-60% patients with CWS develop fixed deficits,^{1,2} but effective therapies remain controversial. A patient with CWS whose clinical outcome was favorable after administration of a loading dose of clopidogrel in addition to other antithrombotic therapy is presented.

From the *Department of Neurology, Minamata City General Hospital and Medical Center, Minamata, Kumamoto; †Department of Neurology, Saiseikai Kumamoto Hospital, Kumamoto; and ‡Department of Neurology, Graduate School of Medical Sciences, Kumamoto University, Kumamoto, Japan.

Received August 29, 2013; revision received September 17, 2013; accepted September 18, 2013.

Disclosure: None.

Funding: None.

Address correspondence to Hiroyuki Kawano, MD, Department of Neurology, Minamata City General Hospital and Medical Center, 1-2-1 Tenjin-cho, Minamata, Kumamoto 867-0041, Japan. E-mail: hkawanoo@gmail.com.

1052-3057/\$ - see front matter

© 2014 by National Stroke Association

<http://dx.doi.org/10.1016/j.jstrokecerebrovasdis.2013.09.020>

Case Report

A 66-year-old man with untreated hypertension and dyslipidemia suddenly developed dysarthria and left hemiparesis at 1 AM, and his symptoms lasted for half an hour; he then experienced 3 more of the same transient events. He was taken to our hospital at 8:30 AM by ambulance during the fourth set of stereotypical symptoms. His symptoms disappeared rapidly in the emergency department. The diffusion-weighted imaging done immediately after the fourth transient ischemic attack (TIA) showed a slightly hyperintense lesion in the right corona radiata (Fig 1, A). Despite administration of aspirin (200 mg daily), cilostazol (200 mg daily), atorvastatin (5 mg daily), argatroban, edaravone, and plasma expander, several stereotypical TIAs occurred repeatedly. His electrocardiogram, transthoracic echocardiogram, and carotid ultrasonography were normal. Diffusion-weighted imaging at 1:50 PM, soon after the seventh TIA, showed acute infarcts in the right putamen expanding to the corona radiata (Fig 1, C). Clopidogrel with a loading dose (300 mg) was started after the 10th TIA. Three more attacks occurred for 2 hours; however, he had no further TIAs thereafter. Overall, he experienced 13 stereotypical TIAs with a duration of 2-52 minutes (18 ± 12 minutes) over 2 days. He was

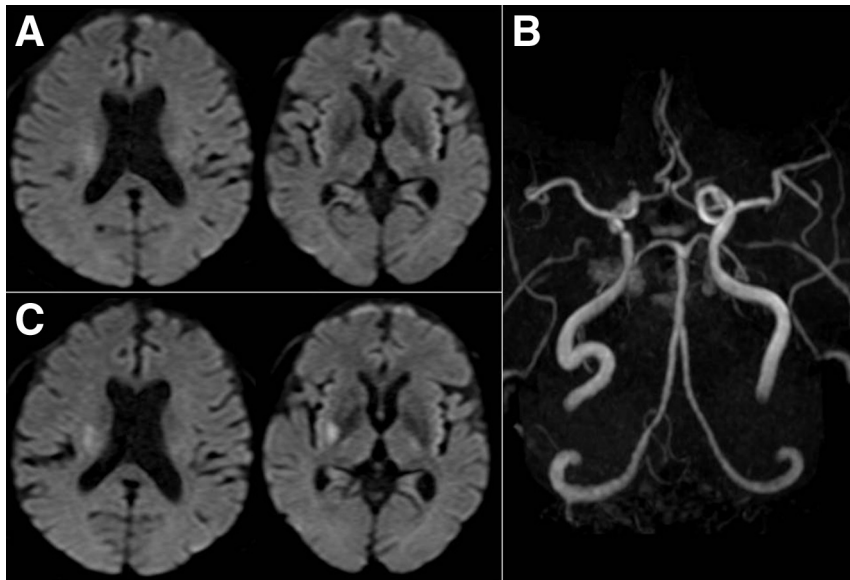


Figure 1. (A) Diffusion-weighted imaging (DWI, b value = 1000 s/mm^2) and (B) magnetic resonance angiography performed immediately after the fourth transient ischemic attack (TIA) show slightly hyperintense lesions in the right corona radiata and a stenotic lesion in the intracranial right internal carotid artery but no occlusion in the right middle cerebral artery, respectively. DWI 13 hours after the initial TIA, immediately after the seventh TIA, reveals an acute infarct in the right putamen expanding to the corona radiata (C).

discharged with no neurologic deficit after 16 days of hospitalization.

Discussion

The present case is unique in that repetitive TIAs ceased approximately 2 hours after administration of a loading dose of clopidogrel in addition to other antithrombotic agents. Considering the rapid response, the clopidogrel loading dose might have been the most effective treatment for this patient.

Concerning treatment for patients with CWS, heparin¹ or intravenous thrombolysis^{3,4} do not entirely prevent further ischemic strokes or residual deficits. Clopidogrel load in combination with aspirin was effective on preventing from leading up to infarction in patients with CWS in some reports,^{5,6} although clopidogrel load alone was not so evident in the other report.⁴

When clopidogrel is started at a maintenance dose, it takes several days for its antiplatelet effects to appear. No benefit of the combination of clopidogrel and aspirin for secondary prevention of ischemic stroke has been shown.⁷ In contrast, a loading dose of clopidogrel has been shown to produce a rapid pharmacodynamic action within the first hours after administration.⁸ Indeed, in patients with acute coronary syndrome, a loading dose of clopidogrel added to standard antithrombotic treatment within 24 hours of symptom onset significantly reduced subsequent ischemic events compared with aspirin alone.⁹ Moreover, use of the loading dose of clopidogrel and aspirin for acute minor stroke or TIA within 24 hours of onset has recently been reported to be superior to aspirin alone and not to increase the incidence of hemorrhage.¹⁰

The clinical course of the present patient was consistent with the pharmacodynamic action of the clopidogrel loading dose. Combined antithrombotic therapy, includ-

ing a clopidogrel loading dose, might be a preferred treatment for patients with CWS, although further studies are necessary to clarify the best strategy.

References

1. Donnan GA, O'Malley HM, Quang L, et al. The capsular warning syndrome: pathogenesis and clinical features. *Neurology* 1993;43:957-962.
2. Paul NL, Simoni M, Chandratheva A, et al. Population-based study of capsular warning syndrome and prognosis after early recurrent TIA. *Neurology* 2012;79:1356-1362.
3. Vivanco-Hidalgo RM, Rodriguez-Campello A, Ois A, et al. Thrombolysis in capsular warning syndrome. *Cerebrovasc Dis* 2008;25:508-510.
4. Tassi R, Cerase A, Acampa M, et al. Stroke warning syndrome: 18 new cases. *J Neurol Sci* 2013;331:168-171.
5. Fahey CD, Alberts MJ, Bernstein RA. Oral clopidogrel load in aspirin-resistant capsular warning syndrome. *Neurocrit Care* 2005;2:183-184.
6. Asil T, Ir N, Karaduman F, et al. Combined antithrombotic treatment with aspirin and clopidogrel for patients with capsular warning syndrome: a case report. *Neurologist* 2012;18:68-69.
7. Diener HC, Bogousslavsky J, Brass LM, et al, MATCH investigators. Aspirin and clopidogrel compared with clopidogrel alone after recent ischaemic stroke or transient ischaemic attack in high-risk patients (MATCH): randomised, double-blind, placebo-controlled trial. *Lancet* 2004;364:331-337.
8. Savcic M, Hauert J, Bachmann F, et al. Clopidogrel loading dose regimens: kinetic profile of pharmacodynamic response in healthy subjects. *Semin Thromb Hemost* 1999;25(Suppl 2):15-19.
9. Yusuf S, Zhao F, Mehta SR, et al. Effects of clopidogrel in addition to aspirin in patients with acute coronary syndromes without ST-segment elevation. *N Engl J Med* 2001;345:494-502.
10. Wang Y, Wang Y, Zhao X, et al, CHANCE Investigators. Clopidogrel with aspirin in acute minor stroke or transient ischemic attack. *N Engl J Med* 2013;369:11-19.