

Laser-Interstitial Thermal Therapy for Refractory Cerebral Edema from Post-Radiosurgery Metastasis

Andrew J. Fabiano^{1,3} and Ronald A. Alberico²

Key words

- Edema
- Laser
- Metastasis
- Necrosis
- Radiation
- Thermal

Abbreviations and Acronyms

LITT: Laser-interstitial thermal therapy

MR: Magnetic resonance



From the Departments of ¹Neurosurgery and ²Radiology, Roswell Park Cancer Institute; and ³Department of Neurosurgery, School of Medicine and Biomedical Sciences, University at Buffalo, State University of New York, Buffalo, New York, USA

To whom correspondence should be addressed:
Andrew J. Fabiano, M.D.

[E-mail: Andrew.Fabiano@roswellpark.org]

Citation: *World Neurosurg.* (2014) 81, 3/4:652.e1-652.e4.
<http://dx.doi.org/10.1016/j.wneu.2013.10.034>

Journal homepage: www.WORLDNEUROSURGERY.org

Available online: www.sciencedirect.com

1878-8750/\$ - see front matter © 2014 Elsevier Inc.
All rights reserved.

INTRODUCTION

Stereotactic radiosurgery is often the treatment of choice for brain metastases (5). Persistent or worsening cerebral edema can occur after radiosurgery and, in some instances, patients can develop radiation necrosis (1). Treatment of this edema includes observation, corticosteroid therapy, and surgical removal of the mass. Systemic side effects from corticosteroids and lesions that are difficult to access surgically can make the treatment of edema after radiosurgery for a metastasis difficult.

Laser-interstitial thermal therapy (LITT) delivers focal heat energy to coagulate tissue with a sharp ablation boundary zone (8). Intracranial LITT involves the stereotactic placement of a probe into a lesion followed by laser ablation while performing real-time magnetic resonance (MR) thermometry to monitor intracranial temperature. Recent studies have suggested the utility of LITT in the treatment of brain

■ **BACKGROUND:** Stereotactic radiosurgery is often an effective tool for the treatment of brain metastases. A complication of radiosurgical treatment for brain metastasis can be persistent cerebral edema. Treatments of this refractory cerebral edema include observation, corticosteroids, and surgical resection of the edema-inducing mass. Laser-interstitial thermal therapy is a minimally invasive technique for ablating intracranial lesions. It may provide a treatment option for metastases after radiosurgery causing refractory cerebral edema.

■ **CASE DESCRIPTION:** We report the case of a 64-year-old man with lung adenocarcinoma presenting to our department with left hemiparesis. Brain magnetic resonance imaging showed an 18-mm enhancing lesion in the right external capsule with significant surrounding edema. The lesion was treated by radiosurgery. There was persistent edema after radiosurgery. The patient required continued corticosteroid therapy to maintain his ability to ambulate. He developed refractory hyperglycemia, weight gain, and bilateral proximal muscle weakness secondary to this therapy. Fourteen weeks after radiosurgery, he underwent laser-interstitial thermal therapy for lesion ablation. He was weaned off corticosteroids during 2 weeks and maintained his strength during the following month.

■ **CONCLUSIONS:** Laser-interstitial thermal therapy may be a treatment option for refractory cerebral edema after stereotactic radiosurgery to a metastasis. This therapy may be of particular use in deep-seated lesions refractory to corticosteroid therapy.

metastases and intracranial radiation necrosis (2, 8).

Persistent cerebral edema despite conventional therapies in patients with brain metastases remains a neurosurgical challenge. Current alternative therapies include bevacizumab and pentoxifylline combined with vitamin E (6, 10). LITT may be a useful treatment option for cerebral edema after stereotactic radiosurgery to a metastasis.

CASE REPORT

History and Physical Examination

A 64-year-old man with lung adenocarcinoma presented with left hemiparesis. He was diagnosed with stage IIIB lung adenocarcinoma 3 years prior, for which he underwent a pneumonectomy followed by chest radiotherapy and cisplatin–gemcitabine chemotherapy. The patient's past medical

history was significant for hypertension, atrial fibrillation, and coronary artery disease status after coronary artery bypass grafting. On physical examination, the patient had a left hemiparesis with left proximal lower extremity strength of 2/5 and was unable to ambulate. His right lower extremity was full strength. Of note, he had no history of diabetes mellitus and his admission blood glucose level was 118 mg/dL.

Imaging Findings and Preoperative Course

MR imaging of the brain showed an 18-mm contrast-enhancing lesion in the right hemisphere adjacent to the external capsule just anterior to descending motor fibers with significant surrounding edema consistent with a brain metastasis (Figure 1A). The patient was started on corticosteroid therapy (dexamethasone), and his strength improved to a level where he was able to ambulate with a walker. His

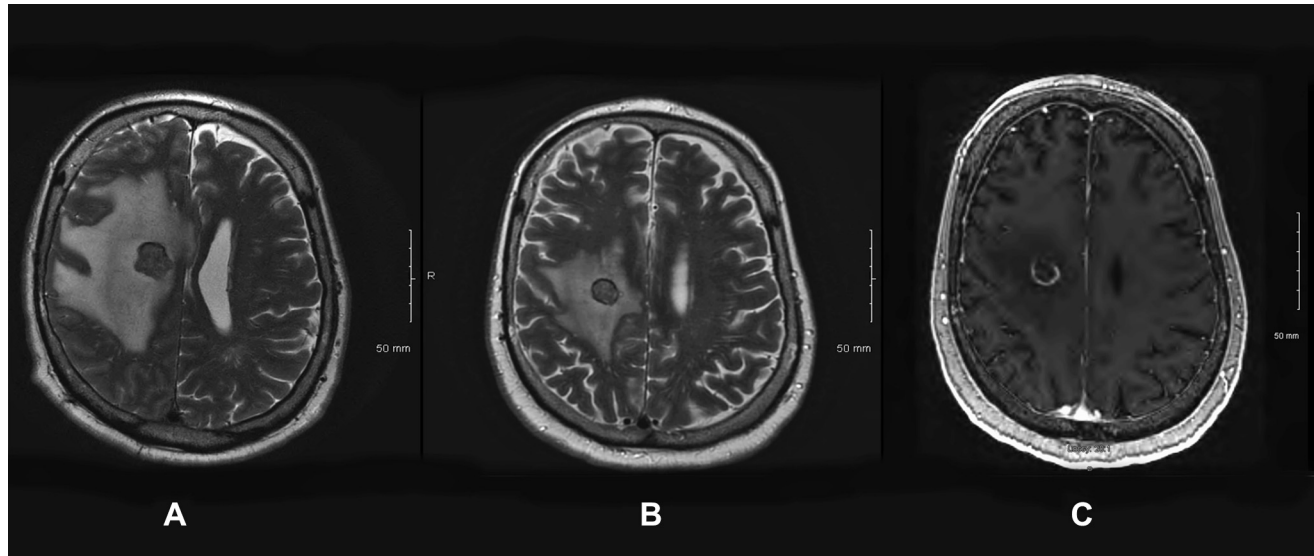


Figure 1. Representative T₂-weighted axial magnetic resonance images demonstrating cerebral edema in a 64-year-old man with a lung adenocarcinoma brain metastasis. **(A)** At presentation. **(B)** Fourteen weeks after stereotactic radiosurgery while the patient was receiving high-dose

corticosteroid therapy. **(C)** Gadolinium-enhanced T₁-weighted image at 14 weeks after stereotactic radiosurgery showing partial marginal enhancement.

proximal left lower extremity strengthened while receiving corticosteroid therapy, which was 4-/5.

Operations and Hospital Course

The lesion was treated by gamma knife (Elekta, Stockholm, Sweden) stereotactic radiosurgery with a dose of 16 Gy to the tumor margin. There was persistent edema after radiosurgery (**Figure 1B**), and the patient required continued corticosteroid therapy to maintain his ability to ambulate with assistance. Gadolinium-enhanced MR imaging (**Figure 1C**) revealed a T₁/T₂ mismatch (7). The patient developed refractory hyperglycemia requiring insulin injection, weight gain, and bilateral proximal muscle weakness (3/5 left, 4/5 right) secondary to the corticosteroids. He was considered a poor candidate for a craniotomy given the deep location of the edema-inducing lesion and his medical comorbidities.

Fourteen weeks after radiosurgery, the patient underwent LITT ablation of the lesion under general anesthesia. A frameless stereotactic navigation system (Medtronic, Minneapolis, Minnesota, USA) was used to place a Visualase probe (Visualase Inc., Houston, Texas, USA) into the lesion through a 2-cm incision using a method

similar to the placement of a stereotactic brain biopsy needle. The patient was then transported to the MR imaging suite. An initial image was obtained to confirm adequate placement of the probe (**Figure 2**). Real-time gradient echo MR thermometry was then used to constantly monitor the intracranial temperature. Several automatic stops were set in the brain surrounding the lesion to limit any damage to the surrounding tissue. Although continuous irrigation was maintained through the probe to control the temperature of the 980-nm diode laser, a thermal ablation of the lesion was performed. The lesion was treated at a temperature of 60° to 95°C, and the treatment time was 2 minutes. An MR image after the ablation was obtained to verify that the treated area matched the surgical goal and there was no evidence of intracranial hemorrhage. The probe was removed, and the incision was closed in the recovery room. The patient went home on the first post-operative day, without issue.

Postoperative Course

The patient was weaned off of corticosteroid therapy during the next 2 weeks. MR imaging at that time showed decreased edema (**Figure 3A**). At 10 weeks after the procedure, he was not receiving corticosteroids and

was ambulating without assistance. MR imaging showed a decrease in the size of the lesion and a small amount of residual edema (**Figure 3B**). The patient's right proximal lower extremity returned to full strength, and his left proximal lower extremity strength was 4+/5.

DISCUSSION

Multiple treatment options exist after stereotactic radiosurgery radiation necrosis. In patients who are asymptomatic, close monitoring with serial imaging is often

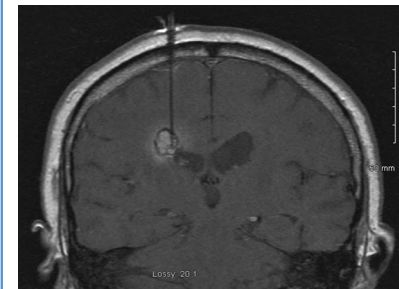


Figure 2. Representative T₁-weighted coronal magnetic resonance image demonstrating a laser-interstitial thermal therapy probe placed within a lesion just before thermal ablation.

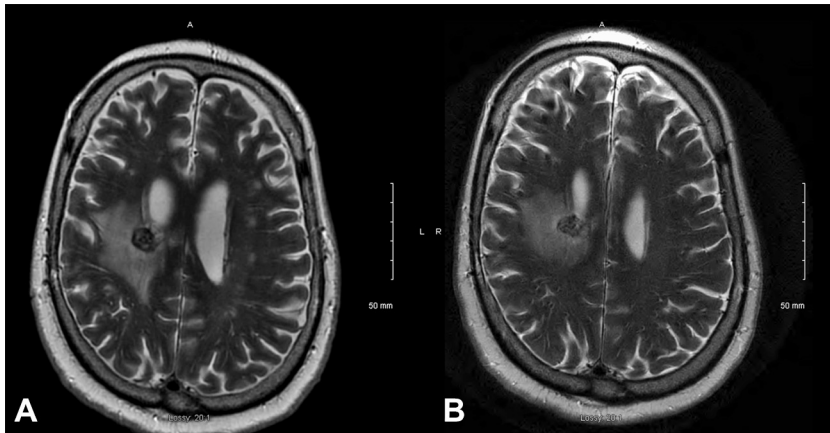


Figure 3. Representative T₂-weighted axial magnetic resonance images demonstrating cerebral edema in a 64-year-old man with a lung adenocarcinoma brain metastasis previously treated with stereotactic radiosurgery and laser-interstitial thermal therapy (LITT). (A) Two weeks after LITT. (B) Ten weeks after LITT. Of note, the patient's corticosteroid dose was tapered during a 2-week period after LITT.

sufficient. In those patients who become symptomatic from persistent edema or direct mass effect, treatment is warranted. Corticosteroids are the first line of treatment as a temporizing measure until the inflammatory reaction rescinds. If corticosteroids are insufficient or intolerable, craniotomy or bevacizumab is warranted. It is at this stage in a patient's treatment course that LITT may be of value as an additional, minimally invasive option. Of note, pentoxifylline combined with vitamin E can be added to the treatment regimen in both asymptomatic and symptomatic patients (4).

LITT uses light to create thermal energy in a reproducible, precise fashion. At temperatures more than 60°C, thermal damage (coagulation) occurs, resulting in cell death. LITT offers a new therapeutic option for brain lesions. Small studies have reported its use for brain metastases refractory to standard therapy and for cerebral radiation necrosis (2, 8). LITT has been used to treat colorectal liver metastases with long-term outcome data extending beyond 5 years (3). Its role in the treatment paradigm for brain metastases remains unclear.

Patients treated by stereotactic radiosurgery are often weaned off of corticosteroid therapy 4 to 6 weeks after the procedure once the treatment has had its effect. For those patients experiencing persistent edema for more than 2 months

after the procedure, it can be difficult to predict when, if ever, the cerebral edema will resolve.

It is within this "limbo" period that LITT may have a role in the treatment of brain metastases. The treated mass continues to perpetuate an inflammatory cascade, leading to edema. LITT offers a minimally invasive method to ablate this mass, thus reducing cerebral irritation and edema. This ablation can result in symptom improvement and the elimination of corticosteroid therapy, as it did in the patient described. Although open surgical resection has been used in similar instances, in patients with deep-seated lesions who are poor open surgical candidates owing to medical comorbidities, LITT may provide a viable alternative.

It is possible that the lesion treated in this patient was a recurrent metastatic tumor, rather than radiation necrosis. The patchy peripheral enhancement of the lesion on follow-up MR imaging and temporal relation to radiosurgical treatment support the diagnosis of radiation necrosis. Unfortunately, there is currently no neuroimaging study capable of non-invasively differentiating these pathologies in a reliable fashion (9). However, as LITT treats both radiation necrosis and metastatic disease, it provides a valuable treatment option in such a scenario.

Long-term outcome data for the treatment of brain metastases with LITT is not

yet available. The ability of this procedure to control cerebral edema-inducing effects of metastatic disease and radiation necrosis in the long term will be a major determinant of its utility. LITT is likely limited to those lesions with a diameter of ≤ 3 cm. With larger lesions, a steep temperature gradient cannot be as easily maintained at the edges of the lesion. Currently, the probes used during LITT ablation are disposable. Once outcome data are available, a cost-analysis may be prudent.

LITT has been suggested as a treatment option for refractory brain metastases and radiation necrosis. The present report describes the use of LITT to ablate a metastasis 14 weeks after radiosurgery, resulting in a reduction in cerebral edema and the termination of corticosteroid therapy. Further study is warranted to determine the exact role LITT will play in the treatment of patients with brain metastases.

CONCLUSIONS

LITT may be a viable, minimally invasive treatment option for refractory cerebral edema after stereotactic radiosurgery to a brain metastasis. This therapy may be of particular use for ablation of deep-seated lesions that have failed corticosteroid therapy.

ACKNOWLEDGMENTS

The authors thank Paul H. Dressel, B.F.A., for preparation of the illustrations and Debra J. Zimmer for editorial assistance.

REFERENCES

1. Breneman JC, Warnick RE, Albright RE Jr, Kukiatinant N, Shaw J, Armin D, Tew J Jr: Stereotactic radiosurgery for the treatment of brain metastases. Results of a single institution series. *Cancer* 79:551-557, 1997.
2. Carpentier A, McNichols RJ, Stafford RJ, Itzcovitz J, Guichard JP, Reizine D, Delalogue S, Vicaut E, Payen D, Gowda A, George B: Real-time magnetic resonance-guided laser thermal therapy for focal metastatic brain tumors. *Neurosurgery* 63:ONS21-ONS29, 2008.
3. Christophi C, Nikfarjam M, Malcontenti-Wilson C, Muralidharan V: Long-term survival of patients with unresectable colorectal liver metastases treated by percutaneous interstitial laser thermotherapy. *World J Surg* 28:987-994, 2004.
4. Delanian S, Porcher R, Rudant J, Lefaix JL: Kinetics of response to long-term treatment combining pentoxifylline and tocopherol in patients

- with superficial radiation-induced fibrosis. *J Clin Oncol* 23:8570-8579, 2005.
5. Flickinger JC, Kondziolka D, Lunsford LD, Coffey RJ, Goodman ML, Shaw EG, Hudgins WR, Weiner R, Harsh GR 4th, Sneed PK, Larson DA: A multi-institutional experience with stereotactic radiosurgery for solitary brain metastasis. *Int J Radiat Oncol Biol Phys* 28:797-802, 1994.
 6. Gonzalez J, Kumar AJ, Conrad CA, Levin VA: Effect of bevacizumab on radiation necrosis of the brain. *Int J Radiat Oncol Biol Phys* 67:323-326, 2007.
 7. Kano H, Kondziolka D, Lobato-Polo J, Zorro O, Flickinger JC, Lunsford LD: T1/T2 matching to differentiate tumor growth from radiation effects after stereotactic radiosurgery. *Neurosurgery* 66:486-492, 2010.
 8. Rahmathulla G, Recinos PF, Valerio JE, Chao S, Barnett GH: Laser interstitial thermal therapy for focal cerebral radiation necrosis: a case report and literature review. *Stereotact Funct Neurosurg* 90:192-200, 2012.
 9. Verma N, Cowperthwaite MC, Burnett MG, Markey MK: Differentiating tumor recurrence from treatment necrosis: a review of neuro-oncologic imaging strategies. *Neuro Oncol* 15:515-534, 2013.
 10. Williamson R, Kondziolka D, Kanaan H, Lunsford LD, Flickinger JC: Adverse radiation effects after radiosurgery may benefit from oral vitamin E and pentoxifylline therapy: a pilot study. *Stereotact Funct Neurosurg* 86:359-366, 2008.
- Conflict of interest statement: The authors declare that the article content was composed in the absence of any commercial or financial relationships that could be construed as a potential conflict of interest.*
- Received 26 July 2013; accepted 12 October 2013; published online 16 October 2013*
- Citation: World Neurosurg. (2014) 81, 3/4:652.e1-652.e4. <http://dx.doi.org/10.1016/j.wneu.2013.10.034>*
- Journal homepage: www.WORLDNEUROSURGERY.org*
- Available online: www.sciencedirect.com*
- 1878-8750/\$ - see front matter © 2014 Elsevier Inc. All rights reserved.*