

## Authors:

Hyo-Sang Kim, MD  
Chang-Hwan Kim, MD  
Myeong-Ok Kim, MD  
Kyung-Lim Joa, MD  
Hyung Chung, MD  
Han-Young Jung, MD

Stroke

## CASE REPORT

## Affiliations:

From the Neurorehabilitation Section,  
Department of Physical &  
Rehabilitation Medicine, School of  
Medicine, Inha University, Incheon  
City, South Korea.

## Correspondence:

All correspondence and requests for  
reprints should be addressed to  
Han-Young Jung, MD, Department of  
Physical & Rehabilitation Medicine,  
Inha University Hospital, 7-206, 3Ga,  
Shinheung-Dong, Joong-Gu, Incheon  
City, 400-711, South Korea.

## Disclosures:

Financial disclosure statements have  
been obtained, and no conflicts of  
interest have been reported by the  
authors or by any individuals in control  
of the content of this article.

0894-9115/14/9303-0267  
*American Journal of Physical  
Medicine & Rehabilitation*  
Copyright © 2013 by Lippincott  
Williams & Wilkins

DOI: 10.1097/PHM.0b013e3182a92f2f

# Forgotten Denture in a Hemiplegic Patient

## ABSTRACT

Kim H-S, Kim C-H, Kim M-O, Joa K-L, Chung H, Jung H-Y: Forgotten denture in a hemiplegic patient. *Am J Phys Med Rehabil* 2014;93:267–271.

A 74-yr-old man developed left hemiplegia because of a right middle cerebral artery territory infarction and also had clinical features of dysphagia and speech difficulty. At that time, he complained of neck pain, but the symptom was ignored because he had a nasogastric tube and had been diagnosed with a huge epiglottic cyst that had already shown several symptoms such as severe hoarseness and throat discomfort. A videofluoroscopic swallowing study was planned to find out the cause and the type of dysphagia. On the videofluoroscopic swallowing study, a foreign body was found at the hypopharynx. Surprisingly, it was confirmed as a denture. After removing the denture, the patient's swallowing and speech difficulty were significantly improved. This case emphasizes the need for elderly stroke patients presenting with dysphagia or communication problems to receive more careful history taking and a more complete physical examination, with the cooperation of several clinical departments.

**Key Words:** Dysphagia, Stroke, Denture, Speech

Swallowing difficulty is a well known complication of stroke patients. Especially during the acute phase, the incidence rate of airway aspiration has been reported to range between 19% and 53%, and almost one-third of the cases were asymptomatic.<sup>1</sup> To prevent comorbidity and even mortality caused by dehydration or pneumonia associated with swallowing difficulty, it is important to assess the cause of swallowing difficulty and to start therapeutic intervention appropriately.

In stroke patients, most of the swallowing difficulty is caused by weakness or asynergia of the oral and pharyngeal musculature related to certain brain lesions. The authors report a very rare case of swallowing difficulty caused by dislodged dentures that had been aspirated and fixed unrevealingly in the hypopharynx.

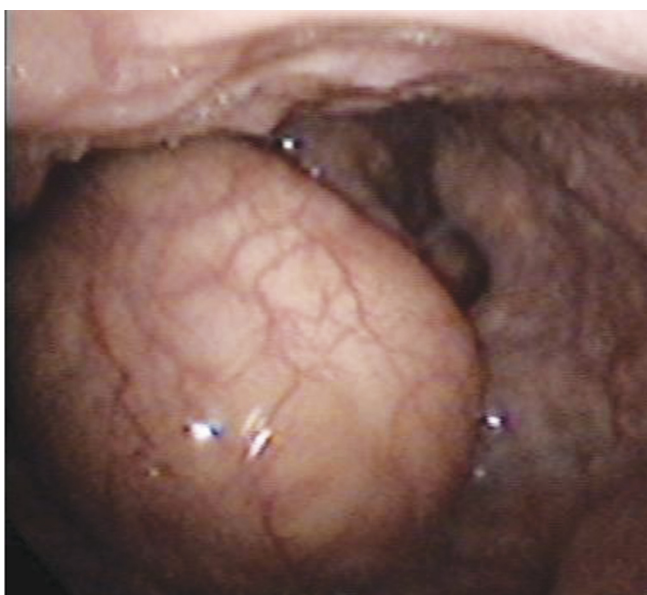In the elderly, the increasing use of dentures should raise the possibility of dentures themselves being the cause of swallowing difficulty, but this possibility is often overlooked. In addition, the belief that the patients' symptoms are purely a consequence of stroke could lead to a delay in the proper investigation and treatment of such patients.

In patients with cognitive dysfunction or aphasia, which hinders a precise history being taken from the patient, multilateral assessment, including a full physical examination and appropriate referral to otolaryngology or radiology, should be performed.

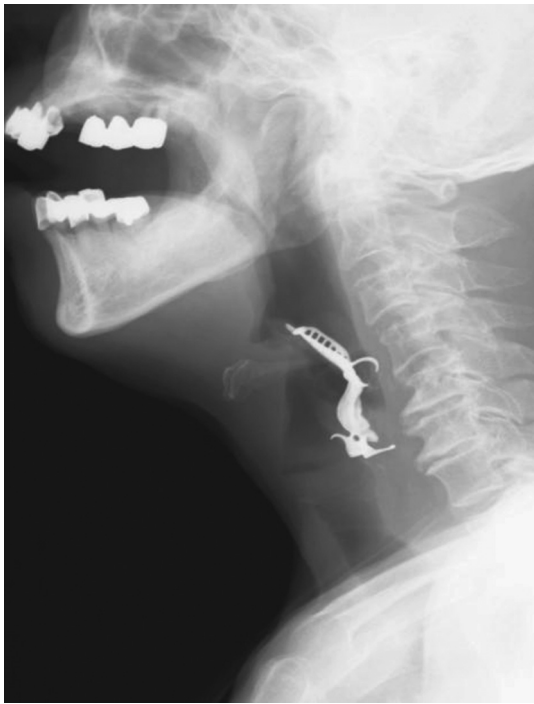## CASE DESCRIPTION

A 74-yr-old male patient admitted to the Department of Neurology complained of the sudden onset of left-sided motor weakness. A brain computed tomographic scan and magnetic resonance imaging were conducted in the emergency department. The magnetic resonance imaging of the brain revealed an acute infarction of the right frontal, parietal lobe, and insular cortex areas, which receive blood supply from the right middle cerebral artery. On a neurologic examination, he was found to have dysphagia and left-sided motor weakness. He received medications such as antiplatelet agents, and on hospital day 1, a nasogastric tube was inserted to prevent pulmonary aspiration. On the 28th hospital day, he was transferred to the Department of Physical and Rehabilitation Medicine to receive intensive rehabilitation for left hemiplegia and swallowing and speech difficulties. At the time of transfer from the Department of Neurology, he continued to be fed via a nasogastric tube because of the difficulty of swallowing. In addition, motor aphasia caused him to have difficulty in communicating verbally. He had an aphasia quotient of 13.0 (7th percentile) and a language quotient of 33.4 (63rd percentile) according to the initial evaluation of the Korean version of the Western Aphasia Battery.

He had diabetes mellitus and atrial fibrillation but no hypertension. One and a half years before this admission, he was diagnosed with an epiglottic cyst ( $2.7 \times 3.0 \times 2.3$  cm), and elective surgery to remove it had been planned (Fig. 1). He had no problem with communication, cognition, and feeding before his stroke. The cerebrovascular accident occurred 5 days before the surgery, and otorlaryngologic evaluation using video laryngoscopy was performed during the hospital stay. No sign of change in his cyst was recorded. After the transfer to the Department of Physical and Rehabilitation Medicine, a videofluoroscopic swallowing study was performed to assess the type and the cause of swallowing difficulty. On the lateral view, to the authors' amazement, a foreign body was found in the patient's lower pharynx, and the test was ceased immediately. A simple radiographic study of the patient's neck revealed a foreign body resembling a certain type of denture,  $3.6 \times 5.7$  cm in size, and a presumption was made that the foreign body was a swallowed denture (Fig. 2). The patient was referred to the Department of Gastroenterology to identify and remove this foreign body, and the foreign body was carefully removed using an endoscope (Fig. 3). It was revealed to be a denture (Fig. 4). After removal of the denture, the patient's swallowing difficulty dramatically improved, and the symptoms of aphasia disappeared; only mild dysarthria remained. The patient was reevaluated using the Korean version of the Western Aphasia Battery, and the results concluded an aphasia quotient of 86.8 (91st percentile) and a language quotient of 78.5 (96th percentile). He continued to receive



**FIGURE 1** *Fiberoptic endoscopic view of the epiglottic cyst ( $2.7 \times 3.0 \times 2.3$  cm).*



**FIGURE 2** Neck x-ray demonstrates radiopaque dental prosthesis in the hypopharynx.

rehabilitation for the left hemiplegia, and after discharge from the hospital, he continued to visit the outpatient department.

## DISCUSSION

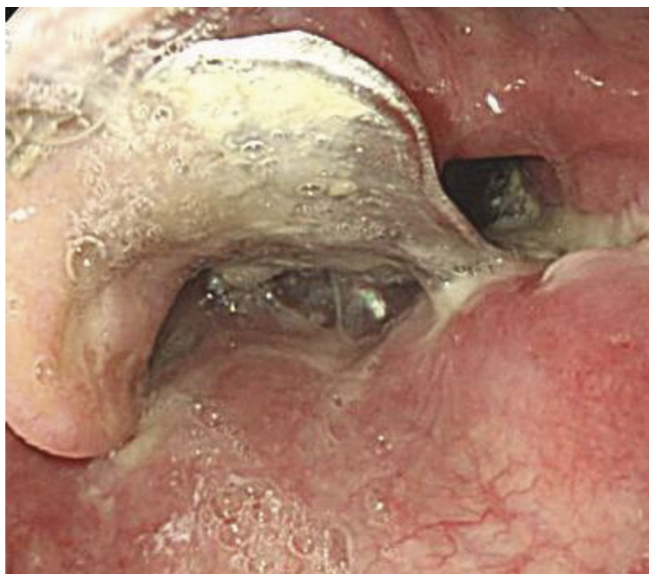Swallowing difficulty is a common complication in the acute phase of stroke, and the type of difficulty can be varied according to the location of the brain lesion.<sup>2,3</sup>

Cerebral lesions might disturb normal masticatory function and a voluntary control of bolus passage, and cortical lesions including the precentral area might result in declination of the contralateral lip and tongue movement, pharyngeal peristalsis, and delay of the swallowing reflex. Particularly, a lesion on the insular cortex, which plays a major role in the swallowing mechanism, causes swallowing difficulties.<sup>4</sup>

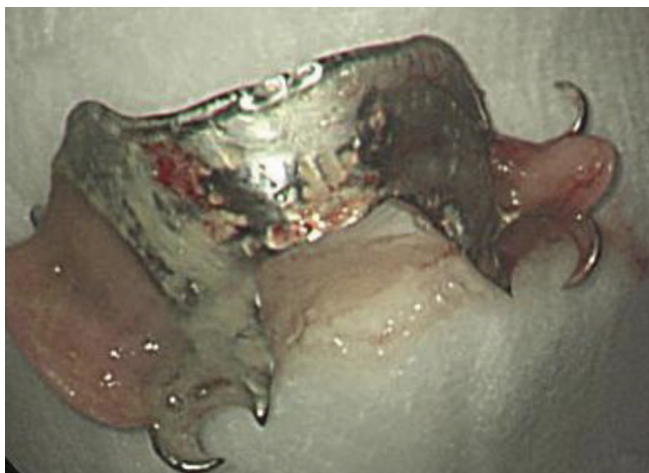
Brainstem lesions might play a lesser but still important role in causing swallowing difficulties. Lesions of the brainstem may affect sensation of the mouth and the lips and also affect the timing of pharyngeal swallowing, laryngeal elevation, and relaxation of the cricopharyngeal muscle.<sup>3</sup> In addition, lesions of the brain controlling cognitive function might adversely affect concentration and selective attention, thus damaging the swallowing procedure.

Aside from stroke, old age and history of prolonged oropharyngeal tube insertion contribute to swallowing difficulties.<sup>5</sup> Elderly patients tend to show a higher incidence of swallowing difficulty, and this might be caused by the overlapping effect of weakened muscle power of the masticatory musculature and the weakened pressure exerted by lip muscles.<sup>6</sup> An epidemiologic study<sup>7</sup> on the causes of swallowing difficulty showed an incidence rate of 16%–22% in patients older than 55 yrs. Thus, the study of swallowing difficulties must encompass multiple features, such as the location of the brain lesion and the patient's age.

However, as in this case, other etiologies besides the brain lesion itself, such as stricture, tumor, foreign bodies, and systemic illness such as Parkinson disease, must not be overlooked. Stroke



**FIGURE 3** Endoscopic examination reveals the dental prosthesis across the hypopharynx.



**FIGURE 4** *The dental prosthesis that was removed by endoscopy.*

is said to be the most common cause of swallowing difficulty, but 50% of patients who have Parkinson disease were also reported to have had swallowing difficulty. A total of 28% of patients who have rheumatoid arthritis and 20% of patients who have cerebral palsy were also reported to have had swallowing difficulty.<sup>7</sup>

The most frequently found foreign body in the oral cavity or the pharynx is dentures. Dentures used for a longer period might cause decreased sensitivity in the oral cavity and decreased control over oral and pharyngeal musculature; thus, using dentures should be regarded as a potential cause of dysphagia.<sup>6</sup>

When patients in the acute phase of stroke have dysphagia, cognitive deficit, and communication disorder, especially when they are using dentures, special care must be taken to investigate the possibility that the dentures themselves may be the cause of their symptoms. If foreign bodies such as dentures remain lodged in the pharynx or the esophagus, serious complications such as perforation or infection may arise, with the need for quick and swift intervention.<sup>8</sup>

The patient of this case had a planned surgical removal of the epiglottic cyst in the Department of Otolaryngology. Examinations were performed several times after admission, but these examinations failed to discover the aspirated denture, which was located below the cyst. In the emergency department, the initial brain computed tomographic scan showed that the patient's denture was in the right position. Therefore, the denture had been lodged after admission even though the exact time the denture was swallowed was undefined. The language disorder of the patient was classified as nonfluent aphasia on the initial evaluation of the Korean version of the Western Aphasia Battery, and

this was wrongly considered to be caused by brain damage of the right hemisphere.<sup>9</sup>

However, right brain damage associated with aphasia is rare. The language problem was much improved just after the removal of the denture. Therefore, a misdiagnosis was made of a swallowed denture with nonfluent aphasia.

As mentioned above, the denture that was lodged in the lower pharynx was found during the videofluoroscopic swallowing test. The denture was the most important factor causing the patient's symptoms, based on the fact that the removal of the denture made significant improvement in the patient's dysphagia and language disorder.

Other cases reporting dentures as a cause of dysphagia include displacement of the denture into the pharynx during an emergency endotracheal intubation,<sup>10</sup> a patient with dysphagia and dyspnea initially diagnosed as having a brainstem infarction was found to have dislocated dentures post mortem,<sup>11</sup> and hoarseness of the voice and mild dysphagia were found to be caused by dentures.<sup>12</sup> In addition, swallowing and respiratory difficulty in a patient with dementia were developed by a lodged denture in the hypopharynx.<sup>13</sup>

## CONCLUSIONS

This case emphasizes the importance of a precise history taking of denture use in elderly patients with stroke who have dysphagia, and in the cases of cognitive disorder and language disorder, a precise evaluation through otolaryngologic inspection must be performed.

## REFERENCES

1. Perry L, Love CP: Screening for dysphagia and aspiration in acute stroke. *Dysphagia* 2001;16:7-18

2. Barer DH: The natural history and functional consequences of dysphagia after hemispheric stroke. *J Neurol Neurosurg Psychiatry* 1989;52:236–41
3. Meng NH, Wang TG, Lien IN: Dysphagia in patients with brainstem stroke: Incidence and outcome. *Am J Phys Med Rehabil* 2000;79:170–5
4. Daniels SK, Foundas AL: The role of the insular cortex in dysphagia. *Dysphagia* 1997;12:146–56
5. Eslick GD, Talley NJ: Dysphagia: Epidemiology, risk factors and impact on quality of life—A population-based study. *Aliment Pharmacol Ther* 2008;27: 971–9
6. Martino R, Foley N, Bhogal S, et al: Dysphagia after stroke. *Stroke* 2005;36:2756–63
7. Kuhlemeier KV: Epidemiology and dysphagia. *Dysphagia* 1994;9:209–17
8. Rathore PK, Raj A, Sayal A, et al: Prolonged foreign body impaction in the oesophagus. *Singapore Med J* 2009;50:e53
9. Bramwell B: On “crossed” aphasia. *Lancet* 1899;1: 1473–9
10. Chin RY, Ellul S: Dysphagia after emergency intubation: Case report and literature review. *Dysphagia* 2009;24:105–8
11. Valori RM, Leclerc J: Impacted dentures mimicking brain stem stroke in a conscious patient. *BMJ* 1985;290: 1413–4
12. Von Haacke NP, Wilson JA: Missing denture as a cause of recurrent laryngeal nerve palsy. *BMJ* 1986;292:664
13. Peters TE, Racey GL, Nahman BJ: Dental prosthesis as an unsuspected foreign body. *Ann Emerg Med* 1984;13:60–2