

Terson syndrome in conjunction with ruptured intracranial aneurysm and penetrating intracranial injury: a review of two cases

Matt Rheinboldt · Kirenza Francis · David Parrish ·
Derrick Harper · John Blase

Received: 16 September 2013 / Accepted: 17 October 2013
© Am Soc Emergency Radiol 2013

Abstract Terson syndrome, the presence of intraocular hemorrhage in the setting of acutely elevated intracranial pressure, was historically described in conjunction with acute subarachnoid hemorrhage; however, more recently, it has been associated with a gamut of intracranial pathophysiology ranging from blunt or penetrating injury to neurosurgical procedures. We describe two cases of profound intracranial injury, secondary to ballistic injury, and a ruptured intracranial aneurysm, in which posterior chamber ocular hemorrhage was noted on CT imaging. Though the outcome in such cases, as with ours, is often poor, the findings are germane to clinical care as the presence of Terson syndrome has been noted to be a negative prognostic factor in multiple clinical reviews. Additionally, clinical recovery can be impacted adversely by lasting visual deficits or retinal degradation in the absence of timely ophthalmologic intervention.

Keywords Terson · Subarachnoid · Hemorrhage · Retina · Subhyaloid

Introduction

Easily overlooked in the acute setting, the presence of retinal or vitreous hemorrhage within the posterior chamber of the globe in conjunction with raised intracranial pressure, i.e., Terson syndrome, can have both important prognostic implications for morbidity and mortality as well as long-term ocular ramifications. Originally described in 1900 by Albert Terson as intraocular bleeding specifically occurring

in patients with acute subarachnoid hemorrhage, Terson syndrome varies widely in incidence in the literature, ranging from 2.6 to 27 % in patients status postintracranial aneurysm rupture [1–6]. The diagnosis is most accurately made with dedicated fundoscopic evaluation, though CT imaging can suggest the diagnosis as well in upwards of 66 % of patients in one series by demonstrating retinal thickening and hyperdense nodularity overlying the optic disk [7]. The ocular changes, though long debated in etiology in the literature, have come to be accepted as being secondary to the transmission of raised intracranial pressure via the subarachnoid space of the optic nerves, resulting in venous hypertension at the optic disk and secondary capillary rupture [8]. Terson hemorrhage, as might logically be expected, is more frequently found in those with greater acute neurological injury and a lower GCS score, typically 8 or below, at the time of presentation [1]. Additionally, in multiple clinical series, long-term morbidity and overall mortality rates have been shown to be significantly higher in those patients manifesting secondary ocular hemorrhage at the time of presentation [1, 5, 6]. Ophthalmologic management is usually initially conservative, though, due to the long-term risks of secondary glaucoma, retinal detachment, proliferative retinopathy, and cataracts, definitive surgical treatment with pars plana vitrectomy is often employed in those with persisting visual deficits lasting beyond 6 months [8].

Case report

Our first patient, a 37-year-old male, sustained a gunshot injury to the right temple area and was brought to the ER semiconscious, Glasgow Coma Scale 7, not following commands and with left-sided neglect. After initial stabilization and intubation, a CT was performed demonstrating a

M. Rheinboldt (✉) · K. Francis · D. Parrish · D. Harper · J. Blase
Department of Emergency Radiology, Henry Ford Hospital, Detroit,
MI, USA
e-mail: mrheinbold@yahoo.com

comminuted fracture of the right temporal, frontal, and parietal bones with numerous intracranial osseous and ballistic fragments, right frontoparietal swelling, and intraparenchymal subarachnoid and subdural hemorrhage (Fig. 1). In addition to the intracranial imaging findings, hemorrhage was observed involving the posterior chambers of both globes, overlying the area of the optic disk in a pattern suggesting subhyaloid dissection (Fig. 2). The patient's condition deteriorated overnight; following cardiopulmonary arrest and prolonged resuscitation efforts, a repeat head CT was performed, demonstrating worsening cerebral edema, increasing intra- and extra-axial hemorrhage, and transtentorial herniation. Additionally, worsening ocular hemorrhage was observed bilaterally (Fig. 3). Shortly, thereafter, despite all resuscitative efforts, the patient expired.

Our second patient, a 50-year-old female, had a prolonged medical history notable for hepatitis C-induced cirrhosis and hepatocellular carcinoma. Immediately prior to the terminal ictus event, she had undergone scheduled admission to the transplant service for radio-frequency ablation of the hepatic tumor. The procedure was uneventful and well tolerated. While recovering from the event on the ward, on postoperative day 1, the patient became abruptly nonresponsive and collapsed. Following resuscitation efforts, an emergent head CT demonstrated diffuse subarachnoid hemorrhage with intraventricular extension, generalized cerebral edema, and early hydrocephalus (Fig. 4). Additionally, a small focus of intraparenchymal hemorrhage was observed in the medial right temporal lobe adjacent to the anterior aspect of the right temporal horn, with a distribution and appearance favoring potential dissection from a rupture of posterior communicating aneurysm. Extracranial findings

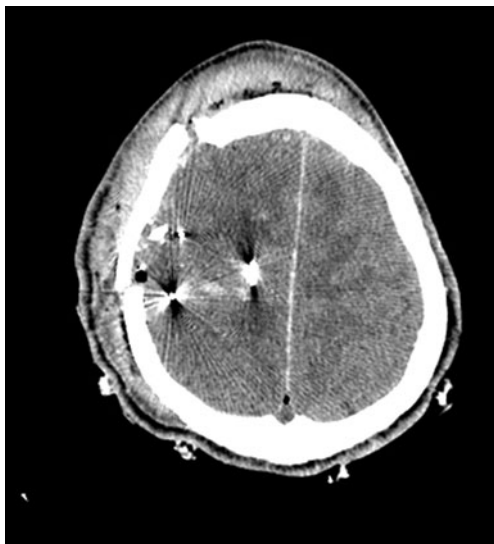

Fig. 1 Axial noncontrast CT image demonstrates numerous ballistic and bone fragments with accompanying intra- and extra-axial hemorrhage and edema at the level of the right frontal and parietal lobes. An overlying calvarial fracture and extensive scalp swelling is also noted

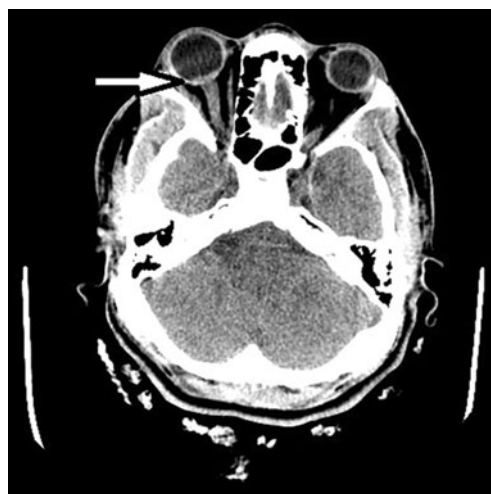

Fig. 2 Axial noncontrast CT image demonstrates faint linear hyperdensity at the level of the posterior chamber of the right globe compatible with Terson hemorrhage dissecting in a subhyaloid fashion over the optic disk. Similar changes were seen in the left globe (not shown)

were notable for bilateral subarachnoid extension of hemorrhage along the optic nerve sheaths, with subhyaloid posterior chamber hemorrhage compatible with accompanying Terson syndrome (Fig. 5). A CT angiogram of the head was attempted as well, though proved to be nondiagnostic, with stasis of contrast at the level of the distal extracranial carotid and vertebral vessels due to markedly elevated intracranial pressure, exceeding the cerebral perfusion pressure. Following the pronouncement of brain death and withdrawal of supportive measures, the patient expired shortly thereafter.

Discussion

With the now ubiquitous presence of helical CT and rapid multiplanar reconstructions in the trauma setting, such secondary findings as Terson hemorrhage in the context of acute intracranial injury are ever more manifest to the ER radiologist. As such, a judicious understanding of the relevancy and prognostic implication are certainly warranted.

Originally described as subhyaloid intraocular hemorrhage in conjunction with an acute subarachnoid bleed, Terson syndrome, as pathophysiological understanding evolved, has come to have an expanded definition of retinal or intravitreal hemorrhage in the setting of acutely raised intracranial pressure [1]. The largest clinical series have pertained chiefly to postaneurysm rupture patients, though the syndrome has also been described in conjunction with a variety of additional settings including acute infarct, moyamoya, trauma, venous sinus thrombosis, and iatrogenic procedures including angioplasty and third ventriculostomy [9–11]. The stated incidence varies in the literature from 2.6 to 27 %, with

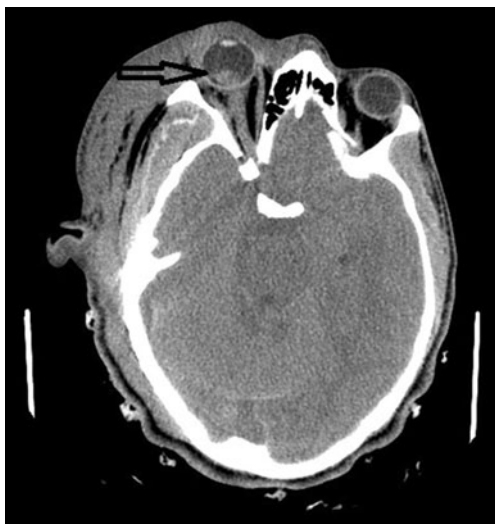

Fig. 3 Axial noncontrast CT image demonstrates worsening intraocular hemorrhage in conjunction with partially visualized worsening global cerebral edema and subarachnoid and subdural hemorrhage

bilaterality observed in 43–67 % of cases [1–6]. In a recent large prospective series from 2008, Fountas et al. found Terson hemorrhage in 12.1 % of their 174 postaneurysmal subarachnoid hemorrhage patients [1].

Though the gold standard for detection is fundoscopic exam, imaging is not insensitive. In a retrospective series of 12 patients diagnosed clinically with Terson syndrome, Swallow et al. found that CT imaging had a sensitivity rate of 66 % for the detection of hemorrhage [7]. Positive findings included hyperdense thickening and nodularity of the retinal surface overlying the optic disk. Remote differential diagnostic considerations as such would include melanoma or orbital metastases, though in the acute clinical setting, the

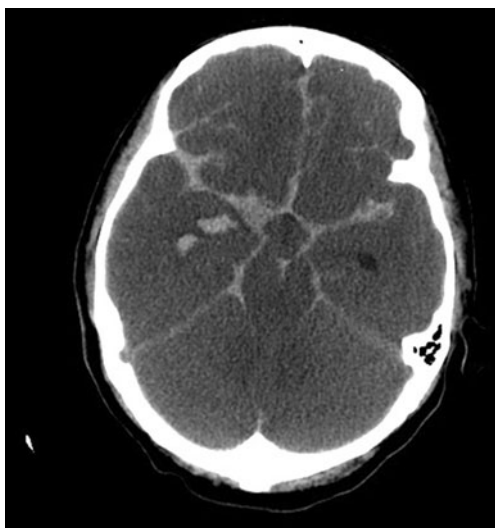

Fig. 4 Axial noncontrast CT image demonstrates diffuse subarachnoid hemorrhage in the basilar cisterns and overlying the frontal and temporal lobes, global cerebral edema and a small focus of intraparenchymal blood partially visualized at the level of the medial right temporal lobe

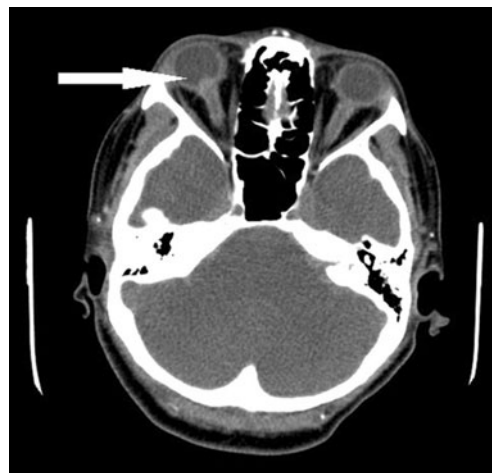


Fig. 5 Axial noncontrast CT image demonstrates bilateral thickening and hyperdensity of the optic nerve sheaths compatible with dissecting subarachnoid hemorrhage. There is also accompanying focal thickening and hyperdensity partially visualized at the level of the right optic nerve head compatible with overlying Terson hemorrhage

appearance is essentially pathognomonic. Expectedly, CT findings can be easily overlooked though secondary to motion or streak artifact. Given the rather limited use of MRI in the follow-up setting of hospitalized patients with acute intracranial injury, there was no reference found in the published literature, to expect ocular findings in Terson syndrome. Expectedly, signal changes on T1- and T2-weighted sequences at the subhyaloid level of the posterior chamber would vary based on internal hemorrhage age and paramagnetic influence. To date, there has been no large-scale investigation of the diagnostic accuracy of multidetector high-resolution CT imaging in Terson syndrome. In this regard, a prospective study correlating both CT and fundoscopic findings in patients enrolled initially based on Glasgow coma scale at the time of presentation rather than mechanism of injury would be of interest.

The most widely accepted rationale for the pathogenesis of the ocular hemorrhage is the hydrostatic transmission of raised intracranial pressure via cerebrospinal fluid or hemorrhage to the optic disk with secondary central retinal venous hypertension and hemorrhage at the retinal choroidal capillary anastomosis [8]. This was investigated in one elegant case report by Ogawa in 2001 in which fluorescein retinal angiography showed dye leakage at the optic disk margin corresponding to the demarcation zone of the inner-limiting membrane in a patient with Terson syndrome status posttherapeutic pars plana vitrectomy [8]. The extravasated blood may then, in turn, further dissect the membrane from the neurosensory retina or rupture into the vitreous.

As might be expected, Terson hemorrhage is significantly more common in patients presenting with more severe injury and greater initial neurological impairment. Specifically, Glasgow Coma Scale of <8, Fisher grade of >3, and Hunt Hess grade of >3 have shown to have a positive correlation in

multiple series [1, 6]. More importantly, both morbidity and mortality have been shown to be elevated in clinical reviews of Terson hemorrhage. In the series of Fountas et al., mortality was 28.6 % for those with ocular hemorrhage versus 2 % for those without [1]. Pfausler et al. [6] had an even greater discordance in their 1996 series, with 90 % of those with ocular bleeding eventually succumbing versus 23 % for those without. Clinical outcome in survivors, as measured using the Glasgow Outcome Scale, was also negatively affected at a statistically significant level in Fountas' series. This was supported in the 2012 series of Stienen et al. [2] assessing outcome in 60 patients with postaneurysmal subarachnoid hemorrhage. The mean GOS was 2.09 in survivors with Terson hemorrhage versus 3.53 in those without.

Initially, the management of Terson syndrome is typically conservative with most patients making a full visual recovery [1, 5]. However, because of the potential for proliferative retinopathy and/or detachment, glaucoma, and cataracts, surgical treatment with pars plana vitrectomy is usually performed in those with persistent impairment after 6 months [3].

In conclusion, Terson syndrome is an uncommon, though not rare complication of severe neurological injury. Given the prognostic implications for both morbidity and mortality as well as the potential for secondary ocular injury, the findings are of relevance both for the ER radiologist as well as for overall clinical patient care.

Conflict of interest The authors declare that they have no conflict of interest.

References

1. Fountas K, Kapsalaki E, Lee G, Machinis T, Grigorian A, Theodosiadis P (2008) Terson hemorrhage in patients suffering aneurysmal subarachnoid hemorrhage: predisposing factors and prognostic significance. *J Neurosurg* 109:439–444
2. Stienen M, Luecke S, Gautschi O, Harders A (2012) Terson hemorrhage in patients suffering aneurysmal subarachnoid hemorrhage: a prospective analysis of 60 consecutive patients. *Clin Neurol Neurosurg* 114:535–538
3. Frizell R, Kuhn F, Morris R, Quinn C, Fisher W (1997) Screening for ocular hemorrhage in patients with ruptured cerebral aneurysms: a prospective study of 99 patients. *Neurosurgery* 41:529–534
4. Garfinkle A, Danys I, Nicolle D, Colohan R, Brem S (1992) Terson's syndrome: a reversible cause of blindness following subarachnoid hemorrhage. *J Neurosurg* 76:766–771
5. Kuhn F, Morris R, Witherspoon C, Mester C (1998) Terson syndrome. Results of vitrectomy and the significance of vitreous hemorrhage in patients with subarachnoid hemorrhage. *Ophthalmology* 105:472–477
6. Pfausler B, Belcl R, Metzler R, Mohsenipour I, Schmutzhard E (1996) Terson's syndrome in spontaneous subarachnoid hemorrhage: a prospective study in 60 consecutive patients. *J Neurosurg* 85:392–394
7. Swallow C, Tsuruda J, Digre K, Glaser M, Davidson H, Harsberger H (1998) Terson syndrome: CT evaluation in 12 patients. *AJNR* 19:743–747
8. Ogawa T, Kitaoka T, Dake Y, Amemiya T (2001) Terson syndrome a case report suggesting the mechanism of vitreous hemorrhage. *Ophthalmology* 108:1654–1656
9. Takkar A, Kesav P, Gupta A (2013) Teaching neuroimages: Terson syndrome in cortical venous sinus thrombosis. *Neurology* 81(6):e40–e41
10. Kim H, Sung S, Seo E (2012) Terson syndrome caused by intraventricular hemorrhage associated with moyamoya disease. *J Korean Neurosurg Soc* 51(6):367–369
11. Hoving E, Rahmani M, Los L, Lavalette R (2009) Bilateral retinal hemorrhage after endoscopic third ventriculostomy: iatrogenic Terson syndrome. *J Neurosurg* 110:858–860