

Aphasia for Morse Code

ALLEN R. WYLER AND MORRIS W. RAY

*University of Tennessee Center for the Health Sciences and Semmes-Murphey Clinic,
Memphis, Tennessee*

The ability to communicate by Morse code at high speed has, to our knowledge, not been localized within the cerebral cortex, but might be suspected as residing within the left (dominant) hemisphere. We report a case of a 54-year-old male who suffered a left temporal tip intracerebral hematoma and who temporarily lost his ability to communicate in Morse code, but who was minimally aphasic.

© 1986 Academic Press, Inc.

INTRODUCTION

The ability to send and receive Morse code at relatively high speed is a complex perceptual as well as linguistic task. To send code at high speed using the iambic keying technique also requires a very precise motor-sequencing skill. (The iambic keying technique is one in which individual letters are formed by squeezing together two paddles held between the thumb and index finger, rather than tapping each letter on a manual key. The paddles control a solid-state circuit which generates dots and dashes at precise timing ratios.) To our knowledge, the areas of brain subserving this complex linguistic function have not been described. Therefore, we report a case of a patient who is an amateur radio operator who suffered a hemorrhage to the left anterior temporal lobe and who lost his abilities to send and receive code.

Case Report

The patient is a 54-year-old white male who fell onto his buttocks and hit his right forehead but did not sustain a loss of consciousness. Later that day, he developed a severe left frontal headache and vomited once. His wife noticed he had developed some hesitation in his normally fluent speech, but he was not grossly aphasic. He was taken to the hospital, and a CT scan was obtained which demonstrated a hemorrhagic contusion

Send correspondence to Allen R. Wyler, 920 Madison Avenue, Memphis, TN 38103.

of the left temporal tip (Fig. 1). An angiogram was negative for an arteriovenous malformation or aneurysm, and an EEG demonstrated only some delta activity in the left temporal region. A neurological examination demonstrated no neurologic deficit other than some slight hesitancy in his speech.

The subject is a licensed amateur radio operator as a hobby. The class of amateur license he holds requires proficiency with sending and receiving Morse code at a minimum speed of 21 words per minute, and he had held this license for 5 years prior to the injury. His main mode of amateur radio communication is with Morse code, and just prior to his injury he was routinely sending and receiving at 40 words per minute and was practicing daily by copying code from an electronic random character generator. Beginning with the second day after injury, he was tested with the random code generator and could copy no faster than 7 words per minute. His ability to send code was equally impaired. However, to objective speech testing, he was not grossly aphasic. Subjectively, he had some slowness finding appropriate words. He tested himself daily

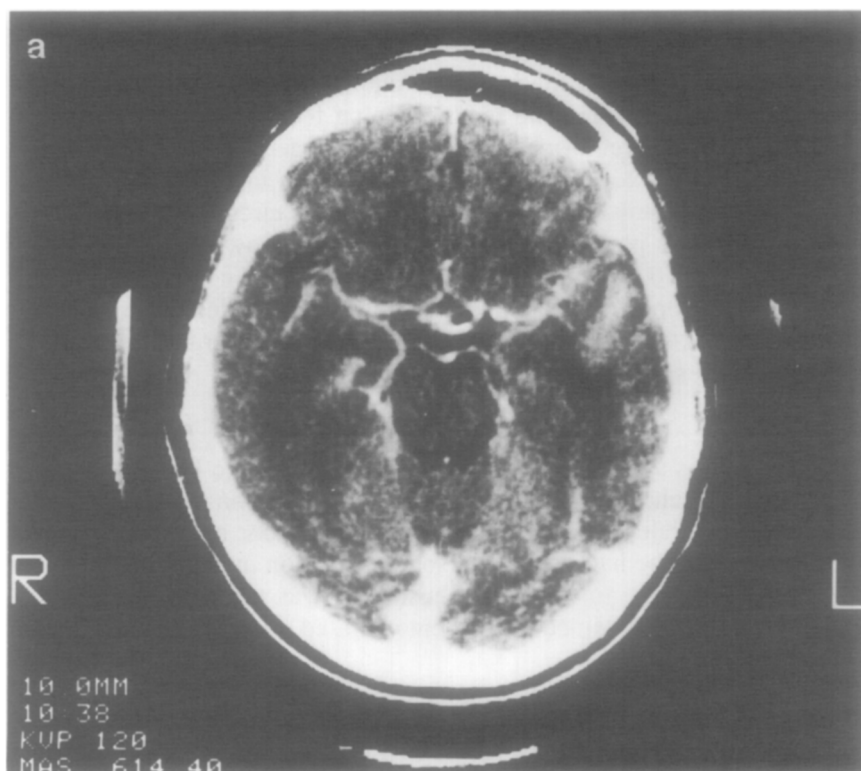
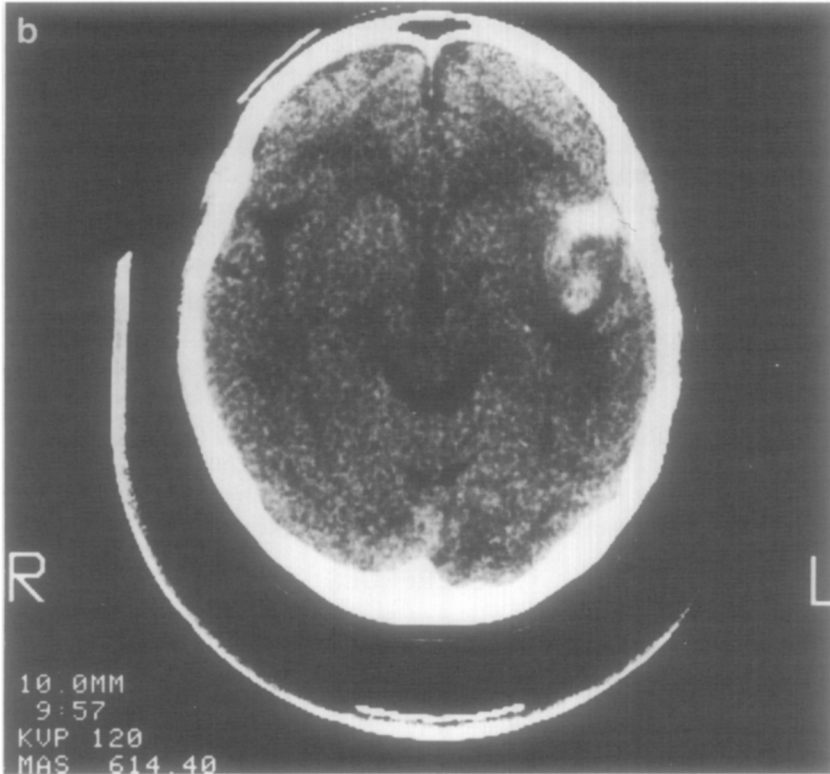


FIG. 1. CT scan demonstrating small hemorrhagic region of contusion within the anterior left temporal lobe.

FIGURE 1 — *Continued.*

with the code generator and recovered both sending and receiving back to 40 words per minute capability by 90 days after injury. During this time, he did not demonstrate any aphasia to cursory neurologic examinations.

DISCUSSION

This patient developed what may be viewed as an aphasia for both sending and receiving Morse code immediately following a hemorrhagic contusion to the anterior left temporal lobe. This loss was apparently more severe than his speech. To our knowledge, this particular deficit has not been described previously in the English language literature. That it should be associated with damage to the anterior portion of the dominant temporal lobe is not too surprising, if the following is considered. To receive Morse code at a speed of 40 wpm requires a high degree of auditory discrimination and ability to detect temporal sequences. When Morse code is sent at an average speed of 40 wpm of random text, the average letter or character is composed of three bits. Each bit can be a

dot or a dash, with the dash being at least three times the duration of the dot. The spacing between each character is longer than a dash. Thus, the average duration of each bit of information that must be discriminated is approximately 50 ms when either sending or receiving code at that speed. Efron (1963) and Sherwin and Efron (1980) have presented auditory evidence that temporal sequence is represented in the anterior temporal lobe of the dominant hemisphere.

An interesting observation in this patient is his ability to send code was equally as disrupted as his ability to receive it. No formal testing was done to determine whether this problem was due primarily to a decrement in his motor sequencing skills or secondary to a lack of precision in auditory feedback and perception. However, either situation could be the case, since it has been shown that lesions in the anterior temporal lobe may disrupt gestural communication (Mateer, Polen, Ojemann, & Wyler, 1982). This finding is also compatible with Ojemann's hypothesis that precise timing mechanisms may underlie a common speech perception and production area in the perisylvian cortex of the dominant hemisphere.

REFERENCES

- Ojemann, G. A., 1983. Brain organization for language from the perspective of electrical stimulation mapping. *The Behavioral and Brain Sciences*, **6**, 189-311.
- Efron, R. 1963. Temporal perception, aphasia and déjà vu. *Brain*, **86**, 403-424.
- Mateer, C. A., Polen, S. B., Ojemann, G. A., & Wyler, A. R. 1982. Cortical localization of finger spelling and oral language: A case study. *Brain and Language*, **17**, 46-57.
- Sherwin, I., & Efron, R. 1980. Temporal ordering deficits following anterior lobectomy. *Brain and Language*, **11**, 195-203.