

## Central Nervous System vasculitis associated with Hepatitis C virus infection: A brain MRI-supported diagnosis

A. Castro Caldas<sup>a,\*</sup>, R. Galdes<sup>a,b</sup>, L. Neto<sup>a,b</sup>, P. Canhão<sup>a,b</sup>, T.P. Melo<sup>a,b</sup>

<sup>a</sup> Department of Neurosciences, Stroke Unit, Hospital de Santa Maria, Portugal

<sup>b</sup> University of Lisbon, Lisbon, Portugal

### ARTICLE INFO

#### Article history:

Received 24 July 2013

Received in revised form 7 October 2013

Accepted 18 October 2013

Available online 27 October 2013

#### Keywords:

Stroke  
CNS vasculitis  
HCV infection  
Gadolinium MRI  
Gadolinium enhanced blood vessels  
Steroid treatment

### ABSTRACT

**Background:** The Hepatitis C virus (HCV) infection is associated with various extrahepatic manifestations, being the Central Nervous System (CNS) rarely involved.

**Case report:** We report a case of a 54 year-old black man with arterial hypertension who presented with progressively worsening headaches, apathy, somnolence and left hemiparesis. Brain MRI showed an acute ischemic lesion in the left anterior cerebral artery (ACA) and an old ischemic infarct in the right ACA territory. Brain MRI with gadolinium revealed mural thickening and contrast enhancement of the A1 and A2 segments of the ACAs, of the middle and distal basilar artery and of the P1 segment of the left posterior cerebral artery, suggesting active vasculitis. Digital angiography confirmed those irregularities and stenosis. Laboratory evaluation revealed ESR (73 mm/h), transaminase elevation, elevated HCV viral load genotype 2, positive IGRA, negative cryoglobulins, CSF protein elevation with oligoclonal bands (mirror pattern) and no pleocytosis; investigation excluded other infectious causes. Pegylated interferon alpha-2a and ribavirin, corticotherapy and tuberculosis prophylaxis were started with clinical and imagiological improvement.

**Conclusion:** The typical inflammation signs of the vascular wall demonstrated by the gadolinium-enhanced MRI strengthened the hypothesis of CNS vasculitis. The association with HCV infection is rare but should be investigated once specific therapeutic is required.

© 2013 Elsevier B.V. All rights reserved.

### 1. Background

Hepatitis C infection (HCV) is a common cause of liver disease with approximately 170 million people chronically infected worldwide [1]. Of these, 38–74% may have extrahepatic manifestations [2,3], where the CNS is rarely involved [4]. We report a case of CNS vasculitis at presentation of a HCV infection.

### 2. Case report

A 54-year-old hypertensive black man, born and resident in Guinea-Bissau, presented in November 2011 febrile syndrome followed by left hemiparesis. Over the following 7 months he referred progressively worsening holocranial headache of moderate intensity. In January 2012 he presented to our emergency department with malaise and headaches with worsening of motor defect. He was apathetic, somnolent with left spastic grade 4 hemiparesis. There were no skin or other systemic changes. Brain MRI revealed an acute ischemic lesion in the left anterior cerebral artery (ACA) and an old ischemic lesion in the right ACA territory (Fig. 1a, b), mural thickening and gadolinium

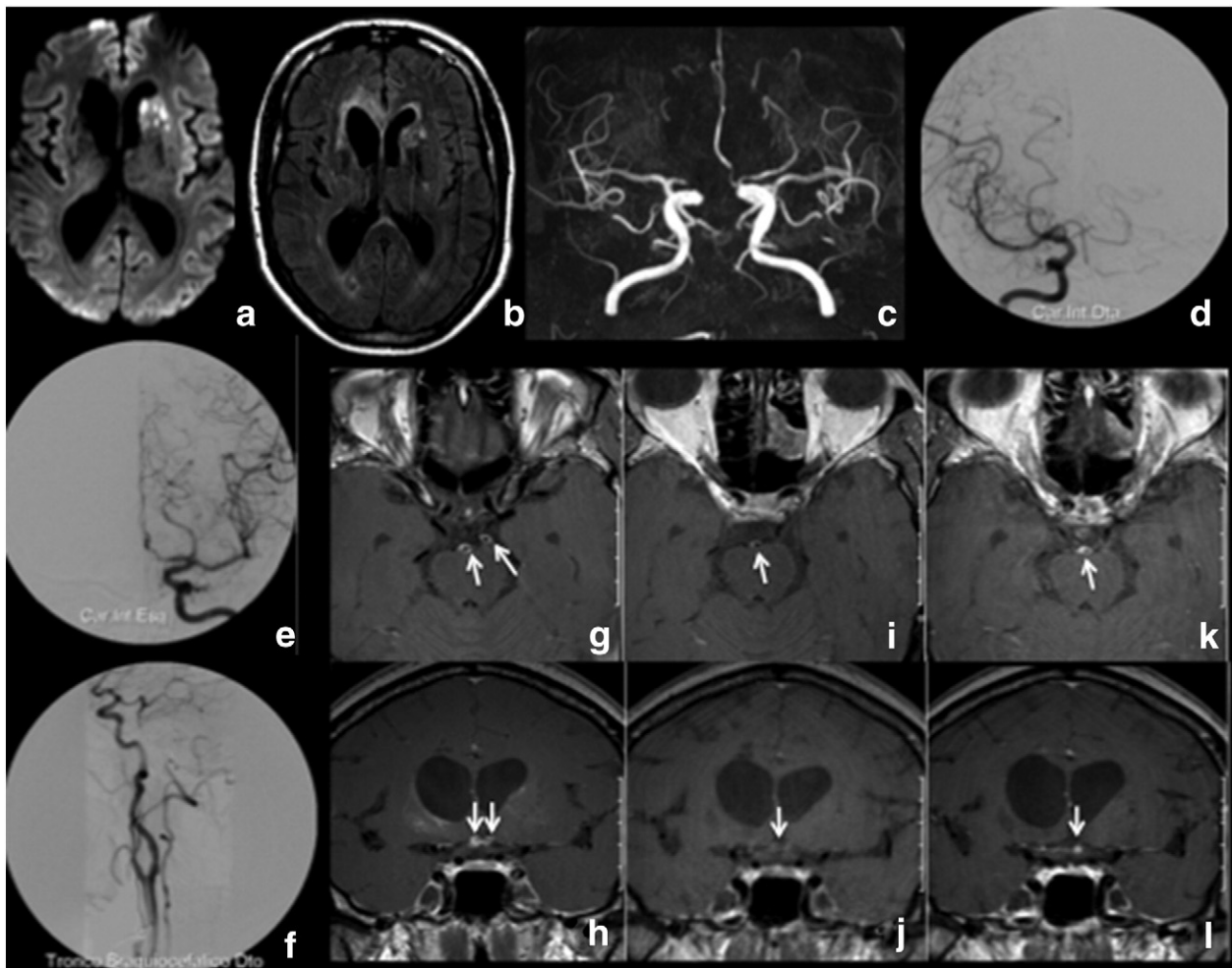
enhancement of both ACAs, basilar artery and left posterior cerebral artery (PCA) (Fig. 1g, h). Digital subtraction angiography (DSA) confirmed the described irregularities and stenosis (Fig. 1d, e, f). The cardiac evaluation was unremarkable.

Laboratory evaluation revealed elevated ESR of 73 mm/h, elevated transaminases, positive anti-HCV virus antibodies, high viral load of HCV genotype 2 in the serum, negative cryoglobulins, CSF proteins of 118 mg/dL, with mirror pattern oligoclonal bands and no pleocytosis. PCR for HCV and VZV of CSF were negative. Apart from a positive IGRA, other infections were excluded. Hepatic ultrasonography and fibroscan showed moderate hepatic fibrosis. There was no laboratorial evidence of renal involvement. Thoracoabdominopelvic CT scan was normal. Peripheral nerve neurophysiological tests were unremarkable.

At this point the diagnosis of CNS vasculitis associated with HCV infection was made. Pegylated interferon alpha-2a, ribavirin and high dose prednisolone were initiated together with tuberculosis prophylaxis. Brain-MRI was repeated 2 months later and showed less gadolinium enhancement in the affected arteries (Fig. 1i, j). During HCV treatment, corticotherapy was slowly tapered off with no new vascular events. An attempt to stop the corticotherapy at six months resulted in asymptomatic increased contrast enhancement in the affected arteries (Fig. 1k, l), suggesting persistent inflammatory activity, and so the patient was kept on 10 mg of prednisolone and was clinically stable after one-year of follow-up.

\* Corresponding author at: Department of Neurology, Hospital de Santa Maria, Av. Prof. Egas Moniz, 1649-035 Lisboa, Portugal. Tel.: +351 217 957 474.

E-mail address: [ana\\_palmela@msn.com](mailto:ana_palmela@msn.com) (A. Castro Caldas).



**Fig. 1.** CNS vasculitis in a patient with HCV infection. Brain MRI showed a left caudate nucleus and lenticulocapsular recent ischemic lesion in DWI (a); an old infarction in the right ACA territory, and other white matter changes were visible in FLAIR (b). Time of flight MR angiography revealed multiple intracranial stenosis in the proximal ACA, left ACP and basilar artery segments (c). Conventional cerebral angiography documented right ACA occlusion (d), critical stenosis at the left A1/A2 segment (e), and occlusion of the inferior 1/3 and of the distal segment of right vertebral artery (f), with retrograde filling of basilar artery through right posterior communicating artery (d). Gadolinium-MRI revealed mural thickening and contrast enhancement of the A1 and A2 segments of both ACAs, of the medial and distal segments of the basilar artery and of the P1 segment of the left posterior cerebral artery (g, h). After two months of treatment a new brain-MRI showed reduced enhancement in the affected arteries (i, j). After steroid reduction there was an asymptomatic increase in the contrast enhancement pattern (k, l).

### 3. Discussion

The association between HCV infection and CNS vasculitis is rare [4,5], especially in cryoglobulin-negative patients [5]. However, it may represent the first clinical manifestation of this infection [5,6]. The diagnosis of CNS vasculitis is difficult and in many cases cerebral biopsy is still required [7]. Progressive headaches, recurrent strokes, multiple cerebral artery stenosis, increased ESR and increased CSF proteins (including oligoclonal IgG) with no pleocytosis support the diagnosis of cerebral vasculitis. A recent study suggests that contrast-enhanced T1-weighted images of the affected arteries may be the most sensitive test to detect a vasculitic process of large vessels [9]. Accordingly, brain-MRI may not only show indirect imaging signs of vasculitis, such as multiple ischemic lesions and multiple vascular stenosis, but also direct signs of mural inflammation [9]. Since the patient was hypertensive, cerebral vascular stenosis could be attributed to atherosclerosis, in which intraplaque heterogeneous intensity and enhancement [10] could occur. Nevertheless he showed contrast enhancement in virtually the entire wall of the stenotic vessel, suggesting a vasculitic process. These signs were observed in our patient and strengthened the hypothesis of CNS vasculitis. In our case, CNS vasculitis was associated with HCV infection. Although in some cases HCV neuroinvasion and replication is demonstrated [8], our patient had negative HCV PCR in CSF. However there is scarce information regarding the sensitivity of RNA HCV sequence detection in the

CSF [8]. Positive oligoclonal bands with mirror pattern suggest a systemic process with neurological involvement, and in our patient the autoimmune reaction seems the most probable scenario. Cerebral vasculitis was the single extrahepatic HCV virus infection manifestation in our case.

Gadolinium brain MRI proved to be very useful in follow-up, not only because the decrease of gadolinium enhancement in the affected arteries after corticotherapy supported the diagnosis of cerebral vasculitis, but also it revealed asymptomatic increase of inflammatory activity that led to a change in therapy, perhaps preventing symptomatic disease reactivation.

This case supports that HCV infection should be excluded in cases of CNS vasculitis [5], since specific therapy is required eventually leading to an improvement of prognosis [5,11].

### Conflict of Interest

The authors report no conflicts of interest.

### References

- [1] World Health Organization. Hepatitis C. Fact sheet N°164. [www.who.int](http://www.who.int); July 2012.
- [2] Cacoub P, Poynard T, Ghillani P, Charlotte F, Olivi M, Piette JC, et al. Extrahepatic manifestations of chronic hepatitis C. MULTIVIRC Group. Multidepartment virus C. *Arthritis Rheum* Oct 1999;42(10):2204–12.

- [3] Cacoub P, Renou C, Rosenthal E, Cohen P, Louri I, Loustaud-Ratti V, et al. Extrahepatic manifestations associated with hepatitis C virus infection. A prospective multicenter study of 321 patients. The GERMIVIC. *Medicine (Baltimore)* Jan 2000;79(1):47–56.
- [4] Cacoub P, Saadoun D, Limal N, Léger JM, Maisonnobe T. Hepatitis C virus infection and mixed cryoglobulinaemia vasculitis: a review of neurological complications. *AIDS* Oct 2005;19(Suppl. 3):S128–34.
- [5] Carvalho-Filho RJ, Narciso-Schiavon JL, Tolentino LH, Schiavon LL, Ferraz ML, Silva AE. Central nervous system vasculitis and polyneuropathy as first manifestations of hepatitis C. *World J Gastroenterol* Jan 14 2012;18(2):188–91. <http://dx.doi.org/10.3748/wjg.v18.i2.188>.
- [6] Acharya JN, Pacheco VH. Neurologic complications of hepatitis C. *Neurologist* May 2008;14(3):151–6. <http://dx.doi.org/10.1097/NRL.0b013e31815fa594>.
- [7] Scolding NJ, Wilson H, Hohlfeld R, Polman C, Leite MI, Gilhus NE. Cerebral Vasculitis, in *European Handbook of Neurological Management, Second Edition, Second Edition, Volume 1*. Oxford, UK: Wiley-Blackwell; 2011. <http://dx.doi.org/10.1002/9781444328394.ch35>.
- [8] Laskus T, Radkowski M, Bednarska A, Wilkinson J, Adair D, Nowicki M, et al. Detection and analysis of hepatitis C virus sequences in cerebrospinal fluid. *J Virol* Oct 2002;76(19):10064–8.
- [9] Küker W. Cerebral vasculitis: imaging signs revisited. *Neuroradiology* Jun 2007;49(6):471–9.
- [10] Kim JM, Jung KH, Sohn CH, Moon J, Han MH, Roh JK. Middle cerebral artery plaque and prediction of the infarction pattern. *Arch Neurol* Nov 2012;69(11):1470–5.
- [11] Tembl JI, Ferrer JM, Sevilla MT, Lago A, Mayordomo F, Vilchez JJ. Neurologic complications associated with hepatitis C virus infection. *Neurology* Sep 11 1999;53(4):861–4.