

## Case report

## Concurrent asymptomatic inflammatory aneurysm and ischemic stroke due to cysticercal arteritis



Antonio Arauz<sup>a</sup>, Francisco Ruiz-Navarro<sup>a</sup>, Humberto Silos<sup>a</sup>,  
 Juan Camilo Vargas-González<sup>a,\*</sup>, Nayelli Arguelles-Morales<sup>a</sup>, Marisela Reyes<sup>a</sup>,  
 Angélica Ruiz-Franco<sup>a</sup>, Aleyda Rivera<sup>a</sup>, Agnes Fleury<sup>b</sup>

<sup>a</sup> Stroke Clinic, National Institute of Neurology and Neurosurgery, México City, Mexico

<sup>b</sup> Biomedical Research Institute, National Institute of Neurology and Neurosurgery, México City, Mexico

### ARTICLE INFO

#### Article history:

Received 2 August 2013

Received in revised form 24 August 2013

Accepted 2 October 2013

Available online 24 October 2013

#### Keywords:

Carotid artery aneurysm

Neurocysticercosis

Stroke

Brain cysticercosis

Case report

## 1. Introduction

Neurocysticercosis (NCC) is recognized as an important public health problem in developing countries. Cysticercal arteritis (CA) may cause endothelial disruption, edema, thrombosis, and the formation of fusiform aneurysms due to a weakening of the vessel walls [1]. Here, we report a case with concurrent asymptomatic internal carotid artery (ICA) inflammatory aneurysm and contralateral ischemic stroke due to CA.

## 2. Case report

A 39-year-old female was admitted with intracranial hypertension (ICH). She denied risk factors and alcohol, tobacco or narcotics use. Fundoscopy revealed bilateral papilledema without focal signs. Brain magnetic resonance imaging (MRI) revealed multiple cystic lesions with associated nodular lesions. The cerebrospinal fluid (CSF) was inflammatory (glucose 3 mg/dl, protein 154 mg/dl, and 496 cells/mm<sup>3</sup>), and the immune response to neurocysticercosis

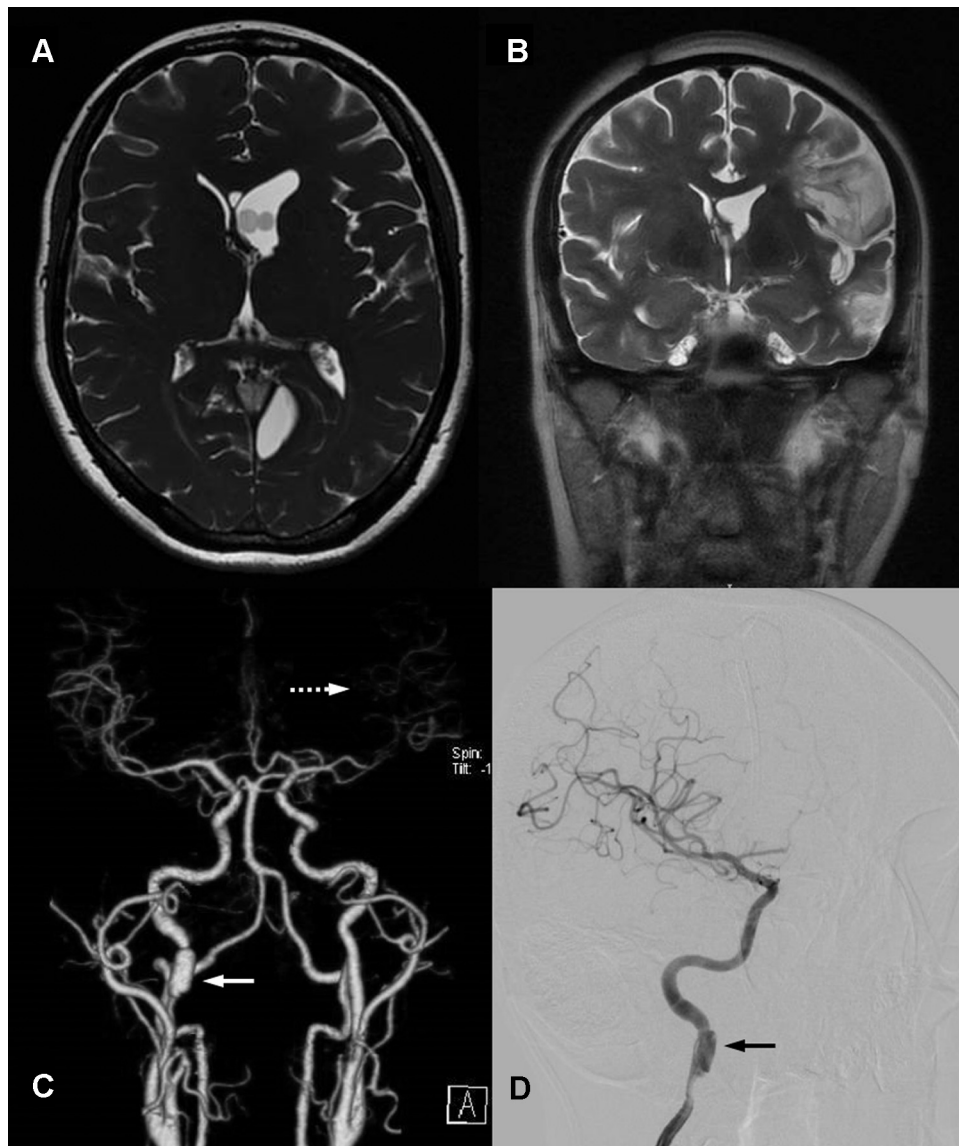
(NCC) was positive. The patient demonstrated a good response when treated with albendazol and intravenous dexamethasone. The control CSF, assessed 2 weeks later, was normal and remained asymptomatic for 2 years. The patient then developed ICH symptoms. An MRI showed basal cistern cysts and hydrocephalus, which required a ventricular shunt and albendazol treatment. Control follow-up CSF analyses confirmed persistent inflammatory meningitis (glucose 35 mg/dl, protein 367 mg/dl, and 35 cells/mm<sup>3</sup>). The patient was then switched to praziquantel and presented a favorable outcome.

Five years later, the patient presented right hemiparesis and non-fluent aphasia. A left temporo-parietal infarct was found using MRI. In addition, computed tomography angiography (CTA) revealed a fusiform aneurysm (Fig. 1) in the right ICA and decreased blood flow in the left medial cerebral artery. Digital subtraction angiography (DSA) confirmed these findings. The results obtained using transcranial Doppler sonography were consistent with CA, which showed increased velocities in all intracranial vessels, particularly in the left medial cerebral artery. The CSF was inflamed again (glucose 35 mg/dl, protein 124 mg/dl and 15 cells/mm<sup>3</sup>) with a positive immune response to NCC. The patient's routine blood laboratory, echocardiogram, rheumatologic and prothrombotic profiles were normal.

The patient received a new cycle of dexamethasone and albendazol. At her 6-month follow-up, she showed an improvement in

\* Corresponding author at: Stroke Clinic, National Institute of Neurology and Neurosurgery, Manuel Velasco Suárez, Insurgentes Sur 3877 La Fama, cp 14269 México, Distrito Federal, Mexico. Tel.: +52 15514885615.

E-mail address: [juanvargax@gmail.com](mailto:juanvargax@gmail.com) (J.C. Vargas-González).



**Fig. 1.** (A) MRI fast imaging employing steady state acquisition (FIESTA) axial image showing intra-ventricular cystic lesions with ipsilateral ventricular dilatation. (B) MRI T2W coronal image displaying a left side temporo-parietal infarction. (C) Computer tomography angiography shows decrease blood flow through LMCA (dotted arrow) and contralateral ICA aneurysm (white arrow). (D) Digital subtraction angiography confirmation of right ICA aneurysm (black arrow).

her deficits, with a modified Rankin score of 1. The control CTA showed a persistent right ICA aneurysm without enlargement.

### 3. Discussion

Cerebrovascular disease is a relatively common but under-recognized complication of NCC; previous studies have indicated that the incidence of stroke is between 4% and 12% in patients with NCC [2]. Cysticerci within the subarachnoid space induced an inflammatory process, which resulted in endarteritis with the infiltration of lymphocytes, plasma cells, and eosinophils as well as thrombosis of the cerebral arterial vessels. This process may result in the disruption of the arterial wall layers and induce the formation of an aneurysmal dilatation [3]. Our patient presented with chronic recurrent NCC meningitis, CA, concurrent left medial cerebral artery infarction and contralateral asymptomatic inflammatory aneurysm of the ICA. Other cases of an inflammatory aneurysm related to NCC have been reported, most of which were located at the distal intracranial arteries. These

inflammatory aneurysms were commonly fusiform and were accompanied with hemorrhage as an initial manifestation [4]. Despite being symptomatic, not all of the patient cases underwent clipping or embolization, but the patients were given medical treatment.

The treatment of infectious inflammatory aneurysms (IIA) differs from that of congenital aneurysms. The wall of IIA and the parent vessel are fragile, and the possibility of intraoperative rupture is high. Because these IIAs are fusiform, the aneurysm is difficult to clip or coil while still preserving the parent artery. In a recent review [5], antibiotic therapy alone was the preferred treatment in patients with an unruptured aneurysm and with a high technical risk for interventions. Up to 36% of patients with IIA received only antibiotics with an overall good outcome observed in 62% of the patients, independent of treatment group [5]. However, due to the low frequency of such cases, the decision to perform medical therapy alone or an intervention to exclude the aneurysm should be considered on a case by case basis and must consider the morphology of the lesion as well as the severity of sacrificing

the parent vessel. Finally, there is a consensus that patients with IIA should be followed up with angiography (DSA, CTA or MRI) to ensure that the aneurysmal diameter does not increase and the absence of new aneurysms; however, the frequency of monitoring remains controversial.

Although we cannot rule out a congenital aneurysm, its location, the presence of chronic meningitis and the evidence of CA suggest an inflammatory origin. The present case demonstrated that the cerebrovascular complications of NCC were nonspecific. Moreover, diffuse NCC and chronic cysticercosis meningitis are predisposed to multiple vessel involvement, including arteritis of the major intracranial arteries and inflammatory aneurysm [1].

#### 4. Conclusion

The present case illustrates the variability of the clinical manifestations of CA and the potential for the simultaneous presence of more than one type of cerebrovascular disease.

#### Conflicts of interest

None to declare.

#### References

- [1] Marquez JM, Arauz A. Cerebrovascular complications of neurocysticercosis. *Neurologist* 2012;18:17–22.
- [2] Alarcon F, Vanormelingen K, Moncayo J, Vinan I. Cerebral cysticercosis as a risk factor for stroke in young and middle-aged people. *Stroke: A Journal of Cerebral Circulation* 1992;23:1563–5.
- [3] Kim IY, Kim TS, Lee JH, Lee MC, Lee JK, Jung S. Inflammatory aneurysm due to neurocysticercosis. *Journal of Clinical Neuroscience: Official Journal of the Neurosurgical Society of Australasia* 2005;12:585–8.
- [4] Cardenas G, Guevara-Silva E, Fleury A, Sciutto E, Luis Soto-Hernandez J. Subarachnoid hemorrhage in neurocysticercosis: a direct or serendipitous association. *Neurologist* 2012;18:324–8.
- [5] Ducruet AF, Hickman ZL, Zacharia BE, Narula R, Grobelny BT, Gorski J, et al. Intracranial infectious aneurysms: a comprehensive review. *Neurosurgical Review* 2010;33:37–46.