

## CASE REPORT

## Acquired stuttering due to recurrent anaplastic astrocytoma

Katherine B Peters,<sup>1</sup> Scott Turner<sup>2</sup><sup>1</sup>Departments of Neurology and Surgery, Duke University Medical Center, Durham, North Carolina, USA<sup>2</sup>Department of Neurosurgery, Geisinger Medical Center, Danville, Pennsylvania, USA**Correspondence to**Dr Katherine B Peters,  
katherine.peters@duke.edu**SUMMARY**

Acquired (neurogenic) stuttering is a rare phenomenon seen after cerebral infarction or brain injury. Aetiology of this symptom is unclear, but recent evidence supports that it is a disturbance in the left hemispheric neural network involving the interplay between the cortex and basal ganglia. We present the case of a patient who develops acquired stuttering after a recurrence of a right temporoparietal anaplastic astrocytoma (WHO grade III). We also review other cases of acquired stuttering and known anatomical correlates.

**BACKGROUND**

Stuttering is a disruption of verbal fluency with involuntary repetition or prolongation of sounds or syllables. There may be silent or audible pauses which can be accompanied by anxiety or secondary motor symptoms such as facial grimacing. Stuttering is not a diagnosis, but a symptom, the exact aetiologies of which are unclear. To better understand this condition, stuttering has been categorised as developmental or neurogenic depending on its onset and characteristics.

Developmental stuttering typically presents before puberty, often as early as 2–5 years of age with a male predominance and without apparent neurological injury. The incidence of developmental stuttering is approximately 5% with an estimated overall recovery rate of 74%, leading to a prevalence of 1% in adults.<sup>1</sup> Developmental stuttering tends to be more common at the beginning of words and is usually associated with secondary symptoms. Developmental stuttering exhibits both adaptation, (it occurs less frequently with repeated attempts) and consistency (it occurs with the same words or syllables).<sup>2</sup>

Neurogenic or acquired stuttering is much less common and occurs following known brain injury. It may exhibit a slow onset when associated with degenerative diseases such as Parkinson's disease or it may appear suddenly following stroke or trauma. Stuttering has also been associated with certain medications, including tricyclic antidepressants and phenothiazines.<sup>3–7</sup> Helm *et al*<sup>8</sup> described five characteristics of neurogenic stuttering that distinguish it from developmental stuttering: (1) lack of adaptation; (2) repetitions, prolongations and blocks are not restricted to initial syllables; (3) stuttering occurs on small grammatical words as well as substantive words; (4) absence of anxiety; and (5) rarely occurs with secondary motor symptoms such as facial grimacing.

Although rare, acquired stuttering has been reported in the setting of acute stroke in a number of patients (table 1). Infarcts in all lobes and in dominant as well as non-dominant hemispheres have been described.<sup>8–17</sup> Though the mechanism remains unclear, stuttering has been attributed to lesions in the supplementary motor area, pons, putamen, the left and right parietal lobes, the thalamus and the corpus callosum.<sup>18–21</sup> Using voxel-based lesion-symptom correlates, Theys *et al*<sup>22</sup> showed that acquired stuttering from infarcts is not due to one specific lesion but rather a dysfunction in the left-sided neural network compromised of the cortex-basal ganglia-cortex.

Infarcts as well as tumours have been used through the years to map important regions of the brain in order to understand better the mechanisms of speech and language. There have been several reports of infarcts leading to stuttering and here, we present a first case report of recurrent anaplastic astrocytoma leading to acquired stuttering which correlated temporally with the tumour's extension into the right parietal lobe and across the corpus callosum.

**CASE PRESENTATION**

A patient with a history of hypertension was evaluated for a left visual field deficit. This was the only abnormality detected on the patient's neurological examination at the time of MRI. MRI with and without gadolinium revealed a diffusely abnormal signal involving the right temporoparietal region. A stereotactic biopsy confirmed the diagnosis of anaplastic astrocytoma (WHO grade III) and he received 5940 cGy of radiation therapy along with concurrent oral temozolomide. After combined treatment, MRI was read as stable disease and the patient then received two cycles of adjuvant temozolomide dosed at 150 mg/m<sup>2</sup> for 5 days in 28-day cycle.

After the completion of two cycles of 5-day temozolomide, the patient presented to the Preston Robert Tisch Brain Tumour Center at Duke with a worsening left visual field deficit and new onset of intermittent stuttering. An MRI at that time showed progressive disease consisting of a diffusely enhancing mass involving the right splenium of the corpus callosum, which extended to the left side and into the right temporal lobe, basal ganglia and occipital lobe (figure 1). The patient was then started on irinotecan in combination with bevacizumab. On neurological examination, the patient was alert and oriented to person, place and time. The patient scored a 28/30 on the Mini-Mental State Examination and only missed points for interlocking pentagon task and lack of recall of one memory



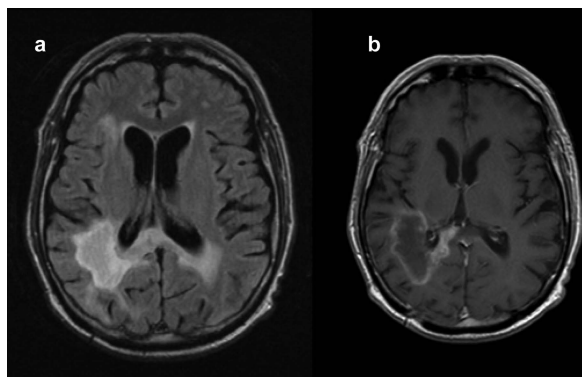
CrossMark

**To cite:** Peters KB, Turner S. *BMJ Case Rep* Published online: [please include Day Month Year] doi:10.1136/bcr-2013-009562

**Table 1** Reports on acquired stuttering associated with neurological injury

Reference	Age (years)	Handedness	Gender		Lesion
Fleet and Heilman <sup>13</sup>	42	Right	Female	Cerebral infarction	Right frontoparietal
Ardila and Lopez <sup>10</sup>	50	Right	Male	Cerebral Infarction	Right temporal
Soroker <i>et al</i> <sup>17</sup>	65	Right	Male	Cerebral infarction	Right hemisphere, post capsule/putamen
Abe <i>et al</i> <sup>18</sup>	38	Not Reported	Male	Cerebral infarction	Paramedian thalami and midbrain
Kono <i>et al</i> <sup>23</sup>	54	Not Reported	Male	Cerebral infarction	Left basal ganglia
Grant <i>et al</i> <sup>14</sup>	68	Right	Male	Cerebral infarction	Left frontotemporal
Grant <i>et al</i> <sup>14</sup>	59	Right	Male	Cerebral infarction	Left posterior temporal/bilateral cerebellum
Grant <i>et al</i> <sup>14</sup>	59	Ambidextrous	Male	Cerebral infarction	Right parietal
Grant <i>et al</i> <sup>14</sup>	55	Right	Male	Cerebral infarction	Left medial occipital
Tsumoto <i>et al</i> <sup>24</sup>	66	Right	Male	Cerebral infarction	Corpus callosum: body, splenium
Ciabarra <i>et al</i> <sup>25</sup>	53	Right	Male	Cerebral infarction	Left rostromedial pons
Ciabarra <i>et al</i> <sup>25</sup>	54	Right	Female	Cerebral infarction	Left putamen, caudate, corona radiata
Ciabarra <i>et al</i> <sup>25</sup>	63	Left	Female	Cerebral infarction	Left corona radiata and left lateral putamen
Hagiwara <i>et al</i> <sup>26</sup>	52	Right	Male	Cerebral infarction	Corpus callosum: body, splenium
Turgut <i>et al</i> <sup>27</sup>	61	Right	Male	Cerebral infarction	Left parietal
Doi <i>et al</i> <sup>28</sup>	60	Not Reported	Male	Cerebral infarction	Midbrain, upper pons
Kakishita <i>et al</i> <sup>19</sup>	51	Right	Male	Cerebral infarction	Corpus callosum: genu, anterior body
Fawcett <sup>12</sup>	84	Left	Female	Cerebral infarction	Left basal ganglia
Hamano <i>et al</i> <sup>29</sup>	77	Right	Female	Cerebral infarction	Corpus callosum: body
Sahin <i>et al</i> <sup>30</sup>	65	Right	Female	Cerebral infarction	Left parietal-supramarginal gyrus, angular gyrus
Sahin <i>et al</i> <sup>30</sup>	95	Right	Male	Cerebral infarction	Left supramarginal gyrus
Osawa <i>et al</i> <sup>31</sup>	51	Right	Male	Cerebral infarction	Left parietal, occipital, and temporal
Tani and Sakai <sup>32</sup>	45	Right	Male	Cerebral infarction	Right cerebellum
Tani and Sakai <sup>33</sup>	49	Ambidextrous	Male	Brain haemorrhage	Left putamen
Tani and Sakai <sup>33</sup>	16	Right	Male	Traumatic brain injury	Right pons, right and left putamen
Tani and Sakai <sup>33</sup>	50	Right	Male	Cerebral infarction	Bilateral basal ganglia and left pons
Tani and Sakai <sup>33</sup>	8	Right	Female	Brain haemorrhage due to arteriovenous malformation	Left parietal
Tani and Sakai <sup>33</sup>	77	Right	Male	Cerebral infarction	Bilateral putamen

word. The patient did admit to mild prosopagnosia. On speech evaluation, the patient had evidence of stuttering. Repetition, comprehension and naming were all normal and intact. As for fluency, the patient could form sentences appropriately but would stutter over multiple words. The patient continued to have a left homonymous hemianopsia. Motor strength was normal. The patient was hyperreflexic on the left side with 3+. There was a mild reduction of temperature sensation in the left upper and left lower extremities in comparison to the right side. The patient's gait was mildly unsteady because the patient had difficulty in looking to the left per the patient. A general physical examination was unremarkable.



**Figure 1** Fluid-attenuated inversion recovery (A) and T1 with gadolinium (B) showing involvement of the right parietal lobe and splenium of the corpus callosum.

**OUTCOME AND FOLLOW-UP**

Throughout the patient's treatment course, the patient continued to experience stuttering. After completing 2 years of treatment on bevacizumab-containing regimens, the patient passed away in hospice.

**DISCUSSION**

Although stuttering has been described for centuries, its underlying causes remain unclear. On average, children who stutter exhibit slightly delayed speech development and have a slightly higher than average incidence of behavioural disorders, suggesting a possible cognitive component,<sup>34</sup> though results are not conclusive. Studies linking stuttering to dystonic contractions of muscles that affect speech have not been borne out, but the fact that antidopaminergic agents such as haloperidol, olanzapine and risperidone have proven helpful in treating stuttering suggest an overactivity of dopaminergic neurons, possibly in the basal ganglia, may play a role.<sup>4</sup>

Neuroimaging and electroencephalography analysis have not demonstrated a single area of abnormality in the brains of stutterers, but functional neuroimaging has demonstrated hyperactivity in the right hemisphere in stutterers as well as a problem with coordination between the left frontal and left central cortex. Moreover, positron emission tomography studies have shown abnormal hemispheric dominance with activation of the left hemisphere during stuttered speech and a possible compensatory hyperactivity of the right hemisphere during fluent speech.<sup>35 36</sup>

Attempts to localise regions that regulate fluent speech by analysing brains of patients who developed acquired stuttering following a stroke have failed to show a consistent location or pattern that leads to stuttering. Neurogenic stutterers, in fact, have lesions in both hemispheres and in all lobes.<sup>2</sup> Our case involved a patient who developed stuttering with tumour involvement of the corpus callosum, suggesting that this structure may play a role in producing fluent speech. In addition to this case, there have been five cases of infarct of the corpus callosum that caused stuttering. All five involved the body to some extent and three involved the splenium.<sup>19</sup> Three of the five developed a callosal apraxia, though that was not the case with our patient. Friederici *et al*<sup>37</sup> compared the speech patterns of patients who had infarcts throughout the corpus callosum to those of normal controls and concluded that the posterior third of the corpus callosum, including the splenium, is involved in processing prosodic information and syntax.

In the case presented here, the patient had a known right-sided anaplastic astrocytoma that caused a homonymous hemianopsia. As the tumour extended into the right temporal lobe and into the left hemisphere through the corpus callosum, he developed intermittent stuttering. However, callosal infarcts have been reported previously without causing stuttering or other speech disorders, while infarcts throughout the cortex and brainstem have led to stuttering in a number of cases. Speech fluency, therefore, is difficult to localise to one area, but rather depends on the interplay between various parts of the cortex, requiring interhemispheric communication through the corpus callosum.

Two separate case reports in the central nervous system literature have examined stuttering. Seki *et al*<sup>38</sup> described a recurrence of developmental stuttering from a brain tumour in the corpus callosum. In a separate report, Balamurali *et al*<sup>39</sup> describe a case of improvement of persistent developmental stuttering after surgical excision of a left perisylvian meningioma. In these case reports, the stuttering was developmental rather than acquired and in left perisylvian meningioma case report, the stuttering improved after the removal of the tumour.

Our case report represents with first description of acquired stuttering due to brain tumour recurrence.

### Learning points

- ▶ Acquired stuttering is rare neurological phenomenon that can occur as a result of acute neurological injury.
- ▶ Ischaemic stroke is a well-documented aetiology of acquired stuttering.
- ▶ This case report demonstrates the first description of acquired stuttering due to brain tumour recurrence.

**Contributors** KBP and ST are responsible for the conception and design, drafting, analysis and final approval of the version to be published.

**Competing interests** None.

**Patient consent** Obtained.

**Provenance and peer review** Not commissioned; externally peer reviewed.

### REFERENCES

- 1 Yairi E, Ambrose NG. Early childhood stuttering I: persistency and recovery rates. *J Speech Lang Hear Res* 1999;42:1097–112.
- 2 Buchel C, Sommer M. What causes stuttering? *PLoS Biol* 2004;2:E46.
- 3 Bar KJ, Hager F, Sauer H. Olanzapine- and clozapine-induced stuttering. A case series. *Pharmacopsychiatry* 2004;37:131–4.
- 4 Brady JP. The pharmacology of stuttering: a critical review. *Am J Psychiatry* 1991;148:1309–16.
- 5 Burns D, Brady JP, Kuruwilla K. The acute effect of haloperidol and apomorphine on the severity of stuttering. *Biol Psychiatry* 1978;13:255–64.
- 6 Prins D, Mandelkorn T, Cerf FA. Principal and differential effects of haloperidol and placebo treatments upon speech disfluencies in stutterers. *J Speech Hear Res* 1980;23:614–29.
- 7 Quader SE. Dysarthria: an unusual side effect of tricyclic antidepressants. *BMJ* 1977;2:97.
- 8 Helm NA, Butler RB, Benson DF. Acquired stuttering. *Neurology* 1978;28:1159–65.
- 9 Aram DM, Ekelman BL, Rose DF, *et al*. Verbal and cognitive sequelae following unilateral lesions acquired in early childhood. *J Clin Exp Neuropsychol* 1985;7:55–78.
- 10 Ardila A, Lopez MV. Severe stuttering associated with right hemisphere lesion. *Brain Lang* 1986;27:239–46.
- 11 Donnan GA. Stuttering as a manifestation of stroke. *Med J Aust* 1979;1:44–5.
- 12 Fawcett RG. Stroke-associated acquired stuttering. *CNS Spectr* 2005;10:94–5.
- 13 Fleet WS, Heilman KM. Acquired stuttering from a right hemisphere lesion in a right-hander. *Neurology* 1985;35:1343–6.
- 14 Grant AC, Biousse V, Cook AA, *et al*. Stroke-associated stuttering. *Arch Neurol* 1999;56:624–7.
- 15 Nass R, Schreter B, Heier L. Acquired stuttering after a second stroke in a two-year-old. *Dev Med Child Neurol* 1994;36:73–8.
- 16 Riggs JE, Nelson LJ, Lanham JE. Reemergence of stuttering after focal cerebral insult. *Arch Neurol* 1983;40:260.
- 17 Soroker N, Bar-Israel Y, Schechter I, *et al*. Stuttering as a manifestation of right-hemispheric subcortical stroke. *Eur Neurol* 1990;30:268–70.
- 18 Abe K, Yokoyama R, Yorifuji S. Repetitive speech disorder resulting from infarcts in the paramedian thalami and midbrain. *J Neurol Neurosurg Psychiatry* 1993;56:1024–6.
- 19 Kakishita K, Sekiguchi E, Maeshima S, *et al*. Stuttering without callosal apraxia resulting from infarction in the anterior corpus callosum. A case report. *J Neurol* 2004;251:1140–1.
- 20 Ross ED, Thompson RD, Yenkosky J. Lateralization of affective prosody in brain and the callosal integration of hemispheric language functions. *Brain Lang* 1997;56:27–54.
- 21 Rubens AB. Aphasia with infarction in the territory of the anterior cerebral artery. *Cortex* 1975;11:239–50.
- 22 Theys C, De Nil L, Thijs V, *et al*. A crucial role for the cortico-striato-cortical loop in the pathogenesis of stroke-related neurogenic stuttering. *Hum Brain Mapp* 2013;34:2103–12.
- 23 Kono I, Hirano T, Ueda Y, *et al*. A case of acquired stuttering resulting from striatocapsular infarction. *Rinsho Shinkeigaku* 1998;38:758–61.
- 24 Tsumoto T, Nishioka K, Nakakita K, *et al*. Acquired stuttering associated with callosal infarction: a case report. *No Shinkei Geka* 1999;27:79–83.
- 25 Ciabarra AM, Elkind MS, Roberts JK, *et al*. Subcortical infarction resulting in acquired stuttering. *J Neurol Neurosurg Psychiatry* 2000;69:546–9.
- 26 Hagiwara H, Takeda K, Saito F, *et al*. A case of callosal apraxia without agraphia and acquired stuttering associated with callosal infarction. *Rinsho Shinkeigaku* 2000;40:605–10.
- 27 Turgut N, Utku U, Balci K. A case of acquired stuttering resulting from left parietal infarction. *Acta Neurol Scand* 2002;105:408–10.
- 28 Doi M, Nakayasu H, Soda T, *et al*. Brainstem infarction presenting with neurogenic stuttering. *Intern Med* 2003;42:884–7.
- 29 Hamano T, Hiraki S, Kawamura Y, *et al*. Acquired stuttering secondary to callosal infarction. *Neurology* 2005;64:1092–3.
- 30 Sahin HA, Krespi Y, Yilmaz A, *et al*. Stuttering due to ischemic stroke. *Behav Neurol* 2005;16:37–9.
- 31 Osawa A, Maeshima S, Yoshimura T. Acquired stuttering in a patient with Wernicke's aphasia. *J Clin Neurosci* 2006;13:1066–9.
- 32 Tani T, Sakai Y. Stuttering after right cerebellar infarction: a case study. *J Fluency Disord* 2010;35:141–5.
- 33 Tani T, Sakai Y. Analysis of five cases with neurogenic stuttering following brain injury in the basal ganglia. *J Fluency Disord* 2011;36:1–16.
- 34 Paden EP, Yairi E, Ambrose NG. Early childhood stuttering II: initial status of phonological abilities. *J Speech Lang Hear Res* 1999;42:1113–24.
- 35 Braun AR, Varga M, Stager S, *et al*. Altered patterns of cerebral activity during speech and language production in developmental stuttering. An H2(15)O positron emission tomography study. *Brain* 1997;120(Pt 5):761–84.
- 36 Fox PT, Ingham RJ, Ingham JC, *et al*. A PET study of the neural systems of stuttering. *Nature* 1996;382:158–61.
- 37 Friederici AD, von Cramon DY, Kotz SA. Role of the corpus callosum in speech comprehension: interfacing syntax and prosody. *Neuron* 2007;53:135–45.
- 38 Seki Y, Maeshima S, Osawa A, *et al*. Acquired stuttering in addition to a recurrence of developmental stuttering caused by brain tumor in the corpus callosum. *No Shinkei Geka* 2011;39:581–7.
- 39 Balamurali G, Bukhari S, Carter J, *et al*. Improvement of persistent developmental stuttering after surgical excision of a left perisylvian meningioma. *Br J Neurosurg* 2010;24:485–7.

Copyright 2013 BMJ Publishing Group. All rights reserved. For permission to reuse any of this content visit <http://group.bmj.com/group/rights-licensing/permissions>.  
BMJ Case Report Fellows may re-use this article for personal use and teaching without any further permission.

Become a Fellow of BMJ Case Reports today and you can:

- ▶ Submit as many cases as you like
- ▶ Enjoy fast sympathetic peer review and rapid publication of accepted articles
- ▶ Access all the published articles
- ▶ Re-use any of the published material for personal use and teaching without further permission

For information on Institutional Fellowships contact [consortiasales@bmjgroup.com](mailto:consortiasales@bmjgroup.com)

Visit [casereports.bmj.com](http://casereports.bmj.com) for more articles like this and to become a Fellow