

CASE REPORT

Transient ischaemic attack: an exceptional presenting syndrome of a superior sagittal sinus thrombosis

Assunta Scuotto, Raffaele D'Avanzo, Massimo Natale, Michele Rotondo

Department of Neuroscience,
Second University of Naples,
Naples, Italy

Correspondence to
Professor Assunta Scuotto,
assunta.scuotto@unina2.it

SUMMARY

We report a case of a transient ischaemic attack (TIA) as an exceptionally rare form of cerebral vein thrombosis. A 41-year-old man presented with a headache and five episodes of a transient left hemiparesis lasting approximately 10–15 min over the course of 2 weeks. Arterial origins of the disease were ruled out by detailed investigations. However, MR venography revealed a superior sagittal sinus thrombosis with numerous prominent collateral venous channels. No parenchymal lesion was seen. After medical therapy, no further transient neurological deficit occurred. Follow-up MR venography showed sinus recanalisation.

BACKGROUND

Interest in this case lies in the fact that venous sinus thrombosis (VST), a rare life-threatening pathology, unusually presents transitory focal deficits in its course. Although exceptional, venous sinus thrombosis (TIA)-like events due to VST should be taken into account, requiring special care to ensure correct diagnosis and treatment.

CASE PRESENTATION

A 41-year-old man was admitted because of a headache and recurrent transient left hemiparesis. During the last 2 weeks, he experienced a total of five episodes of mild left-sided weakness, lasting 10–15 min without any lapses of consciousness. His headache was unresponsive to analgesics and was increasing in intensity during the attacks; it was diffuse and dull, sometimes accompanied by nausea. No triggers for the neurological events were identified. On admission, the neurological examination was normal. Physical examination showed no abnormalities.

His medical history was unremarkable. In terms of vascular risk factors, he had been smoking <5 cigarettes/day for the past 12 years. Family history was non-contributory.

Initial working diagnoses included TIAs, seizures and hemiplegic migraines. Focal seizure episodes, generally lasting a few minutes or less, were previously excluded: routine EEG performed during an episode of hemiparesis was normal.

INVESTIGATIONS

Brain CT was normal. Electrocardiography, echocardiography, carotid ultrasonography, MRI of the brain and MR angiography (MRA) of the cerebral arterial vessels were unremarkable, while MR venography (MRV) detected superior sagittal sinus

thrombosis (figure 1A). The haematological and biochemical profiles were normal. Thrombophilia, vasculitis and infective screening were negative.

DIFFERENTIAL DIAGNOSIS

The differential diagnosis chiefly included cerebral arterial thromboembolism and/or cardiogenic embolism, which are the most common causes of TIAs. Although less frequent and/or exceptional, other conditions such as vasculitis, cerebral vasospasm due to sympathomimetic drugs, hypercoagulable state, syncope, migraine, partial seizures, hypoglycaemia, labyrinthine disorders and exceptional subepidural haematomas, subarachnoid haemorrhage and neurobrucellosis were likewise considered and excluded.

Detailed laboratory investigations (ie, hypercoagulability tests as protein C, protein S, antiphospholipid antibodies, homocysteinemia, antithrombin, rheumatoid factor, erythrocyte sedimentation rate, C reactive protein) along with neuroradiological procedures allowed for the proper diagnosis.

TREATMENT

Medical treatment included subcutaneous low-molecular-weight heparin administration for 3 weeks. He was discharged on anticoagulant therapy (warfarin) for 3 months.

OUTCOME AND FOLLOW-UP

The headache subsided 1 week after anticoagulation therapy. No further attacks presented during hospitalisation or at the 14-month follow-up. MRV, performed 1 and 12 months after treatment (figure 1B), detected full recanalisation of the affected sinus. Actually, it would be better to plan and recommend a neuroimaging follow-up 3–6 months after diagnosis to assess the recanalisation of the occluded cortical vein/sinuses in stable patients.

DISCUSSION

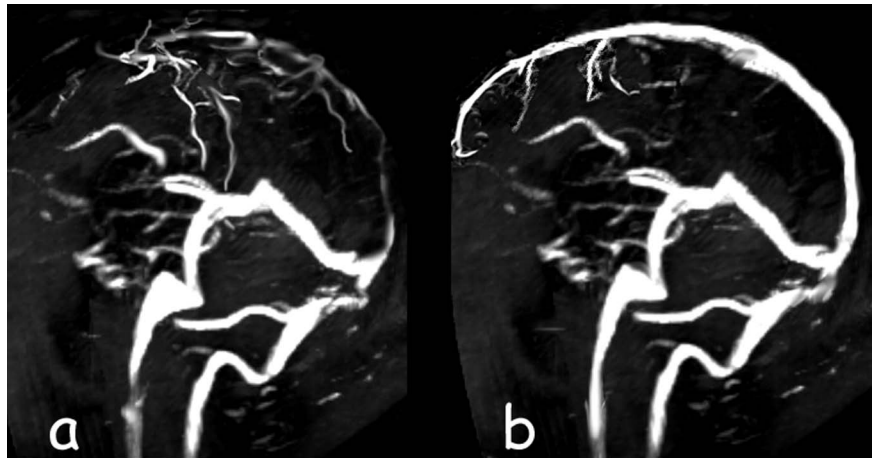
Cerebral venous thrombosis is a rare life-threatening pathology with an estimated annual incidence of 3–4 cases per million in adults and 7 cases per million in neonates.¹

Among the most common risk factors are the use of oral contraceptives, pregnancy and puerperium, which contribute to making the disease more frequent in women than in men. Other causes such as cerebral neoplasms, infections and traumas are less frequently encountered. In 15–20% of patients, cerebral venous thrombosis remains unprovoked. Also, in the present case, no aetiological factor



To cite: Scuotto A, D'Avanzo R, Natale M, et al. *BMJ Case Rep* Published online: [please include Day Month Year] doi:10.1136/bcr-2013-200894

Figure 1 (A) MR venography show extensive thrombosis in the superior sagittal sinus, with extensive cortical venous collateral formation. (B) MR venography 12 months later depicts complete recanalisation of the superior sagittal sinus.



could be found. The most frequently encountered sinuses are the superior sagittal (62% of patients) and the transverse (40%), but in two-thirds of cases more than one sinus is involved.

Clinical manifestations are variable and not specific, depending on the oedema and/or increased intracranial pressure, cerebral haemorrhages and cerebral infarcts. Signs and symptoms include headache (the most common one with no specific features), seizures, focal neurological deficits, papilloedema and consciousness alteration. Recurrent transient focal deficit is an exceedingly rare manifestation of cerebral venous thrombosis. To the best of our knowledge, less than half a dozen cases have been previously reported in the literature.^{2–7}

At present, the pathogenesis of TIA caused by VST still remains debatable. In the absence of parenchymal lesions as in the described case, a functional/metabolic disturbance, probably related to perfusion failure, might be considered the origin of the neurological deficit.

VST should be regarded as a continuing process of disequilibrium between prothrombotic and thrombolytic mechanisms rather than as an abrupt monophasic process. Consequently, local areas of the brain could be only functionally/metabolically disturbed but not irreversibly damaged.⁸

Although collateral pathways in venous sinus disease are generally believed to be well established because of the slow growth of the venous thrombus, a discrepant moment of venous drainage can occur before the adequate opening of the collateral channels. Flow dynamic forces can collide at the level of capacitance vessels after which the tissue perfusion pressure may be reduced, which results in a neurological deficit.³

Early diagnosis is essential to minimise morbidity and improve survival of patients with VST. However, diagnosis may be overlooked or delayed mainly because of the wide spectrum of clinical presentations along with the possible lack of indirect imaging signs such as parenchymal abnormalities, that is, venous infarcts, brain oedema, etc.

Usually MRV allows a proper diagnosis, seldom requiring additional digital angiography.

Anticoagulant treatment, initially with heparin and subsequently with oral vitamin K antagonists, is crucial. Usually oral anticoagulant is administered only for 3 months if the risk factor of VST is transient and/or removed; otherwise, it can be prolonged as in the case of severe thrombophilia or of other permanent risk factors such as myeloproliferative neoplasms.^{1,9}

Other treatments, such as local or systemic thrombolysis, are currently still under evaluation. These options could be associated with a high risk of intracranial bleeding and should therefore be considered only for patients who deteriorate despite adequate anticoagulation.⁹ Conversely, according to a recent report,¹⁰

endovascular thrombolytic treatment might cure the chronic thrombosis and recanalise the cerebral venous sinus.

Learning points

- ▶ We suggest that patients with transient ischaemic attack (TIA)-like episodes and headache should be carefully investigated in terms of cerebral venous thrombosis, especially if detailed investigations for arterial–cardiac thromboembolic aetiologies are completed and common causes of TIA are excluded.
- ▶ MR venography should be additionally performed when neuroradiological studies exclude arterial origins of the disease. Digital subtraction angiography could be required in selected cases.
- ▶ Early diagnosis and anticoagulant treatment reduce morbidity and improve survival.
- ▶ The optimal duration of anticoagulant treatment is not currently well established.

Competing interest None.

Patient consent Obtained.

Provenance and peer review Not commissioned; externally peer reviewed.

REFERENCES

- 1 Martinelli I. Cerebral vein thrombosis. *Thromb Res* 2013;131:S51–4.
- 2 Bousser MG, Chiras J, Borjes J, et al. Cerebral venous thrombosis: a review of 38 cases. *Stroke* 1985;16:199–213.
- 3 Chang DI, Yoon SS, Chung KC. Superior sagittal sinus thrombosis and transient ischaemic attacks: possible mechanism. *J Korean Med Sci* 1998;13:566–8.
- 4 Liu GJ, Wang YF, Liu ZG, et al. A unilateral brachiocephalic vein thrombosis: cause of a rare, transient ischaemic attack, a case report and review of the literature. *Int J Neurosci* 2013;123:433–8.
- 5 Togay IC, Kural AM, Erden I. Cerebral vein thrombosis as an exceptional cause of transient ischaemic attack. *J Stroke Cerebrovasc Dis* 2012;21:907–12.
- 6 Morris JG, Fisher M, Carandang RA. Cortical vein thrombosis as a mimic for isolated cortical subarachnoid hemorrhage and transient ischaemic attack. *Case Rep Neurol* 2010;2:63–8.
- 7 Manzano Palomo S, Egidio Herrero JA, Saiz Ayala A, et al. Transient ischaemic attack: the only presenting syndrome of dural sinus thrombosis. *Neurologia* 2006;21:155–8.
- 8 Villringer A, Mehraein S, Einhüpl KM. Pathophysiological aspects of cerebral sinus venous thrombosis (SVT). *J Neuroradiol* 1994;21:72–80.
- 9 Einhüpl K, Stam J, Bousser MG, et al. for the European Federation of Neurological Societies. EFNS guideline on the treatment of cerebral venous and sinus thrombosis in adult patients. *Eur J Neurol* 2010;17:1229–35.
- 10 Guo XB, Song LJ, Guan S. Endovascular treatment of chronic, recurrent headache secondary to chronic cerebral venous sinus thrombosis. *J Stroke Cerebrovasc Dis* Published Online First: 27 May 2013. doi: 10.1016/j.jstrokecerebrovasdis.2013.04.005

Copyright 2013 BMJ Publishing Group. All rights reserved. For permission to reuse any of this content visit <http://group.bmj.com/group/rights-licensing/permissions>.
BMJ Case Report Fellows may re-use this article for personal use and teaching without any further permission.

Become a Fellow of BMJ Case Reports today and you can:

- ▶ Submit as many cases as you like
- ▶ Enjoy fast sympathetic peer review and rapid publication of accepted articles
- ▶ Access all the published articles
- ▶ Re-use any of the published material for personal use and teaching without further permission

For information on Institutional Fellowships contact consortiasales@bmjgroup.com

Visit casereports.bmj.com for more articles like this and to become a Fellow