

Typical and atypical phenotypes of PNPO deficiency with elevated CSF and plasma pyridoxamine on treatment

TYSON L WARE¹ | JOHN EARL² | GAJJA S SALOMONS³ | EDUARD A STRUYS³ | HEIDI L PETERS⁴ |
KATHERINE B HOWELL¹ | JAMES J PITT⁵ | JEREMY L FREEMAN¹

1 Department of Neurology, The Royal Children's Hospital, Melbourne; **2** Discipline of Paediatrics and Child Health, University of Sydney, Sydney, NSW, Australia.

3 Department of Clinical Chemistry, Metabolic Unit, VU University Medical Center, Amsterdam, the Netherlands. **4** Department of Metabolic Genetics, The Royal Children's Hospital, Melbourne; **5** Victorian Clinical Genetics Services, Murdoch Childrens Research Institute, Melbourne, Vic., Australia.

Correspondence to Dr Jeremy L Freeman at Department of Neurology, The Royal Children's Hospital, 50 Flemington Road, Parkville Vic. 3052, Australia. E-mail: jeremy.freeman@rch.org.au

PUBLICATION DATA

Accepted for publication 15th October 2013.

Published online 23rd November 2013.

ABBREVIATIONS

FMN Flavinmononucleotide
PNPO Pyridox(am)ine phosphate oxidase

Pyridox(am)ine phosphate oxidase (PNPO) deficiency causes severe early infantile epileptic encephalopathy and has been characterized as responding to pyridoxal-5'-phosphate but not to pyridoxine. Two males with PNPO deficiency and novel *PNPO* mutations are reported and their clinical, metabolic, and video-electroencephalographic (EEG) findings described. The first child showed electro-clinical responses to pyridoxine and deterioration when pyridoxine was withheld. At last review, he has well-controlled epilepsy with pyridoxal-5'-phosphate monotherapy and an autism spectrum disorder. The second child had a perinatal middle cerebral artery infarct and a myoclonic encephalopathy. He failed to respond to pyridoxine but responded well to pyridoxal-5'-phosphate. At the age of 21 months he has global developmental delay and hemiparesis but is seizure-free with pyridoxal-5'-phosphate monotherapy. Plasma and cerebrospinal fluid pyridoxamine levels were increased in both children during treatment with pyridoxine or pyridoxal-5'-phosphate. These observations indicate that differential responses to pyridoxine and pyridoxal-5'-phosphate treatment cannot be relied upon to diagnose PNPO deficiency.

Vitamin B6 deficiency is a rare but treatable cause of neonatal and infantile seizures and neurodevelopmental disability.¹ Delayed treatment in children with early onset seizures is associated with increased risk of learning difficulties and cerebral palsy, making early diagnosis important. Two inborn errors affecting vitamin B6 metabolism are known: antiquitin deficiency (*ALDH7A1* gene, OMIM 266100) and pyridox(am)ine phosphate oxidase (PNPO) deficiency (*PNPO* gene, OMIM 610090). It was previously thought that PNPO deficiency responds to treatment with pyridoxal-5'-phosphate but not to pyridoxine.²

Here we report two children with PNPO deficiency and novel mutations, including their clinical and video-electroencephalographic (EEG) findings, as well as their plasma and cerebrospinal fluid (CSF) B6 vitamers analyses. Contrary to expectations, the first child's seizures responded to pyridoxine treatment. Additionally, we found elevated plasma and CSF pyridoxamine levels in these children compared with treated and untreated control individuals.

Consent for publication of patient information was obtained from each family.

CASE REPORT 1

A male infant was born to non-consanguineous Greek parents by emergency Caesarean section for breech presentation after spontaneous labour at 38 weeks' gestation. The

infant developed persistent multifocal myoclonic jerks and an eye movement disorder late on the first day of life. Septic work-up and brain magnetic resonance imaging (MRI) were normal. EEG on day 3 showed a mildly abnormal trace with an excess of multifocal sharp activity, but normal background activity. Hemiclonic seizures began on day 5, prompting administration of phenobarbitone. These clinical features persisted along with hypertonia, mild encephalopathy, and an intermittent high-pitched cry, until pyridoxine was added on day 7. Pyridoxine-dependent epilepsy caused by an *ALDH7A1* defect was suspected but urine amino adipic semialdehyde levels were normal. Breakthrough seizures occurred whenever pyridoxine doses were missed, which prompted sequencing of the *ALDH7A1* gene. This was normal and the diagnosis remained elusive through early childhood.

Occasional breakthrough seizures with Rolandic and occipital features were noted. Some were attributed to pyridoxine dose omission, dose delay, or intercurrent illness. Interictal EEG showed bilateral independent centrotemporal spikes with normal background activity. Other antiepileptic medications were trialled without benefit and at the parents' insistence the child remained on treatment with low-dose pyridoxine (50mg twice daily). Diagnosis of an autism spectrum disorder was made at 4 years of age. Frequent eye rubbing events were considered behavioural.

Video-EEG monitoring was first performed at 5 years of age for characterization of infrequent seizures suspected to be caused by occult focal cortical dysplasia. The interictal record again showed bilateral independent centrotemporal spikes, which increased during light sleep, plus rare generalized spike-wave bursts. Pyridoxine-dependence was confirmed as omission of a single dose led to increased interictal epileptiform activity and the occurrence of frequent seizures. Episodes with irritability and eye rubbing were associated with background slowing and interictal bursts of bisynchronous frontal and generalized spike-wave. Focal seizures arose from this encephalopathic state with variable localization and clinical features that included focal clonus and blinking, but also periods of no clinical change during robust focal neocortical seizures. Pyridoxine re-loading abolished the status, restored the normal background and greatly reduced the interictal discharges.

The confirmation of pyridoxine-dependence, but with normal *ALDH7A1* sequencing, as well as some features of the metabolic profile (Table I), led to suspicion of PNPO deficiency. This was supported by a single nucleotide polymorphism microarray, which revealed the presence of a single long (20 megabase-pair) contiguous stretch of homozygosity covering the *PNPO* locus at 17q31-32 and a peak on the CSF chromatogram (Fig. 1a) corresponding to that seen in another patient with confirmed PNPO deficiency. Consequently, a trial of pyridoxal-5'-phosphate monotherapy (100mg three times daily, 20mg/kg/d) was commenced, but on the third day another seizure occurred with febrile illness. This appeared to discredit the diagnosis of PNPO deficiency and led to reinstatement of pyridoxine treatment.

What this paper adds

- PNPO deficiency is sometimes pyridoxine-responsive.
- Elevated plasma and CSF pyridoxamine may be a marker of treated PNPO deficiency.

At 7 years of age, sequencing of the *PNPO* gene identified a novel, likely pathogenic homozygous missense mutation (c.674G>A, p.R225H; Table SI, online supporting information), for which both parents were carriers. Pyridoxal-5'-phosphate (100mg three times daily, 15mg/kg/d) was added to pyridoxine (15mg/kg/d) and led to a protracted period free of convulsive seizures, although episodes with eye rubbing persisted. It was expected that withdrawal of pyridoxine leaving pyridoxal-5'-phosphate as monotherapy (200mg three times daily, 27mg/kg/d) would be tolerated. This was attempted during video-EEG monitoring, but diffuse background slowing with generalized epileptiform activity emerged (Fig. 1b) and correlated with periods of irritability and eye rubbing. Focal seizures were seen after 42 hours on pyridoxal-5'-phosphate monotherapy.

Plasma B6 vitamers have been measured when treated with pyridoxine, with pyridoxal-5'-phosphate and with both pyridoxine and pyridoxal-5'-phosphate (Table I). After video-EEG the patient returned to combination therapy and the dose of pyridoxal-5'-phosphate was increased while the dose of pyridoxine was reduced. Currently the patient takes pyridoxal-5'-phosphate 1100mg in three divided doses (44mg/kg/d) and no pyridoxine. This is well tolerated and no further eye rubbing events or seizures have occurred, apart from two seizures during an intercurrent febrile illness.

Table I: Clinical, EEG, and metabolic investigation findings

	Case 1	Case 2
Neonatal period	Clinical: multifocal myoclonic jerks; eye movement disorder EEG: normal continuity and background; minor excess sharp transients; no events captured	Clinical: multifocal myoclonic jerks; eye movement disorder; tongue thrusting EEG: Burst suppression pattern with myoclonus corresponding to the bursts
Infancy	Clinical: breakthrough versive and hemiclonic seizures EEG: normal background	Clinical: breakthrough versive seizures; tonic seizures and spasms EEG: slow background; multifocal discharges; tonic seizures and spasms
Childhood	Clinical: staring and eye rubbing at dosage troughs; breakthrough versive and hemiclonic seizures EEG: normal interictal background; centrotemporal spikes; background slowing and generalized spike-wave with pyridoxine omission; focal seizures	
Initial metabolic profile	Urine: normal AASA, P6C, sulfite, purines, pyrimidines and pipercolic acid Plasma: normal profile CSF: Thr↑, Arg↓, 5-HIAA ↓, HVA ↓	Urine: normal P6C, sulfite, purines, pyrimidines and pipercolic acid; VLA↑ Plasma: normal profile CSF: Thr↑, Arg↓, 5-HIAA ↓, HVA ↓
Pyridoxamine levels (nmol/L) ^a	Plasma: 400 ^{PN} ; 470 ^{PLP} ; 1060 ^{PN+PLP} CSF: 966 ^{PN} ; 553 ^{PN} ; 311 ^{PN}	Plasma: 624 ^{PLP} CSF: 5898 ^{PLP} ; 7925 ^{PLP}

^aPlasma pyridoxamine levels were <50 nmol/L in control individuals and in one pyridoxine-supplemented unaffected participant. CSF pyridoxamine levels were 50 (SD 17) nmol/L in 14 pyridoxine-supplemented neonatal controls. EEG, encephalogram; AASA, amino adipic semialdehyde; P6C, piperidine 6-carboxylate; VLA, vanillic acid; Thr, threonine; Arg, arginine; 5-HIAA, 5-hydroxyindoleacetic acid; HVA, homovanillic acid; PN, pyridoxine therapy; PLP, pyridoxal 5'-phosphate therapy; PN+PLP, pyridoxine + pyridoxal 5'-phosphate combination therapy.

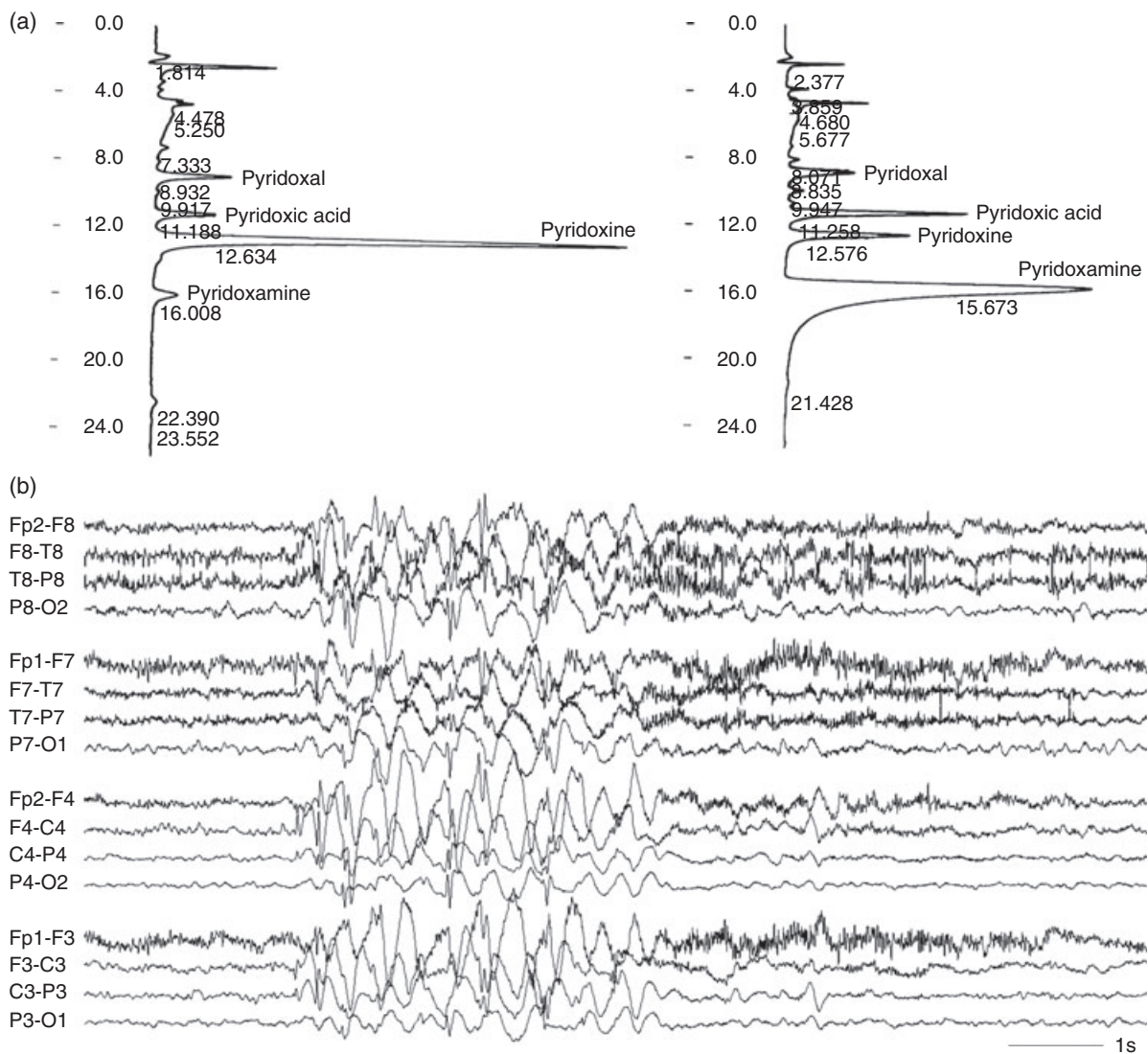


Figure 1: Cerebrospinal fluid (CSF) chromatograms and encephalopathic encephalogram (EEG) in PNPO deficiency. (a) CSF chromatograms in an unaffected neonate (on the left) and in our second patient (right), both treated with pyridoxal 5'-phosphate. In the patient CSF pyridoxamine is markedly elevated, whereas pyridoxine is comparatively low. (b) EEG demonstrating intermittent diffuse slowing and irregular generalized epileptiform activity in the encephalopathic state associated with eye rubbing in our first patient.

CASE REPORT 2

A male infant was born to consanguineous Sudanese parents at 35 weeks' gestation by Caesarean section for non-reassuring foetal monitoring. He developed a neonatal epileptic encephalopathy on day 1 of life with multifocal myoclonus and a suppression-burst EEG. Brain MRI revealed a perinatal middle cerebral arterial ischaemic stroke, but this was not considered to be the cause of the myoclonic encephalopathy. There was a good response to treatment with a combination of levetiracetam, pyridoxal-5'-phosphate, folinic acid, and biotin, whereas treatment with phenobarbitone and phenytoin had been ineffective. Initial metabolic investigations indicated the possibility of PNPO deficiency (Table I). Breakthrough myoclonic

seizures and abnormal eye movements occurred with missed doses of pyridoxal-5'-phosphate, during intercurrent illnesses and at pyridoxal-5'-phosphate dose troughs. A single nucleotide polymorphism microarray demonstrated numerous long contiguous stretches of homozygosity, consistent with parental consanguinity. One of these stretches covered the PNPO locus at 17q31, while there was no loss of heterozygosity at the same locus in two unaffected siblings. Sequencing of the *PNPO* gene identified a novel, probably pathogenic homozygous missense mutation (c.686G>A, p.R229Q; Table SI), for which both parents were carriers. Pyridoxal-5'-phosphate dosage was increased to 50mg/kg/day in four to five divided doses, achieving seizure-freedom. Other

antiepileptic medications were able to be discontinued. At 21 months of age there is moderate global developmental delay and hemiparesis.

DISCUSSION

For decades, pyridoxine-dependent epilepsy was known to occur in children with neonatal epileptic encephalopathy and in older children.^{1,3} Antiquitin deficiency and PNPO deficiency are two inborn errors of metabolism that cause functional pyridoxal-5'-phosphate deficiency, with very similar clinical, metabolic, and neurotransmitter abnormalities. Clinical and metabolic characterization of PNPO deficiency^{4,5} preceded discovery of the molecular genetic basis of the condition.² Reports of patients with *PNPO* mutations are summarized in Table S1. The peculiar eye movement disorder, orofacial dystonia, and epileptic seizures noted in our patients are typical of the neonatal phenotype of pyridoxine-dependent epilepsy.⁶ In both antiquitin and PNPO deficiency, pyridoxal 5'-phosphate-dependent enzymes including aromatic amino acid decarboxylase, threonine dehydratase, and glycine cleavage enzyme are deficient, giving an overall metabolic signature with elevated vanillic acid, threonine, and glycine and reduced arginine, homovanillic acid, and 5-hydroxyindoleacetic acid. However, these plasma and CSF abnormalities quickly disappear with treatment, which is often started before results of metabolic testing are available. Amino adipic semialdehyde and piperidine 6-carboxylate are biomarkers for antiquitin deficiency that persist regardless of treatment, but clinical diagnosis of PNPO deficiency has been more difficult because of the lack of a persistent biomarker.

Clinical response to pyridoxal-5'-phosphate treatment and lack of response to pyridoxine treatment have generally been regarded as characteristic of PNPO deficiency,⁷ although transient pyridoxine responsiveness was reported in some cases.^{2,4,8} The existence of pyridoxine responsive forms of PNPO deficiency, illustrated by our first patient and by the recent case report of Pearl et al.⁹ makes this clinical approach to diagnosis unreliable. Indeed, acceptance of this generality led to diagnostic delay in our case, despite neurotransmitter and amino acid results suggesting PNPO deficiency. Footitt et al.¹⁰ presented evidence that plasma B6 vitamers, including pyridoxamine levels, may be useful in diagnosing PNPO deficiency in the treated state. We noted that plasma and CSF pyridoxamine levels were greatly increased in our patients relative to treated and untreated controls (Table I).

Pyridox(am)ine phosphate oxidase is part of a salvage pathway regenerating pyridoxal-5'-phosphate from pyridoxine and pyridoxamine derived from food or degraded B6-dependent enzymes. In PNPO deficiency, pyridoxal-5'-phosphate may be present as a result of pyridoxal-5'-phosphate treatment, or pyridoxine treatment combined with some residual PNPO activity. There is an effective equilibrium between pyridoxal-5'-phosphate and pyridoxamine 5'-phosphate as part of the reaction mechanism of many B6-depen-

dent isomers such as transaminases. We suggest that pyridoxamine 5'-phosphate may, therefore, be released from these enzymes during their catalytic cycles and subsequently converted to pyridoxamine (Fig. S1, online supporting information). Pyridoxamine 5'-phosphate release may be facilitated because of its non-covalent binding to the enzymes, in contrast to the covalently bound pyridoxal-5'-phosphate. Endogenous substrate and product concentrations may also favour pyridoxamine 5'-phosphate production, but the reasons for pyridoxamine accumulation in treated patients are currently unexplained.

Understanding of the PNPO enzyme, its cofactor flavin-mononucleotide (FMN) and its substrates pyridoxine 5'-phosphate and pyridoxamine 5'-phosphate has been greatly aided by molecular and crystallographic studies, in which the R229Q mutation was shown to have better catalytic activity and FMN affinity than the R229W mutation.^{11,12} The phenotype observed in our second patient has been correspondingly milder than that seen in the reported R229W patients (Table S1).^{13,14} The same authors identified the importance of the nearby R225 residue, which provides one of the critical hydrogen bonding sites to the substrate and correctly orientates the substrate and FMN within the active site of PNPO. The R225H mutation in our first patient is, therefore, presumed to disrupt the arrangement of substrate and cofactor within the PNPO active site. The G118R mutation of the patient reported by Pearl et al.⁹ is also in close proximity to the pyridoxine 5'-phosphate and FMN binding sites. We hypothesize that in these patients there is a small perturbation to the configuration, with some degree of pyridoxine 5'-phosphate binding preserved. Pyridoxine supplementation can, therefore, boost the pyridoxine 5'-phosphate substrate via pyridoxal kinase (Fig. S1), with some oxidation of pyridoxine 5'-phosphate to pyridoxal-5'-phosphate resulting in pyridoxine-responsiveness. Recognition of FMN as a cofactor has prompted us to consider co-administration of riboflavin in our patients.

ACKNOWLEDGEMENTS

The authors wish to thank Avantika Mishra for amino acid analysis and Trent Burgess for providing the single nucleotide polymorphism microarray results. Portions of this work were supported by the Victorian Government's Operational Infrastructure Support Program. The authors have stated that they had no interests which might be perceived as posing a conflict or bias.

SUPPORTING INFORMATION

The following additional information can be found online:

Table S1: Summary of reported *PNPO* deficiency cases and mutations.

Figure S1: Major metabolic inter-conversion of B6 vitamers. Enzymes involved are 1 = pyridoxal kinase; 2 = specific and non-specific phosphatases; 3 = pyridox(am)ine phosphate oxidase (PNPO); 4 = indirect conversion from various enzymes utilising pyridoxal 5'-phosphate.

REFERENCES

1. Baxter P. Pyridoxine-dependent and pyridoxine-responsive seizures. *Dev Med Child Neurol* 2001; **43**: 416–20.
2. Mills PB, Surtees RA, Champion MP, et al. Neonatal epileptic encephalopathy caused by mutations in the PNPO gene encoding pyridox(am)ine 5'-phosphate oxidase. *Hum Mol Genet* 2005; **14**: 1077–86.
3. Hunt AD, Stokes J, McCrory WW, Stroud HH. Pyridoxine dependency: report of a case of intractable convulsions in an infant controlled by pyridoxine. *Pediatrics* 1954; **13**: 140–5.
4. Brautigam C, Hyland K, Wevers R, et al. Clinical and laboratory findings in twins with neonatal epileptic encephalopathy mimicking aromatic L-amino acid decarboxylase deficiency. *Neuropediatrics* 2002; **33**: 113–7.
5. Clayton PT, Surtees RA, DeVile C, Hyland K, Heales SJ. Neonatal epileptic encephalopathy. *Lancet* 2003; **361**: 1614.
6. Schmitt B, Baumgartner M, Mills PB, et al. Seizures and paroxysmal events: symptoms pointing to the diagnosis of pyridoxine-dependent epilepsy and pyridoxine phosphate oxidase deficiency. *Dev Med Child Neurol* 2010; **52**: e133–42.
7. Kuo MF, Wang HS. Pyridoxal-phosphate responsive epilepsy with resistance to pyridoxine. *Pediatr Neurol* 2002; **26**: 146–7.
8. Khayat M, Korman SH, Frankel P, et al. PNPO deficiency: an under diagnosed inborn error of pyridoxine metabolism. *Mol Genet Metab* 2008; **94**: 431–4.
9. Pearl PL, Hyland K, Chiles J, McGavin CL, Yu Y, Taylor D. Partial pyridoxine responsiveness in PNPO deficiency. *JIMD Rep* 2013; **9**: 139–42.
10. Footitt EJ, Clayton PT, Mills K, et al. Measurement of plasma B(6) vitamers profiles in children with inborn errors of vitamin B(6) metabolism using an LC-MS/MS method. *J Inherit Metab Dis* 2013; **36**: 139–45.
11. Musayev FN, Di Salvo ML, Saavedra MA, et al. Molecular basis of reduced pyridoxine 5'-phosphate oxidase catalytic activity in neonatal epileptic encephalopathy disorder. *J Biol Chem* 2009; **284**: 30949–56.
12. di Salvo ML, Ko TP, Musayev FN, Raboni S, Schirch V, Safo MK. Active site structure and stereospecificity of *Escherichia coli* pyridoxine-5'-phosphate oxidase. *J Mol Biol* 2002; **315**: 385–97.
13. Bagci S, Zschocke SJ, Hoffmann GF, et al. Pyridoxal phosphate-dependent neonatal epileptic encephalopathy. *Arch Dis Child Fetal Neonatal Ed* 2008; **93**: F151–2.
14. Ruiz A, Garcia-Villoria J, Ormazabal A, et al. A new fatal case of pyridox(am)ine 5'-phosphate oxidase (PNPO) deficiency. *Mol Genet Metab* 2008; **93**: 216–8.

Mac Keith Press

www.mackeith.co.uk/cdmelist.html

Childhood Headache


2nd Edition

Clinics in Developmental Medicine

Edited by **Ishaq Abu-Arafeh**

- Explores the current evidence base into the causes and treatments of childhood headache.
- Clinical experience brought to life with real case vignettes.
- Expanded information on difficult diagnoses, atypical presentations, management issues, and treatment options.
- New chapter on drawing as expression of headache by patients.

240 x 170mm / 352 pages / Hardback / June 2013 / 978-1-908316-75-2 / £95.00



T: 0800 243407 (FREE PHONE, UK ONLY) or +44 (0)1243 843294
F: +44 (0)1243 843296 / **E:** cs-books@wiley.co.uk