



Case Report

Hemichorea after multiple bee stings

Abstract

Bee sting is one of the most commonly encountered insect bites in the world. Despite the common occurrence of local and systemic allergic reactions, there are few reports of ischemic stroke after bee stings. To the best of our knowledge, there have been no reports on involuntary hyperkinetic movement disorders after multiple bee stings. We report the case of a 50-year-old man who developed involuntary movements of the left leg 24 hours after multiple bee stings, and the cause was confirmed to be a right temporal infarction on a diffusion magnetic resonance imaging scan. Thus, we concluded that the involuntary movement disorder was caused by right temporal infarction that occurred after multiple bee stings.

Despite the common occurrence of local and systemic allergic reactions after bee stings, there are few reports of severe complications such as acute coronary syndrome, ischemic stroke, and renal failure [1,2]. In particular, neurologic events after bee stings are very rare [3]. Usually, manifestations such as motor weakness, sensory change, dysarthria, ophthalmoplegia, altered mentation, vision loss, and seizure may occur [4,5]. However, there have been no reports of involuntary hyperkinetic movement disorders occurring after multiple bee stings. This is the first report of a patient with involuntary hyperkinetic movement disorder after multiple bee stings.

A 50-year-old man without any remarkable medical history was admitted to the hospital emergency department after multiple bee stings that occurred the previous day. There were an estimated 3 stings on both of his proximal tibia areas. He experienced itching and 2 syncope episodes after the multiple bee stings. Therefore, he visited a local clinic where he was orally medicated with a H1 blocker. Upon admission, he complained of dyspnea, lip swelling, and itching. His consciousness was normal, and his blood pressure was 140/80 mm Hg. He was given intravenous methylprednisolone (125 mg), intravenous chlorpheniramine maleate (4 mg), intravenous ranitidine (100 mg), and intramuscular adrenaline (0.3 mg). The patient was observed in the monitoring unit. During 1 follow-up hour (27 hours after the bee stings), he developed a sudden onset of involuntary hyperkinetic movements of the left leg. The computed tomography scan of his brain had normal findings. Diffusion magnetic resonance imaging of the patient revealed right temporal lobe infarction (Fig. 1). A brain computed tomography angiography with contrast revealed a right M2 inferior and superior division branch occlusion (Fig. 2). No pathologic findings were detected on echocardiography or in carotid artery Doppler examination. The laboratory findings, including cerebrospinal fluid tests, did not indicate any other pathology. The patient was examined by a neurologist and hospitalized for the treatment of involuntary movements and follow-up. He was treated

with aspirin, citicoline sodium, lorazepam, and haloperidol. On day 1 after admission, his involuntary movements disappeared. After 13 days, the patient was discharged without any neurologic sequelae.

Local and systemic reactions after bee stings are common. Local reactions include a number of manifestations such as pain, itching, redness, burning, and local swelling. Systemic involvement, which includes symptoms of vomiting, diarrhea, dyspnea, generalized edema, acute renal failure, myocardial infarction, and cerebral infarction, is a rare manifestation [1,2]. Dechypirom and coworkers have reported that typical stroke syndromes developed between 2 hours and 2 days after bee stings [5]. Temizoz and coworkers [4] have reported 7 cases of wasp and bee stings that were associated with cerebral ischemia and exhibited neurologic complications including seizure, hemiparesis, aphasia, apraxia, and dysarthria. However, there are no reports of involuntary hyperkinetic movement disorders occurring after multiple bee stings. *Hemichorea* is defined as the presence of irregular, abrupt, and relatively rapid involuntary movements that are unilateral, that is, involving muscle groups on one side of the body. Poststroke hemichorea is an uncommon involuntary hyperkinetic disorder that involves unilateral body parts [6]. In a previous study, the incidence of poststroke hemichorea has been reported in 0.54% (27/5009 patients) of patients [7]. The

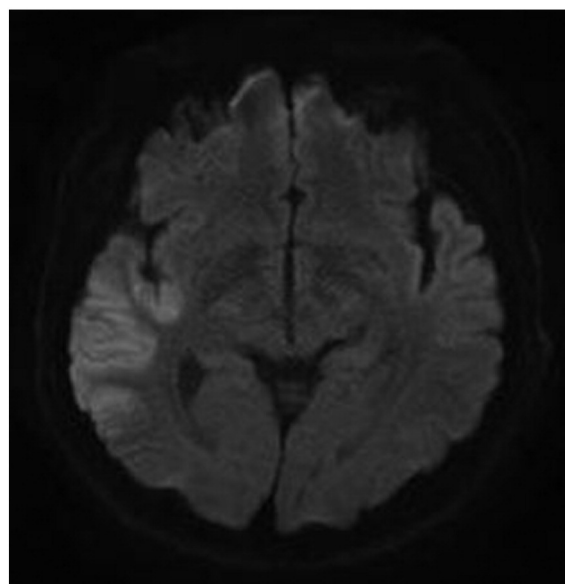


Fig. 1. Diffusion-weighted magnetic resonance imaging clearly demonstrated lesions in the right temporal lobe.

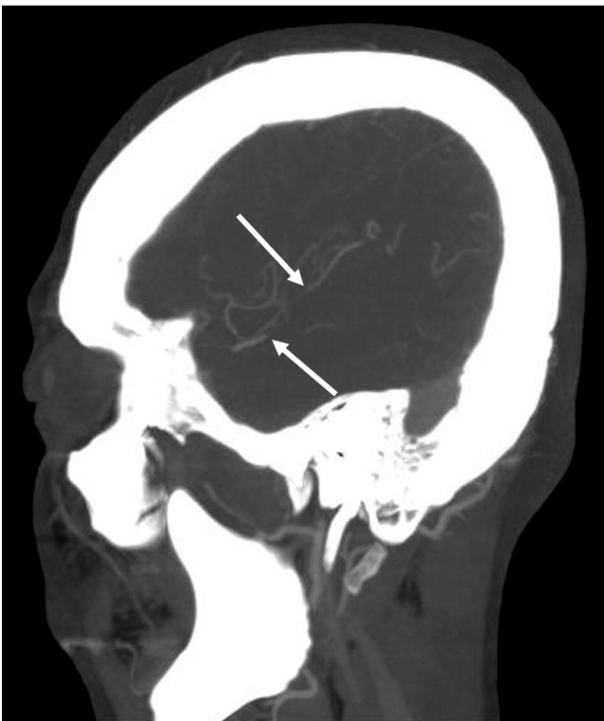


Fig. 2. Brain computed tomography angiography with contrast shows a right M2 inferior and superior division branch occlusion (white arrow).

hemichorea developed within 5 days of the ischemic stroke and usually on the day of the stroke. This observation supports the idea that poststroke hemichorea results from the stroke-induced acute functional dysregulation of the basal ganglia motor circuit rather than from restorative neuroplasticity [7,8]. Chung and coworkers [7] have reported brain lesions in poststroke hemichorea that were developed by lenticular lesions followed by subthalamic and cortical lesions. The pathophysiology of cerebral ischemic stroke by bee sting is unknown. The 5 major causes of cerebral ischemia are vascular thrombosis, cerebral embolism, hypotension, hypertensive hemorrhage, and hypoxia [4]. Similar to acute myocardial infarctions that occur after hymenoptera stings, it has been suggested that vasoconstriction is secondary to the mediators that are released after the sting; aggregation also contributes to the cerebral ischemia [9]. Bee venom itself contains histamine, thromboxane, leukotrienes, and other vasoactive and inflammatory mediators. Both thromboxane and leukotrienes have been shown to cause vasoconstriction and results in cerebral infarction [10].

We suggest that in our patient, the multiple bee stings caused hypotension (2 syncope episodes), vasoconstriction, and a prothrombotic state with subsequent ischemia that resulted in stroke and poststroke hemichorea. Hence, cerebral ischemic stroke should be suspected if patients complain of involuntary hyperkinetic movements after bee sting.

Jin Young An MD

Department of Internal Medicine, College of Medicine
Chungbuk National University, Cheongju, Korea

Ji Seon Kim MD

Department of Neurology, College of Medicine
Chungbuk National University, Cheongju, Korea

Jin Hong Min MD

Kyu Hong Han MD

Jun Ho Kang MD

Suk Woo Lee MD, PhD

Hoon Kim MD, PhD

Jung Soo Park MD

Department of Emergency Medicine, College of Medicine
Chungbuk National University, Cheongju, Korea

E-mail address: cpr@chungbuk.ac.kr

<http://dx.doi.org/10.1016/j.ajem.2013.09.024>

References

- [1] Crawley F, Schon F, Brown MM. Cerebral infarction: a rare complication of wasp sting. *J Neurol Neurosurg Psychiatry* 1999;66(4):550–1.
- [2] Reisman RE. Unusual reactions to insect stings. *Curr Opin Allergy Clin Immunol* 2005;5(4):355–8.
- [3] Viswanathan S, Muthu V, Singh AP, et al. Middle cerebral artery infarct following multiple bee stings. *J Stroke Cerebrovasc Dis* 2012;21(2):148–50.
- [4] Temizoz O, Celik Y, Asil T, et al. Stroke due to bee sting. *Neurologist* 2009;15(1):42–3.
- [5] Dechyapirom W, Cevik C, Nugent K. Concurrent acute coronary syndrome and ischemic stroke following multiple bee stings. *Int J Cardiol* 2011;151(2):e47–52.
- [6] Ghika-Schmid F, Ghika J, Regli F, et al. Hyperkinetic movement disorders during and after acute stroke: the Lausanne Stroke Registry. *J Neurol Sci* 1997;146(2):109–16.
- [7] Chung SJ, Im JH, Lee MC, et al. Hemichorea after stroke: clinical-radiological correlation. *J Neurol* 2004;251(6):725–9.
- [8] Krauss JK, Jankovic J. Head injury and posttraumatic movement disorders. *Neurosurgery* 2002;50(5):927–39.
- [9] Riggs JE, Ketonen LM, Wymer JP, et al. Acute and delayed cerebral infarction after wasp sting anaphylaxis. *Clin Neuropharmacol* 1994;17(4):384–8.
- [10] Schiffman JS, Tang RA, Ulysses E, et al. Bilateral ischaemic optic neuropathy and stroke after multiple bee stings. *Br J Ophthalmol* 2004;88(12):1596–8.