

## Mitochondrial myopathy, encephalopathy, lactic acidosis, and stroke-like episodes with acanthocytosis: a clinicopathological study of a unique case

M. Mukoyama, H. Kazui, N. Sunohara, M. Yoshida, I. Nonaka, and E. Satoyoshi

National Centre for Nervous, Mental and Muscular Disorders, 4-1-1, Ogawahigashimachi, Kodairashi, Tokyo, Japan 187

**Summary.** A case of a unique combination of mitochondrial myopathy, encephalopathy, lactic acidosis and stroke-like syndrome (MELAS) with acanthocytosis is reported. Neuropathological examination revealed pellagra-like change in Betz cells, brain-stem neurons and anterior horn cells as well as findings compatible with mitochondrial encephalomyopathies. Abnormal function of nicotinic acid-related enzymes could be the cause of the complicated clinicopathologic findings in this case. This is the first report of MELAS with acanthocytosis.

**Key words:** Mitochondrial encephalomyopathy – MELAS – Acanthocytosis – Pellagra – Ragged-red fibres

### Introduction

The concept of mitochondrial encephalomyopathies, introduced by Shapira et al. [13], includes several disease entities, such as Kearns-Shy syndrome, Alper's disease, trichopoliodystrophy, Zellweger syndrome and Canavan's disease. Recently, two conditions, myoclonic epilepsy associated with ragged-red fibres in the skeletal muscles (MERRF) [4] and mitochondrial myopathy, encephalopathy and lactic acidosis with stroke-like episodes (MELAS) [10], have been proposed as distinctive clinical syndromes. In these disorders, ragged-red fibres in the muscle, lactic acidosis and involvement of the central nervous system are always present, and a defect of some mitochondrial enzyme activities has been considered as the morphological and biochemical factor common to all these disorders [4, 10, 12, 13]. We have studied a sporadic case of MELAS with acanthocytosis, a combination that has not been previously reported.

### Case report

The patient had a normal pre- and perinatal history. Birth weight was 2900 g. Motor, language and mental development was delayed, however, and school performance was below average. He was the second of three children. There was no known consanguinity, and family history was not contributory. He was always thin and short. At age 10 years, he

started to have intermittent headache with nausea and vomiting, which continued for about 1 week. These episodes recurred once or twice a year. At age 14, he had myoclonus in his right limbs and then developed generalized tonic and clonic seizures. Anticonvulsants controlled the generalized convulsions, but myoclonus persisted in the right limbs. At age 15, he developed a right hemiparesis and an excessive aphasia of sudden onset. These symptoms improved gradually in the following several months but then episodes of unconsciousness without convulsions appeared. His intellectual performance and daily activities deteriorated by degrees. He became bedridden at age 18 and was admitted to the National Centre Hospital at age 20. On admission he was short and emaciated. Body length was 151 cm and weight 30.5 kg. Chest, heart and abdomen were normal. He was calm and apathetic, and did not speak of his own accord. He answered with a few words only to a repeated question. There was diffuse wasting and weakness of all limb muscles. Myoclonus was observed in his face, trunk and four limb muscles. Pain sensation looked normal. Reflexes were generally decreased. Babinski's sign was negative. Pupils were dilated with a sluggish light reaction. Funduscopic examination revealed bilateral optic atrophy without retinal degeneration. He had a slight hearing loss. There was no ptosis, ophthalmoplegia, nystagmus, ataxia or tremor.

Red blood cells were  $294 \times 10^4/\text{mm}^3$ , haematocrit 28.8%, haemoglobin 8.5 g/dl and white blood cells  $8,000/\text{mm}^3$ . About 20% of erythrocytes in the peripheral blood were acanthocytes (Fig. 1). Serum enzymes were normal except for CK, which was 105 units (normal, less than 75). Serum GOT, GPT and LDH were normal. EMG showed low-voltage and short-duration potentials. Motor nerve conduction velocities were normal. A CT scan showed multiple low-density areas in the brain with cortical atrophy and ventricular dilatation. EEG demonstrated diffuse slow (theta) wave background activity with focal sporadic sharp waves, mainly over the right parieto-occipital area. Abnormal waves associated with myoclonus were not found. Urinalysis, serum proteins, urea nitrogen, uric acid, serum electrolytes, including Ca and P, serum cholesterol and lipids, fasting blood sugar, liver function, amino acid content, including alanine in serum and urine, thyroid function, STS, Coomb's test, ECG, chest and skull radiographs and CSF examinations all were within normal limits.

In the venous blood that was obtained during resting state, lactate was 44.8 mg/dl (normal, 4–16) and pyruvate 2.31 mg/dl (normal 0.3–0.9). In the CSF, lactate was 95.8 mg/dl (normal,

10–20) and pyruvate 3.08 mg/dl (normal, 0.3–1.0). Venous lactate and pyruvate levels showed normal responses after ischaemic exercise. There were no abnormal changes in these values during an oral 50 g glucose tolerance test.

During this admission the patient had frequent myoclonus in the muscles of the face, trunk and extremities. General con-

vulsions appeared, associated with or without myoclonus. Clonazepam and valproic acid were temporarily effective for myoclonus and convulsions. Intravenous multivitamin therapy did not improve his symptoms. The patient died of pneumonia at age 21 years.

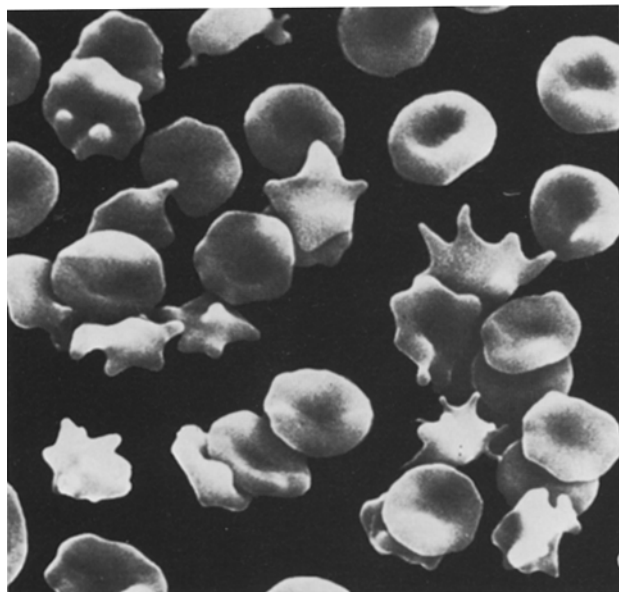
#### *Muscle biopsy study*

On light microscopy, the biceps brachii and quadriceps femoris muscles revealed marked variation in fibre size with an increase in the number of internal nuclei. Endomysial fibrosis was slight. With the modified Gomori trichrome stain, ragged-red fibres were present in 25% of all the fibres, mostly in type I fibres. The distribution of histochemical fibre types was preserved with the myosin ATPase stain. An electron microscopic study showed a prominent accumulation of abnormal mitochondria in the subsarcolemmal regions. Some mitochondria contained paracrystalline inclusions (Fig. 2).

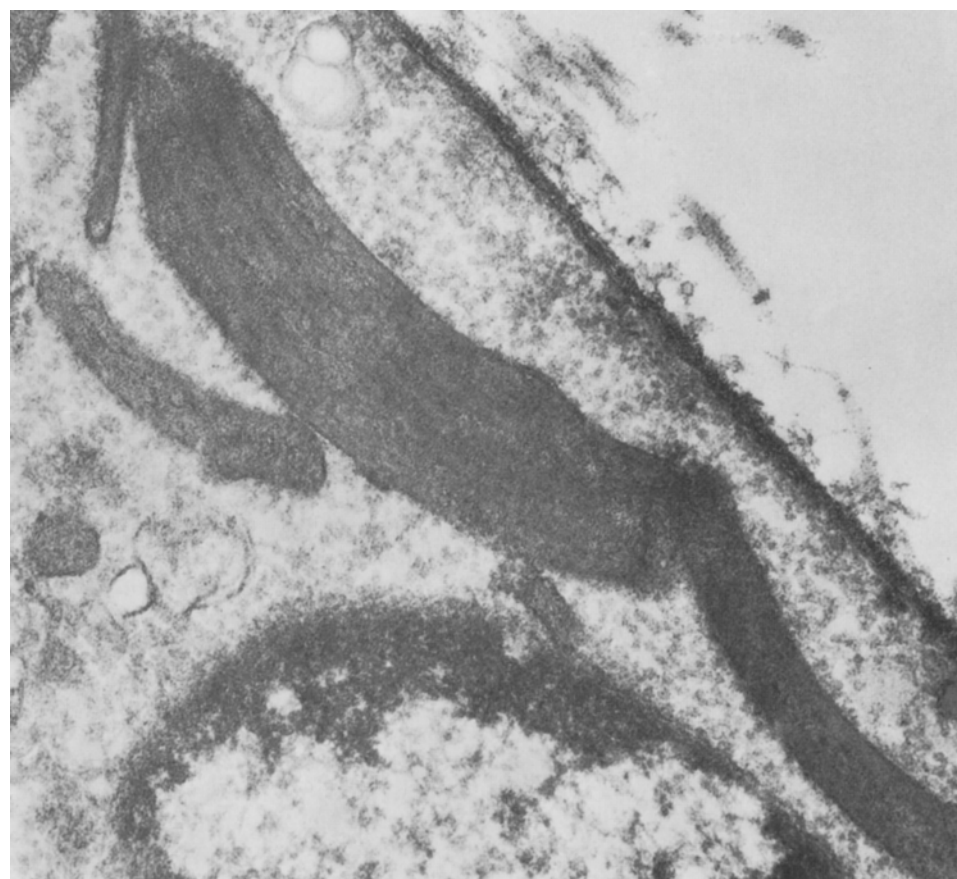The assay of mitochondrial enzymes demonstrated normal activities of pyruvate dehydrogenase complexes, pyruvate dehydrogenase phosphatase, and carnitine palmityl transferase.

#### *Autopsy*

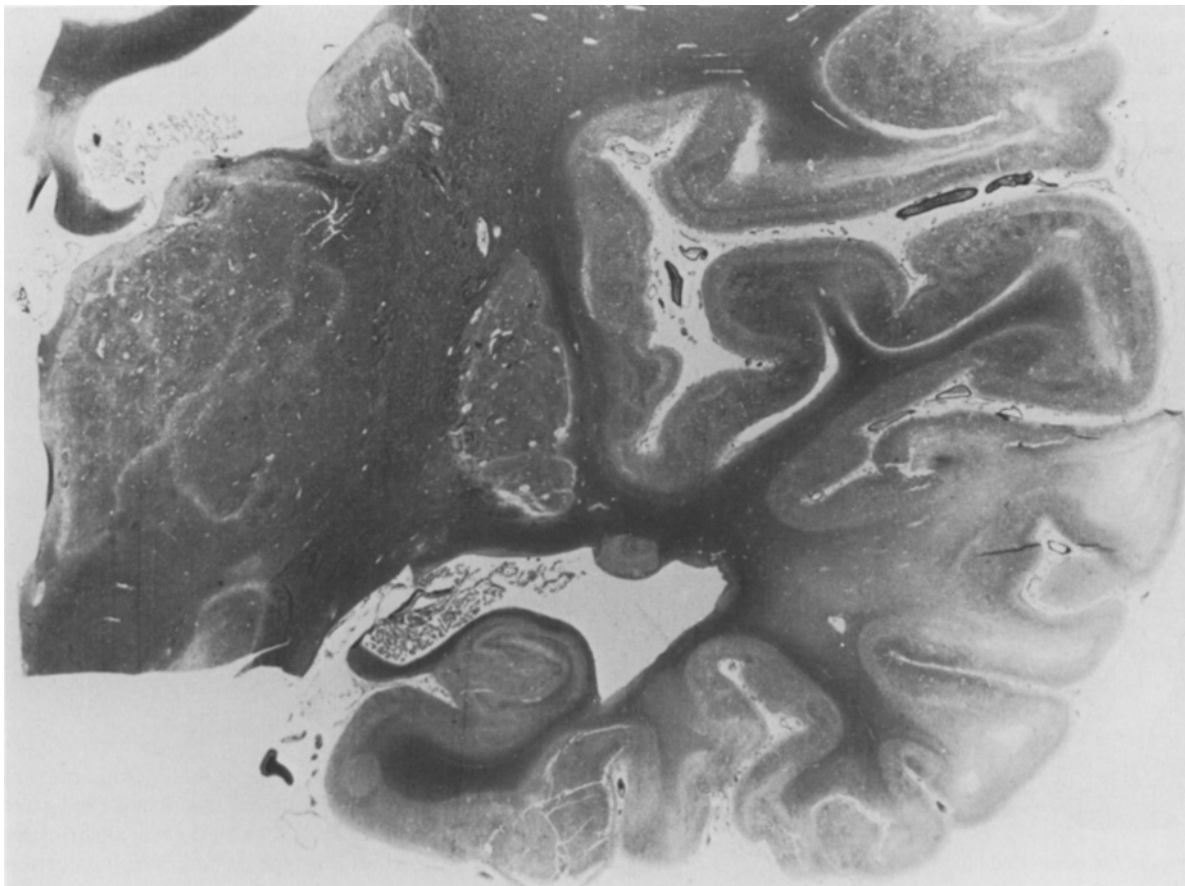
The cause of death was a bronchopneumonia. Bone marrow did not contain abnormal cells. The brain weighed 1060 g and was generally atrophic. Multiple, localized cortical shrinkage was observed in both frontal, temporal and occipital cortices



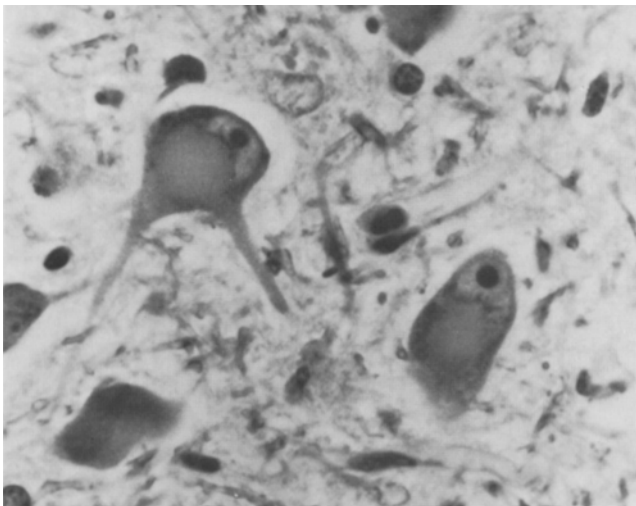
**Fig. 1.** Acanthocytes in the peripheral blood.  $\times 1,500$



**Fig. 2.** Mitochondria containing paracrystalline inclusions in biceps brachii muscle. Lead citrate and uranyl acetate,  $\times 19,800$



**Fig.3.** Multiple lesions of softening in the cerebral cortex, thalamus, internal capsule and basal ganglia. Bodian,  $\times 1.1$



**Fig.4.** Ballooning of perikarya and central chromatolysis observed in the neurons in pontine nuclei. Kluever-Barrera,  $\times 564$

with meningeal clouding. No arteriosclerotic plaques were found in the main brain blood vessels. Microscopic examination revealed scattered, solitary and continuous softening in the cerebral cortex (Fig.3). The size and age of the lesions were varied. The distribution of these lesions did not correspond to a vascular pattern. In addition to these soft lesions,

there were several areas with spongy alterations in the cerebral cortex where neuronal loss was prominent. Although adjacent subcortical white matter was involved, deep white matter appeared normal. Localized cerebral softening was also observed in the thalami, internal capsules and basal ganglia (Fig.3). In the cerebellum, Purkinje cells had focally disappeared. The dentate nuclei showed severe neuronal loss with astrogliosis and capillary proliferation. Fine or coarse calcium granules were deposited in the capillary walls of the globus pallidus and dentate nucleus on both sides.

The remaining Betz cells in the motor cortex, the neurons in oculomotor, pontine, hypoglossal and inferior olivary nuclei and the anterior horn cells showed ballooning of the perikarya and central chromatolysis (Fig.4). The optic nerves revealed moderate degeneration of nerve fibres and astrocytic gliosis. The blood vessels showed no inflammatory or atherosclerotic changes.

The pyramidal tracts and posterior columns in the spinal cord showed slight and diffuse degeneration with astroglial proliferation. The spinocerebellar tracts, however, were normal. Nerve cells in the dorsal root ganglia were moderately decreased and satellite cells were increased. The sciatic nerve showed a reduced number of nerve fibres with fibrosis.

With modified Gomori trichrome stain the slices of heart muscle disclosed ragged-red fibres, but those of the brain or the sciatic nerve did not show any red-staining materials. Electron microscopy revealed no accumulations or alterations of mitochondria in neurons or glial cells.

## Discussion

A patient is described with failure of growth, mental retardation, myoclonus, general convulsion and a stroke-like accident, who also showed high lactate and pyruvate levels in blood and CSF, acanthocytosis in the peripheral blood, ragged-red fibres in skeletal and heart muscles and multiple low-density areas on CT scan. Autopsy disclosed multiple areas of softening as well as spongy alterations in the cerebral cortex. From the clinicopathological findings, this case is considered to be an example of MELAS syndrome [10], and the presence of acanthocytosis in this case is unique.

Pavlakakis et al. [10] summarized two cases of MELAS with nine clinically similar cases in the literature: among them only three cases were examined by autopsy. According to these authors, the neuropathological findings of MELAS were similar to and overlapped with MERRF [4] and Kearns-Shy syndrome [2, 12], but focal cerebral softening and calcification of the basal ganglia were most prominent in MELAS. The present patient had multiple lesions of softening and spongy alterations in the cerebral cortex. These have been described in several reported cases of mitochondrial encephalopathies [5, 6, 12]. Our patient also had a high lactate and pyruvate content in CSF as well as in the blood, and so mitochondrial involvement in the brain was strongly suspected [5, 7, 9, 10, 13]. Modified Gomori trichrome stain and EM studies, however, failed to find morphological abnormalities of the brain mitochondria.

The present case had deposits of calcium granules in the capillary walls of the globus pallidus and dentate nucleus, but no hypoparathyroidism. Calcification in the basal ganglia, especially in the globus pallidus, has been described in cases of mitochondrial encephalomyopathy [1, 4, 5, 7, 13]. Kuriyama's case [7] had rather diffuse calcification in the caudate nuclei, pallidum, thalami, internal capsules and dentate nuclei. None of the cases reported so far have had hypoparathyroidism. The implications of this calcification are not clear.

Ballooning of the perikarya with central chromatolysis in the Betz cells, the neurons in the brain-stem and the anterior horn cells detected in this case resembled the pathological findings in pellagra because of their shape and distribution [3]. These findings have been described in the cases reported previously but without special comment [4, 7]. Our patient had no clinical symptoms of pellagra, such as light-sensitive dermatitis or glossitis, and there was no clinical improvement after intravenous vitamin B complex, including nicotinic acid. It is possible, however, that some metabolic disturbance of nicotinic acid-related enzymes, such as NADH-CoQ-reductase and NADH-cytochrome C reductase, exists. These enzymes work as an electron carrier in mitochondria and have been known to cause ragged-red fibres in cases of mitochondrial encephalomyopathy [6, 9–12]. An abnormality of these enzymes might produce pellagra-like changes in the CNS neurons and ragged-red fibres in the muscles. Analysis of several mitochondrial enzymes, such as pyruvate dehydrogenase complexes, pyruvate dehydrogenase phosphatase, and carnitine palmityl transferase, in the muscles did not reveal any specific abnormalities.

This case is unique because of the presence of both acanthocytosis and MELAS, a combination not previously described. Acanthocytosis has been reported in patients with several neuromuscular disorders, such as Bassen-Kornzweig syndrome [12], vitamin E deficiency [12], chorea acantho-

cytosis [8], motor neuron disease [14], and benign myopathy [15]. These disorders occur either sporadically or by inheritance. Red cell abnormalities with hypobetalipoproteinaemia can be found in the review of Croft et al. of 348 cases of ocular myopathy with neuropathic complications [2]. The underlying biochemical defect in these disorders remains undetermined, but there could be a generalized membrane abnormality [14–16]. There have been no studies that have suggested a metabolic disorder of nicotinic acid-related enzymes to be the pathogenesis of acanthocytosis co-existing with a neuromuscular disorder. In the X-linked McLeod syndrome, inherited deficiency of specific antigens in the erythrocyte surface has been reported to cause acanthocytes [15]. Yoshida et al. [16] demonstrated that an abnormal erythrocyte in Duchenne muscular dystrophy appeared only while the blood specimens were tested in high  $\text{Ca}^{++}$  solution. The patient in the present paper had a normal blood content of betalipoprotein and  $\text{Ca}^{++}$  and no family history of neuromuscular problems. Further studies will be necessary to elucidate the common factors which produce acanthocytosis associated with neuromuscular disorders.

**Acknowledgements.** This work was supported in part by grant no. 85-05 from the National Centre for Nervous, Mental, and Muscular Disorders of the Ministry of Health and Welfare, Japan. The authors thank Drs. Kenji Tojima and Yasuhiro Kuroda (Tokushima University) and Seiji Sugiyama (Nagoya City University), who assayed mitochondrial enzymes in the muscles; Dr. Thoru Yamada (Iowa University Hospital) and Mr. Masayo Watanabe (University of Kansas) for their assistance in the preparation of this manuscript.

## References

1. Bogousslavsky J, Perentes E, Deruaz JP, Regli F (1982) Mitochondrial myopathy and cardiomyopathy with neurodegenerative features and multiple brain infarcts. *J Neurol Sci* 55: 351–357
2. Croft PB, Cutting JC, Jewesbury ECO, Blackwood W, Mair WGP (1977) Ocular myopathy (progressive external ophthalmoplegia) with neuropathic complications. *Acta Neurol Scand* 55: 169–197
3. Duchen LW, Jacobs JM (1984) Nutritional deficiency and metabolic disorders. In: Adams JH, Corsellis JAN, Duchen LW (eds) *Greenfield's neuropathology*, 4th edn. Arnold, London, pp 573–626
4. Fukuhara N, Tokiguchi S, Shirakawa K, Tsubaki T (1980) Myoclonus epilepsy associated with ragged-red fibers (mitochondrial abnormalities): disease entity or a syndrome? *J Neurol Sci* 47: 117–133
5. Hart ZH, Chang CH, Perrin EVD, Neerunjun JS, Ayyar R (1977) Familial poliodystrophy, mitochondrial myopathy, and lactate acidemia. *Arch Neurol* 34: 180–185
6. Holliday PL, Climie ARW, Gilroy J, Mahmud MZ (1983) Mitochondrial myopathy and encephalopathy: three cases. A deficiency of NADH-CoQ dehydrogenase. *Neurology (Cleveland)* 33: 1619–1622
7. Kuriyama M, Umezaki H, Fukuda Y, Osame M, Koike K, Tateishi J, Igata A (1984) Mitochondrial encephalomyopathy with lactate-pyruvate elevation and brain infarctions. *Neurology (Cleveland)* 34: 72–77
8. Levine IM, Estes JW, Looney JM (1968) Hereditary neurological disease with acanthocytosis. A new syndrome. *Arch Neurol* 19: 403–409
9. Morgan-Hughes JA, Hayes DJ, Clark JB, Landon DN, Swash M, Stark RJ, Rudge P (1982) Mitochondrial encephalomyopathies. Biochemical studies in two cases revealing defects in the respiratory chain. *Brain* 105: 553–582

10. Pavlakis SG, Phillips PC, DiMauro S, De Vivo DC, Rowland LP (1984) Mitochondrial myopathy, encephalopathy, lactic acidosis, and strokelike episodes: a distinctive clinical syndrome. *Ann Neurol* 16:481-488
11. Rigges JE, Schochet SS Jr, Fakadej AV, Papadimitriou A, DiMauro S, Crosby TW, Gutmann L, Moxley RT III (1984) Mitochondrial encephalomyopathy with decreased succinate-cytochrome c reductase activity. *Neurology (Cleveland)* 34:48-53
12. Rowland LP (1983) Molecular genetics, pseudogenetics, and clinical neurology. *Neurology (Cleveland)* 33:1179-1195
13. Shapira Y, Harel S, Russell A (1977) Mitochondrial encephalomyopathies: a group of neuromuscular disorders with defects in oxidative metabolism. *Isr J Med Sci* 13:161-164
14. Spitz MC, Jankovic J, Killian JM (1985) Familial tic disorder, parkinsonism, motor neuron disease, and acanthocytosis: a new syndrome. *Neurology (Cleveland)* 35:366-370
15. Swash M, Schwartz MS, Carter ND, Heath R, Leak M, Roger KLL (1983) Benign X-linked myopathy with acanthocytes (McLeod syndrome). Its relationship to X-linked muscular dystrophy. *Brain* 106:717-733
16. Yoshida M, Ando K, Satoyoshi E (1983) Abnormalities of erythrocytes in Duchenne muscular dystrophy. *Ann Neurol* 13:649-653

Received October 1, 1985 / Accepted November 27, 1985