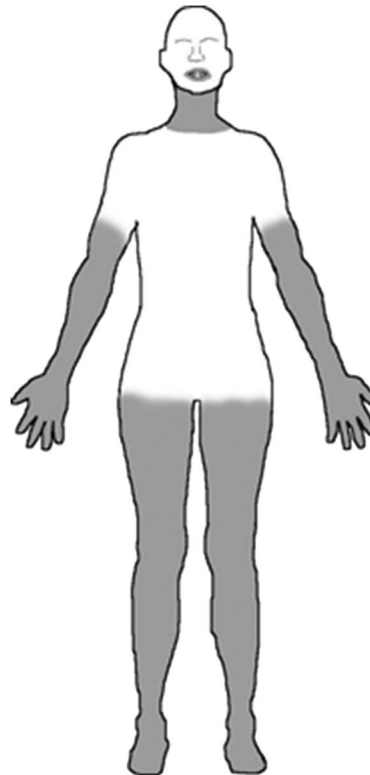
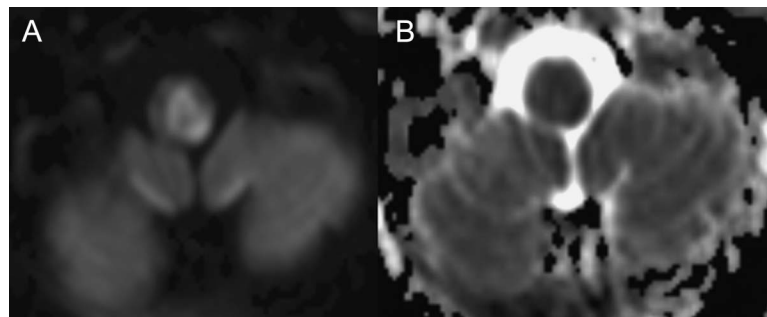


# Medial medullary infarction with central sparing

**Figure 1** Shaded areas indicate regions of decreased sensation



**Figure 2** Brain MRI



(A) Axial diffusion-weighted imaging and (B) apparent diffusion coefficient mapping show a ring-like area of ischemia involving the medial medulla with central sparing.

A 35-year-old woman had cardiac arrest requiring treatment with a left ventricular assist device. After regaining consciousness, examination revealed upbeat nystagmus, otherwise normal bulbar function, left arm dysmetria, and numbness periorally and in areas she described as “a turtleneck of numbness with a T-shirt of sensation” (figure 1).

MRI showed diffusion restriction in a ring-like pattern in the medial medulla (figure 2), a probable embolic infarction given the clinical history. This correlated with the patient's preserved truncal sensation, since in the medullary portion of the medial lemniscus, truncal fibers are positioned centrally, between fibers from the lower extremities anteriorly and upper extremities posteriorly.<sup>1</sup> In contrast to Dejerine syndrome, the hypoglossal nucleus was spared. Upbeating nystagmus and left arm dysmetria were consistent with involvement of the nucleus intercalatus<sup>2</sup> and the cuneocerebellar tract, respectively.

*Davis C. Ryman, MD, PhD, Yo-El S. Ju, MD*

From Washington University School of Medicine, St Louis, MO.

*Author contributions:* Dr. Ryman: drafting/revising the manuscript for content, acquisition of data, analysis or interpretation of data. Dr. Ju: drafting/revising the manuscript for content, acquisition of data, analysis or interpretation of data.

*Study funding:* No targeted funding reported.

*Disclosure:* The authors report no disclosures relevant to the manuscript. Go to Neurology.org for full disclosures.

*Correspondence to Dr. Ryman:* rymand@neuro.wustl.edu

1. Kim JS, Koh JY, Lee JH. Medial medullary infarction with restricted sensory symptom. *Eur Neurol* 1998;39:174–177.
2. Saito T, Aizawa H, Sawada J, Katayama T, Hasebe N. Lesion of the nucleus intercalatus in primary position upbeat nystagmus. *Arch Neurol* 2010;67:1403–1404.

## **NeuroImages Are Free at [www.neurology.org](http://www.neurology.org)!**

All *Neurology*<sup>®</sup> *NeuroImages* can now be freely accessed on the *Neurology* Web site. See them at [www.neurology.org](http://www.neurology.org), where you can also sign up for journal email alerts and check out other online features, including the Resident & Fellow section, *Neurology: Clinical Practice*, and the weekly *Neurology* Podcasts.