



Clinical letter

Complex visual hallucinations as the sole manifestation of symptomatic temporo-occipital lobe epilepsy due to old intracerebral hemorrhage



Yuki Sakamoto, Rieko Suzuki*, Tomoyuki Ohara, Tetsuya Miyagi, Masato Osaki, Kazutaka Nishimura, Kazunori Toyoda

Department of Cerebrovascular Medicine, National Cerebral and Cardiovascular Center, Suita, Japan

ARTICLE INFO

Article history:

Received 4 August 2013

Received in revised form 31 October 2013

Accepted 1 November 2013

1. Introduction

Complex visual hallucinations in a blinded visual field are an under-appreciated phenomenon.¹ Both a stimulating phenomenon and a release phenomenon have been suggested as explanations for these hallucinations. However, the mechanisms of complex visual hallucinations in patients with visual field defects due to intracranial diseases are still controversial.¹ A patient with complex visual hallucinations in a quadrantanopic visual field caused by symptomatic epilepsy after cerebral hemorrhage is reported.

2. Case presentation

A 70-year-old, right-handed man was admitted to our hospital with a two-day history of repeated complex visual hallucinations. He had a history of intracerebral hemorrhage (ICH) in the right parietal lobe one year previously which had left him with left lower quadrantanopia. One night, he noticed that he saw a human face in his left quadrantanopic field when he watched a soccer game on television. He immediately realized that the man was a soccer player he had seen on the television a few minutes earlier. The hallucinatory image faded gradually and finally disappeared after about one minute. The next morning, he saw a stooping woman in his defective field whilst on a bus to go

shopping. He recognized that the woman was an image of his wife in her younger days. The false image disappeared after a few minutes. He visited our hospital because hallucinations lasting a few minutes occurred repeatedly, as frequently as forty times a day. On admission, he was alert, with a Mini-Mental State Examination score of 30. He had left lower quadrantanopia and mild constructional apraxia. General physical and neurological examinations were otherwise normal. The hallucinatory images were always human with a surrounding scene, and the human was sometimes only a face and sometimes the whole body. Hallucinations could involve seeing either one or a few people. The hallucinatory human and surrounding scenes were always still and pale-colored, and the image was moving from top to bottom slowly or shaking slightly, like “a gliding portrait in the blinded field”. The patient always recognized that the image was false, and he did not feel fear or experience a sense that the image was real. He often realized who the hallucinatory human when he saw the scene. He saw a range of hallucinatory images, such as his wife in her youth, his old colleagues enjoying a picnic under the cherry blossoms (a scene he had seen a few years previously), and our ward nurse. The image disappeared when saccadic eye movement were conducted, though smooth pursuit did not remove the hallucinatory images. There were no other semiological signs more typically associated with epileptic seizures like automatism or impairment of consciousness.

On admission, magnetic resonance imaging examinations revealed slight hyperintensity in the right temporo-occipital lobe on diffusion-weighted imaging (Fig. 1A, arrow) and fluid-attenuated inversion recovery (FLAIR, Fig. 1B). Single photon emission computed tomography (SPECT) using intravenous injection of 99mTc-labeled hexamethylpropyleneamine oxime (99mTc-PAO) demonstrated increased 99mTc-PAO uptakes in the lesion (Fig. 1C). FLAIR showed an old ICH in the right parieto-occipital lobe (Fig. 1D, arrowhead). Surface electroencephalography (EEG) showed periodic lateralized epileptiform discharges (PLEDs) in the right temporo-occipital lobe (Fig. 2). Nonconvulsive status epilepticus due to old ICH was diagnosed. The repeated hallucinations were not perceived and PLEDs were not observed on EEG after intravenous diazepam, and the visual seizures had not recurred after 6 months of follow-up with oral carbamazepine.

* Corresponding author at: Department of Cerebrovascular Medicine, National Cerebral and Cardiovascular Center, 5-7-1, Fujishiro-dai, Suita, Osaka 565-8565, Japan. Tel.: +81 6 6833 5012; fax: +81 6 6835 5267.

E-mail address: rsuzuki@ncvc.go.jp (R. Suzuki).

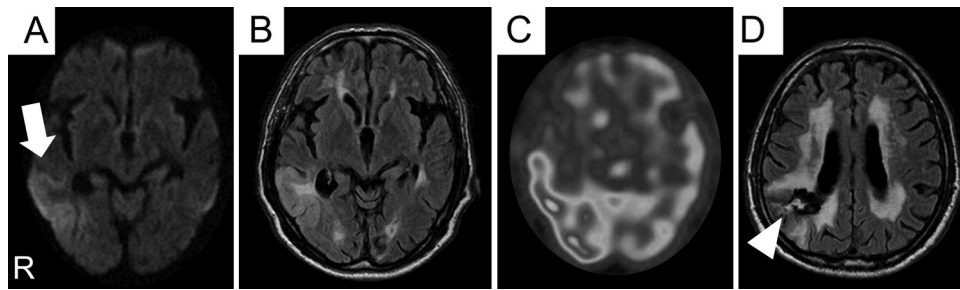


Fig. 1. MRI and SPECT on admission. MRI shows slight hyperintensity in the right temporo-occipital lobe on DWI (A, arrow) and FLAIR (B). SPECT using intravenous injection of ^{99m}Tc -PAO shows increased ^{99m}Tc -PAO uptake in the lesion (C). FLAIR shows old ICH in the right parieto-occipital lobe (D, arrowhead).

3. Discussion

Intracranial lesions can cause visual hallucinations in the defective visual field.¹ Lesions in the occipital lobe (primary visual cortex) are considered to result in simple visual hallucination,² and the lesions responsible for complex visual hallucination are assumed to be the temporo-occipital border region (visual association cortex).³ Complex visual hallucinations in patients with visual field defects have been considered to consist of at least two types of phenomena, stimulating or release phenomena. A stimulating phenomenon refers to irritative processes in the visual association cortex, and a release phenomenon implies disinhibition of the visual association cortex due to loss of a normally

inhibiting visual pathway, both resulting in generating discharges falsely interpreted as due to sensory inputs. However, the mechanisms of complex visual hallucinations in patients with a visual field defect due to intracranial diseases are still controversial,¹ probably because patients having intracranial lesions are prone to develop symptomatic epilepsy compared to those with a visual field loss from disorders in the extracranial optical tract. In the present case, SPECT showed hyperperfusion related to repetitive ictal sharp wave discharges seen over temporo-occipital leads in EEG. The history of a delay of over one year between the occurrence of visual hallucinations and intracerebral bleeding, as well as the short duration of the visual phenomena, support an epileptic origin rather than a release phenomenon as the probable

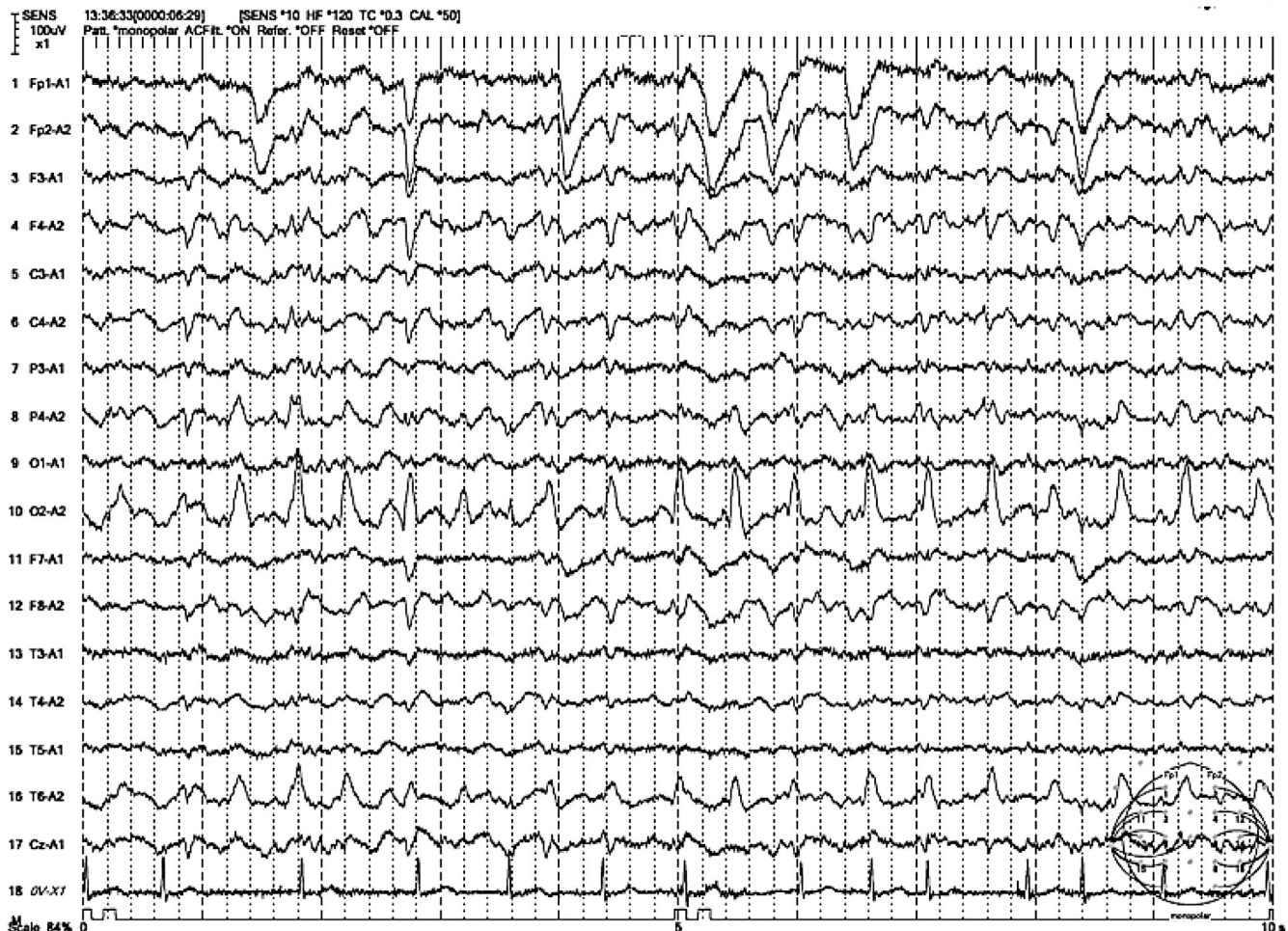

Fig. 2. EEG on admission. EEG shows periodic lateralized epileptiform discharges in the right temporo-occipital lobe.

underlying cause in case discussed here. Indeed, case series of release hallucinations showed that these occurred with a much shorter latency period after the original injury (a few days).¹ Complex visual hallucination in a blinded visual field can occur due to focal symptomatic epilepsy alone.

In the present case, complex visual hallucinations were the only presentation of symptomatic epilepsy. Stimulating and release phenomena were presumed to be distinguished by the duration of the hallucinatory experience, stereotyped hallucination or not, and associated clinical characteristics.¹ The duration of hallucinations in the present case was relatively short, a few minutes, but the variety of hallucinated images was considerable. Complex visual hallucination due to an irritative processes may be non-stereotyped and the sole manifestation of seizure. This may be important because early seizures occur in around 5% of acute ischemic stroke patients,⁴ and complex visual hallucinations without associated characteristics suggestive of epilepsy in such patients may be misunderstood as release phenomena. Recognizing the irritative process in these patients seems to be significant because some

are associated with persistent neurological deficits or develops recurrent seizures (epilepsy). Acute stroke patients with visual hallucinations should undergo EEG even with hallucinations are non-stereotyped and occur in the absence of more typical seizure manifestations.

Conflict of interest statement

None declared.

References

1. Kolmel HW. Complex visual hallucinations in the hemianopic field. *J Neurol Neurosurg Psychiatry* 1985;**48**:29–38.
2. Freiman TM, Surges R, Vougioukas VI, Hubbe U, Talazko J, Zentner J, et al. Complex visual hallucinations (Charles Bonnet syndrome) in visual field defects following cerebral surgery. Report of four cases. *J Neurosurg* 2004;**101**:846–53.
3. Kasper BS, Kasper EM, Pauli E, Stefan H. Phenomenology of hallucinations, illusions, and delusions as part of seizure semiology. *Epilepsy Behav* 2010;**18**:13–23.
4. Kilpatrick CJ, Davis SM, Tress BM, Rossiter SC, Hopper JL, Vandendriesen ML. Epileptic seizures in acute stroke. *Arch Neurol* 1990;**47**:157–60.