

SHORT REPORT

Air-embolism and cerebral ischaemia following epidural hydrogen peroxide irrigation in a closed lumbar cavity

Prasanna S. Patankar^{1,2}, Shashank S. Joshi¹ & Kishor A. Choudhari^{1,3}

¹Department of Neurosurgery, Sevenhills Hospital, Andheri (East), Mumbai, India, ²Department of Neurosurgery, Lokmanya Tilak Medical College, Sion, Mumbai, India, and ³Department of Neurosurgery, Regional Neurosciences Unit, Royal Victoria Hospital, Belfast, UK

Abstract

Authors report a case of air-embolism and subsequent ischaemic damage to the brain following intra-operative irrigation with hydrogen peroxide within a closed cavity of a spinal cold abscess of tuberculous origin. Copious amount of undiluted hydrogen peroxide irrigation was deployed under moderate pressure to clean-up the abscess cavity. Post-operatively, the patient developed seizures followed by clinical and radiological features of brain ischaemia ultimately resulting in a fatal outcome. The authors reflect on the events, review the relevant literature regarding intra-operative use of hydrogen peroxide in cranio-spinal procedures, outline mechanism of its actions, and highlight its disadvantages and potential complications.

Keywords: cold abscess; hydrogen peroxide; intra-operative irrigation; ischaemic brain damage; vasospasm

Introduction

Hydrogen peroxide (H₂O₂) is commonly used in Neurosurgery as a time-tested haemostatic agent. It is especially useful in arresting capillary and venous oozing in the tumour-beds as well as in abscess cavities where usual bipolar coagulation can be cumbersome and less effective. When H₂O₂ comes in contact with exposed blood or blood vessels it generates nascent oxygen, water and heat. Generated heat and nascent oxygen stimulates primary hemostasis, that is, platelet aggregation which potentiates hemostasis.¹ Its action on blood vessels depends on amount of catalase released by the endothelium. Authors illustrate a case where intra-operative irrigation of 2% v/w H₂O₂ resulted in a fatal outcome due to air embolism and reactive vasospasm leading to severe post-operative cerebral ischaemia.

Case report

A 65-year-old man presented with low-back pain followed by progressive paraparesis. He underwent decompression

of spinal canal and fusion in the form of laminectomy and fixation using trans-pedicular screws and rods for a tuberculous spine affecting throaco-lumbar region. Immediate post-operative course was uneventful with excellent neurological recovery. Three months later he presented with a fluctuant swelling over his back at the site of previous scar indicating formation of the cold abscess. He had no neurological complaints. On re-exploration of the lower part of the original incision, there was a subcutaneous cavity containing pus that communicated with the operative area through a small defect in the lumbar fascia (Fig. 1). After evacuating the pus, thorough and forceful wash-out of the abscess cavity was carried using undiluted 2% v/w H₂O₂. Dura appeared to be intact. As there were no signs of acute inflammation, the implants were not removed. The procedure was uneventful. Patient recovered rather slowly from general anaesthesia and went on to have repeated generalised tonic clonic seizures over next 24 h with further deterioration in the level of sensorium. A CT scan brain showed pneumo-encephalus involving ventricles and CSF cisterns (Fig. 2A). Despite intensive-care management, over next 48 h, he continued to deteriorate and became comatose. A follow-up CT brain showed multiple diffuse infarcts involving deep white matter (Fig. 2B). He did not recover and succumbed a few days later. No post-mortem could be carried out.

Discussion

H₂O₂ is a widely used intra-operative chemical haemostatic and anti-bacterial agent in neurosurgical procedures.¹ Postulated mechanisms for its haemostatic effect include the following:

- i) Release of nascent oxygen by decomposition of H₂O₂ producing foam which causes occlusion of the rent in the vessel wall thereby producing haemostasis.
- ii) Initiation of a thermophilic reaction which promotes vasoconstriction and stimulates thrombosis.

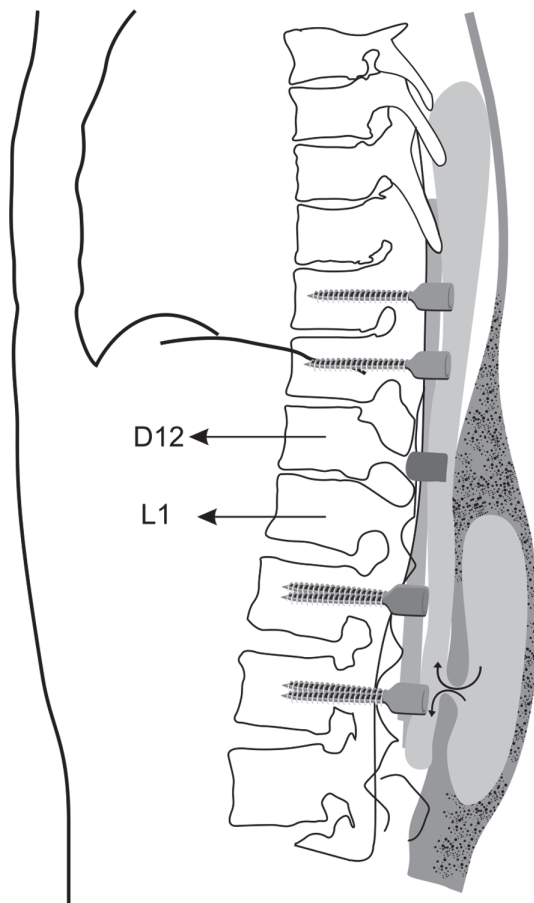


Fig. 1. Schematic diagram showing the dumb-bell shaped abscess cavity in relation to the spinal column.

- iii) H₂O₂, with its foaming effect, can exert mechanical pressure and enhance haemostasis.
- iv) In addition to its direct haemostatic effect, H₂O₂, by its virtue of increasing the permeability of endothelial lining, is said to transgress inside the vessel and further facilitate haemostasis.¹

In most clinical situations, H₂O₂ does not cause any major side-effects even when used undiluted on raw brain or spinal cord surface. H₂O₂ is in fact an indigenous metabolite found in the different tissues of the human body that is removed from the system by rapid decomposition into water and nascent oxygen by a system of enzymes called 'catalase'.¹ It is estimated that approximately 1 ml of H₂O₂ liberates 10 ml of nascent oxygen.² The catalase enzymes react with H₂O₂ and similar other superoxide molecules and preserves cell membrane integrity thereby maintaining the *milieu interior*. When used at lower concentration and in smaller amounts, the enzyme catalase is able to effectively decompose H₂O₂ thereby preventing any major side-effects from its use.

H₂O₂, however, is not without its own complications. Some of these are as follows:

- i) H₂O₂ can disrupt intact blood brain barrier (BBB).¹ Some studies suggest that excessive H₂O₂, when under pressure, may result in production of peroxynitrite which endothelium cannot metabolise rapidly. This may potentially result in disruption of endothelial lining and subsequent air-embolism.¹

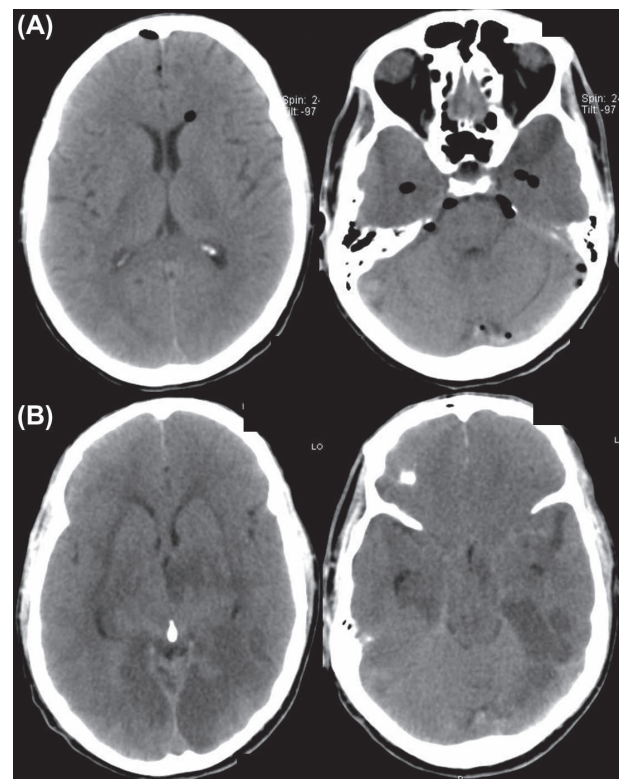


Fig. 2. Early CT scan showing post-operative cerebral pneumocephalus (2A), and 72-h CT scan showing generalised ischaemic changes (2B).

- ii) Vasoconstriction resulting from chemical and mechanical effects of H₂O₂ may be counterproductive as, if it affects small perforators supplying the deeper parts of the cerebrum or the brain stem, it can cause ischaemic brain damage.¹
- iii) H₂O₂ has been found to permeate through intact cell membranes and even by the mechanism of facilitated diffusion using water channels (aquaporins) situated within the cell membranes.¹ In experimental studies, it has been observed to have caused significant damage to arachnoid, pia, and brain tissue up to the depth of 1 mm when applied directly to brain surface.³
- iv) H₂O₂ is known to cross intact pia and has extreme affection for the blood vessels.¹ However, in smaller quantities, it is not normally known to damage vessels and their endothelium.³
- v) With use of copious amount of H₂O₂ there is a risk of air embolism. There are sporadic case reports where intra-operative usage of H₂O₂ for spinal surgeries and even after scalp infiltration have resulted venous air embolism causing metabolic disturbances.¹

In our patient, 2% H₂O₂ was instilled in a dumb-bell shaped, partially closed, abscess cavity under moderate pressure. It probably produced abundant nascent oxygen within the deeper part of the cavity under pressure. It is likely that the nascent oxygen and/or H₂O₂ might have transgressed into the valveless epidural venous plexuses causing air-embolism, and subsequent cerebral ischaemia. A possibility of an unintended dural breach during the surgical intervention potentiating under-pressure transgression of nascent oxygen and intact H₂O₂ intra-durally and subsequent direct damage to neural

tissue could not be ruled out. Arachnoid and pia are known to be permissible to H_2O_2 /nascent oxygen and may have caused small perforators to undergo spasm and thrombosis.^{1,3}

We believe that the complication in our case probably resulted from an intra-operative technical error of using excess amount of undiluted H_2O_2 with moderate force when irrigating a closed cavity. We do not consider that our experience and the literature to date provide adequate evidence for stopping its use in neurosurgical procedures. However, reflecting on the events in our case, we advocate cautious use of H_2O_2 in closed cavities wherein nascent oxygen/ H_2O_2 under pressure may be driven inside the subarachnoid spaces or in the blood vessels. Accordingly, we have continued to use H_2O_2 in cranio-spinal surgeries as a haemostatic and anti-bacterial agent, albeit more carefully than ever before.

Declaration of interest: The authors report no declarations of interests. The authors alone are responsible for the content and writing of the paper. The authors confirm that patient consent has been obtained in the illustrative case.

References

1. Mut M, Yemisci M, Gursoy-Ozdemir Y, Ture U. Hydrogen peroxide-induced stroke: elucidation of the mechanism in vivo laboratory investigation. *J Neurosurg* 2009;110:94-100.
2. Yang ZW, Zheng T, Zhang A, Altura BT, Altura BM. Mechanisms of hydrogen peroxide-induced contraction of rat aorta. *Eur J Pharmacol* 1998;344:169-81.
3. Mesiwala AH, Farrell L, Santiago P, Ghatan S, Silbergeld DL. The effects of hydrogen peroxide on brain and brain tumors. *Surg Neurol* 2003;59:398-407.

Copyright of British Journal of Neurosurgery is the property of Taylor & Francis Ltd and its content may not be copied or emailed to multiple sites or posted to a listserv without the copyright holder's express written permission. However, users may print, download, or email articles for individual use.