

A 'Posterior Circulation Stroke' that Benefits from Vitamins

To the Editor:

A 75-year-old woman was admitted for somnolence and confusion. She had been treated for hypertension and hyperlipidemia. One year before, she had been hospitalized for a mild right ataxic hemiparesis attributed to a lacunar stroke and received aspirin 100 mg/day. For the past 6 months, she regularly complained about gastric discomfort and bloating, which was attributed to the aspirin intake. As a consequence of her gastric problems and her decreasing appetite, her food intake was very limited. During a call, 24 hours before admission, she complained about nausea and vomiting for the past 2 days; she felt dizzy and staggered. The morning after, she would not answer the phone and was found in a lethargic state in bed.

On admission, she had sinus tachycardia, a blood pressure of 150/90 mm Hg, and a temperature of 37°C. She was

unable to stand or walk. She was very somnolent, but she would open her eyes upon intense verbal stimulation, following simple commands and uttering a few dysarthric words. She had no signs of meningism. Her pupils were symmetric and reactive to light, but she presented upper vertical gaze paresis, mild bilateral abducens nerve paresis, and intense gaze-evoked nystagmus. She had mild paresis and ataxia in all limbs, and the plantar response was bilaterally indifferent. Apart from moderate hypochromic microcytic anemia and blood glucose of 3.4 mmol/L, the laboratory results were unremarkable. Due to the impending hypoglycemia, she was administered 500 mL of dextrose water 10% followed by normal saline. A nonenhanced brain computed tomography scan was normal. She was admitted to the Internal Medicine department with a presumed diagnosis of "posterior circulation stroke/top of the basilar syndrome." Because the onset of symptoms was unknown, intravenous thrombolysis was not performed and the patient was treated conservatively with 325 mg of aspirin via a nasogastric tube. Within 12 hours, she became deeply lethargic, progressed to near-complete external ophthalmoplegia, and would withdraw the limbs only upon painful stimulation. A brain magnetic resonance imaging (MRI) scan and MR angiography were performed with the indication of "basilar artery occlusion." The MRI revealed extensive hyperintensities of the medial thalami, the hypothalamus, the mammillary bodies, the periaqueductal gray matter, and the floor of the fourth ventricle, compatible

Funding: None.

Conflict of Interest: None.

Authorship: All authors had access to the data and a role in writing the manuscript.

Requests for reprints should be addressed to Theodoros Karapanayiotides, PhD, Oikismos Filothei, 57001 Nea Raïdestos, Thessaloniki, Greece.

E-mail address: tkarapanayiotides@yahoo.gr or theonev@ath.forthnet.gr

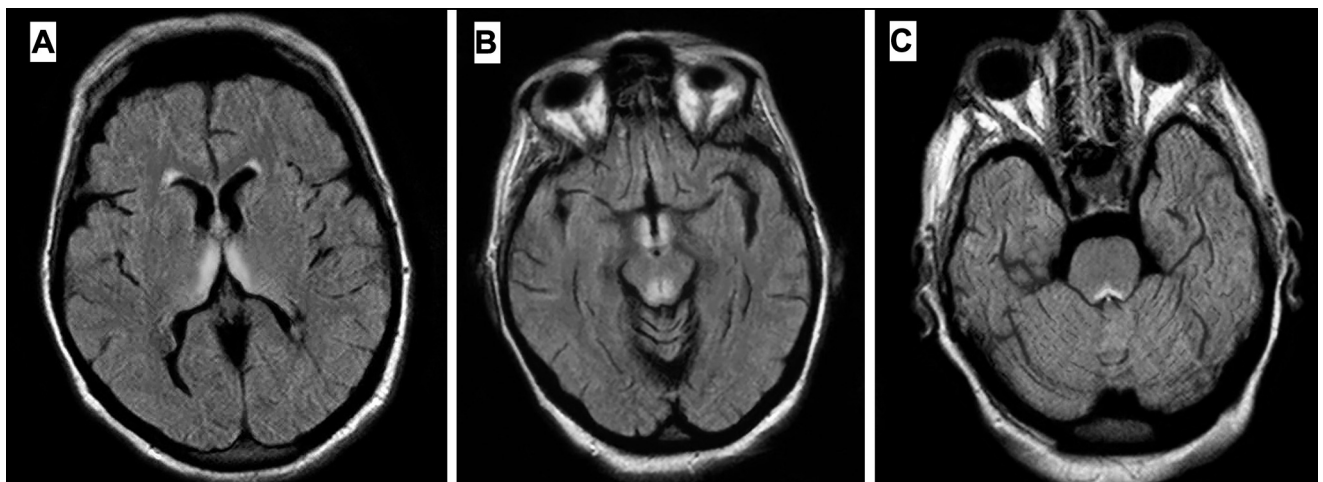


Figure Brain magnetic resonance imaging scan (fluid-attenuated inversion recovery [FLAIR] sequence). Hyperintense lesions are seen in the medial thalami (A); the periaqueductal area, the hypothalamus, and the mammillary bodies (B); and the floor of the fourth ventricle (C).

with an advanced Wernicke encephalopathy (**Figure**).¹ She was treated immediately with high-dose intravenous thiamine and complex B vitamins. Over the next week, she gradually regained consciousness, and the disorders of ocular motility resolved, apart from a moderate gaze-evoked nystagmus. Three months later she was able to look after herself again, despite suffering from a moderate amnesic syndrome.

Wernicke encephalopathy, the consequence of thiamine deficiency, is characterized by disorders of ocular motility, gait ataxia, and disturbances of consciousness and mentation.² The same triad of signs is encountered commonly in occlusion of the rostral basilar artery.³ Most emergency physicians recognize a catastrophe such as basilar occlusion but are less aware of Wernicke encephalopathy, especially in a setting of alcohol nonuse. In our patient, in a setting of thiamine deficiency due to prolonged starvation, vomiting precipitated the encephalopathy. The initial wrong diagnosis, also driven by the prior vascular history, was followed by glucose administration that exacerbated the encephalopathy, underscoring the necessity of concomitant administration of thiamine in comatose patients. As economic crisis in Greece flares up, we expect an increase of Wernicke encephalopathy among malnourished people.

Physicians should be alert for this posterior circulation stroke mimic, as inadvertent use of intravenous thrombolysis may be detrimental.

Theodoros Karapanayiotides, PhD^a

Athanasia Anastasiou, PhD^b

Nikolaos Bampas, MD^b

Nikolaos Grigoriadis, PhD^a

Dimitrios Karacostas, PhD^a

^a^{2nd} Department of Neurology

Aristotelian University of Thessaloniki

AHEPA University Hospital

Thessaloniki, Greece

^bDepartment of Radiology

Hippokrateion Hospital

Thessaloniki, Greece

<http://dx.doi.org/10.1016/j.amjmed.2013.10.007>

References

1. Karapanayiotides T, Zaloni I, Thomaidis T. Delayed development of Wernicke encephalopathy after gastrectomy. *Arch Neurol*. 2006;63:1026-1027.
2. Sechi G, Serra A. Wernicke's encephalopathy: new clinical settings and recent advances in diagnosis and management. *Lancet Neurol*. 2007;6:442-455.
3. Caplan LR. "Top of the basilar" syndrome. *Neurology*. 1980;30:72-79.