

SHORT REPORT

Diffuse cerebral vasospasm following resection of a hypoglossal schwannoma in a child

Fardad T. Afshari¹, James J. Fitzgerald¹, J. Nicholas Higgins², Matthew R. Garnett¹, Helen M. Fernandes¹ & Thomas Santarius¹

¹Department of Neurosurgery, Addenbrooke's Hospital, University of Cambridge, Cambridge, UK, and ²Department of Neuroradiology, Addenbrooke's Hospital, University of Cambridge, Cambridge, UK

Abstract

Diffuse cerebral vasospasm is a rare complication following tumour resection. This phenomenon seems to be even rarer in the paediatric population and more so following resections of posterior fossa tumours. Here we report diffuse cerebral vasospasm in a child with hypoglossal nerve Schwannoma eight days following resection of the tumour.

Keywords: delayed ischaemic neurological deficit; paediatric; posterior fossa; schwannoma; vasospasm

Abbreviations: ACA: anterior cerebral artery; CPP: cerebral perfusion pressure; CSF: cerebrospinal fluid; CT: computed tomography; DIND: delayed neurological ischaemic deficit; DSA: digital subtraction angiography; EVD: external ventricular drain; HHH: hypervolemia-hypertension-haemodilution; ICA: internal carotid artery; MCA: middle cerebral artery; MRA: magnetic resonance angiography; MRI: magnetic resonance imaging; PCA: posterior cerebral artery; SAH: subarachnoid haemorrhage

Introduction

Although cerebral vasospasm and its clinical manifestations also known as delayed neurological ischaemic deficit (DIND) are commonly seen following aneurysmal subarachnoid haemorrhage (SAH) and traumatic brain injury, vasospasm is considered to be a rare entity following tumour resection. It may present in the early postoperative period or as a delayed complication up to 30 days later, but in most cases it occurs between 7 and 14 days postoperatively.

Diffuse vasospasm of cerebral arteries following tumour resection is extremely rare in the paediatric population. To our knowledge there have been only two previous case reports of diffuse postoperative cerebral vasospasm in children.^{1,2} Here we describe the third case, in a 9-year-old child presenting with hypoglossal nerve schwannoma who developed cerebral vasospasm on the eighth postoperative day.

Case report

We have previously reported a case of left-sided hypoglossal Schwannoma in a 9-year-old girl who underwent a complete resection of the tumour.³ The patient initially presented with 2-month history of nausea and vomiting and daytime headache. She had a left-sided abducens nerve palsy and bilateral papilloedema as well as mild weakness and hyperreflexia in the left upper limb. Magnetic resonance imaging (MRI) revealed hydrocephalus and a uniformly enhancing mass filling most of the inferior third of the posterior cranial fossa, extending through the abnormally expanded left hypoglossal canal to underneath the jugular foramen. The appearance on MRI was consistent with a schwannoma arising from the hypoglossal nerve. A right occipital external ventricular drain (EVD) was inserted and the tumour was excised via a median suboccipital craniotomy and histological diagnosis of schwannoma (WHO-2007 grade 1) was made.

On postoperative Day 7 the EVD was removed and the patient continued to improve. However on the eighth postoperative day, she developed left-sided hemiparesis with facial weakness and became drowsy. An MRI/MRA did not reveal a mass lesion or vertebral artery dissection (given the intimate relationship of the vertebral artery and the tumour), but showed widespread bilateral supratentorial arterial narrowing (Fig. 1A). Subsequent digital subtraction angiography demonstrated diffuse vasospasm of the internal carotid artery, and middle and anterior cerebral arteries on both sides (Fig. 1B–C). CT perfusion (Fig. 1D) scan demonstrated global supratentorial hypoperfusion, more pronounced on the right.

After the diagnosis of vasospasm had been made, the patient was treated with intravenous nimodipine and milrinone as well as noradrenaline infusions to maintain adequate cerebral perfusion pressure (CPP). Repeated imaging revealed moderate ventriculomegaly and 30 cm H₂O pressure was measured during EVD re-insertion. These measures led to improvement of neurological function (left upper limb power improved from 1/5 to 4/5). The vasospasm resolved

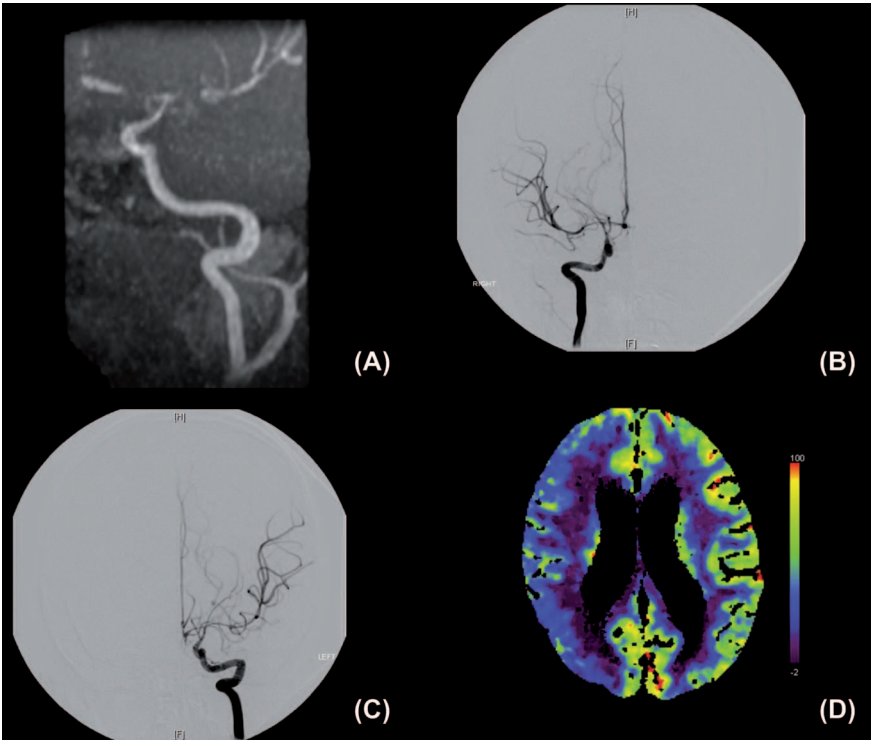


Fig. 1. Selection of images from radiological investigations demonstrating vasospasm (all performed on postoperative Day 8). (A) MRA showing severe narrowing of the right internal carotid (ICA), proximal anterior (ACA) and middle cerebral arteries (MCA). (B) Right carotid injection digital subtraction angiogram (DSA) showing narrowing of distal ICA, proximal ACA and MCA narrowing. (C) Left carotid injection DSA showing narrowing of proximal ACA and MCA narrowing. (D) Perfusion CT showing generalized hypoperfusion, worse on the right.

over the course of one week and the patient made a full recovery. At 3-months follow-up the patient was neurologically intact.

Discussion

Localized postoperative vasospasm is rare, but a known postoperative complication. Diffuse postoperative cerebral vasospasm is an exceedingly rare phenomenon, particularly in the paediatric population and the literature review revealed only two such paediatric cases.^{1–3} Table I summarizes these together with the case reported here. In our case, the vasospasm manifested itself with drowsiness and left hemiparesis. Imaging demonstrated diffuse narrowing of supratentorial arteries and reduced cerebral perfusion particularly on the right hemisphere. Although it is likely that hydrocephalus

contributed to delayed postoperative neurological deterioration, “vasospasm” was likely the dominant underlying factor.

On average, SAH-induced vasospasm occurs within three weeks following haemorrhage with the majority of cases around Day 7. Vasospasm following tumour resection can present within a similar time window. In a cohort of eight adult patients with post tumour resection vasospasm Bejjani et al. reported an average delay from surgery to onset of the vasospasm of 8.5 days. This was similar in the two reported paediatric cases and in our case (Table I).

Multiple aetiologies and pathogenic mechanisms have been put forward to explain vasospasm in the postoperative period. Hypothalamic dysfunction was originally proposed as a cause for vasospasm, as multiple cases were observed following resection of pituitary adenomas. However, vasospasm

Table I. Reported cases of diffuse cerebral vasospasm following tumor resection.

References	Age/Sex	Pathology	Onset	Vessels involved (DSA)	Intra-operative Bleeding	Presentation	Treatment	Outcome
Bejjani et al. (1997) ¹	6/F	III nerve Schwannoma	7 days	Right ICA, MCA and PCA	Minimal	Change of mental status	HHH therapy Angioplasty	Full recovery
Lee et al. (1998) ²	1.3/F	Cerebellopontine primitive neuroectodermal tumor	16 days	Bilateral internal carotid and vertebral arteries	Minimal	Left hemiparesis and right partial ptosis	HHH therapy Nimodipine Anticoagulation	Bihemispheric infarcts
Afshari et al. (2014; current report)	9/F	XII nerve Schwannoma	8 days	Bilateral ICA, MCA and ACA	Minimal	Left hemiparesis and facial weakness	Haemodynamic support Nimodipine	Full recovery

DSA, digital subtraction angiography; HHH, hypervolemia, hypertension, haemodilution; F/M, female/male; ICA, internal cerebral artery; MCA, middle cerebral artery; PCA, posterior cerebral artery.

has been also recorded following resection of other types of tumours such as schwannomas and meningiomas, and at locations far from the pituitary.

Manipulation of vessels is another possible causative factor, either through direct mechanical damage to the vessel. This mechanism was clearly not responsible for the vasospasm in our case as the operative field was remote from the affected vessels.

Excessive bleeding, particularly in the basal cistern, may be an important factor in the development of vasospasm. This theory is supported by experiments by Zabramski et al. who induced vasospasm by introducing blood into subarachnoid cisterns of dogs. It is well known that there is a positive correlation between the amount of blood following SAH and the extent of vasospasm.

In our case, intra-operative bleeding was minimal with no obvious blood in the basal cisterns on the postoperative imaging and patient-specific (constitutional) factors also need to be considered. It is interesting to note that in this patient's case, there was a maternal family history of hemiplegic migraine. Hemiplegic migraine has previously been reported in the paediatric population. Although in our case the patient herself did not suffer from migraine, we cannot exclude that this phenomenon may have played a part in the vasospastic episode observed. Currently, however, there is no evidence that patients with migraine are more at risk of postoperative vasospasm.

Vasospasm following tumour resection is a rare entity and its pathogenesis remains elusive. However, it should be considered when there is any delayed and unexpected neurological deterioration following tumour resection that is not explained by haematoma or focal brain oedema. Aggressive treatment with CPP-directed therapy along with nimodipine should be instituted as soon as possible. In addition, intra-arterial infusion of vasoactive agents as well as angioplasty should be considered in patients with vasospasm not responding to haemodynamic support.

Declaration of interest: The authors report no declarations of interest. The authors alone are responsible for the content and writing of the paper.

References

1. Bejjani GK, Duong DH, Kalamarides M, Ziyal I, Sullivan BJ. Cerebral vasospasm after tumour resection: a case report. *Neurochirurgie* 1997;43:164-8.
2. Lee TT, Ragheb J, Bruce JC, Altman N, Morrison G. Diffuse cerebral vasospasm with ischemia after resection of a cerebellopontine angle primitive neuroectodermal tumour in a child. *Paediatr Neurosurg* 1998;29:300-3.
3. Santarius T, Dakoji S, Afshari FT, et al. Isolated hypoglossal schwannoma in a 9-year old child. *Pediatr Neurosurg* 2012;10: 130-3.

Copyright of British Journal of Neurosurgery is the property of Taylor & Francis Ltd and its content may not be copied or emailed to multiple sites or posted to a listserv without the copyright holder's express written permission. However, users may print, download, or email articles for individual use.