

Cervical epidural haematoma causing Brown-Sequard syndrome: a case report

Arvind G Kulkarni,^{1,2} Kushal Nag,¹ Sambhav Shah^{1,2}

¹ Saifee Hospital, Mumbai, India

² Bombay Hospital, Mumbai, India

ABSTRACT

Brown-Sequard syndrome secondary to compression of the spinal cord by an epidural haematoma following minor trauma is rare. A 65-year-old woman presented with neck pain and sudden onset hemiplegia with contralateral anaesthesia. Magnetic resonance imaging showed a haematoma in the epidural space in the C3 to C5 levels. She underwent open-door laminoplasty for evacuation of the haematoma. At the 2-year follow-up, she had regained normal sensations and a neurological grade of 5/5.

Key words: *Brown-Sequard syndrome; hematoma, epidural, spinal*

INTRODUCTION

Brown-Sequard syndrome is characterised by motor paralysis on the same side as the spinal cord lesion and deficits in pain and temperature sensation on the

opposite side. This is known as ipsilateral hemiplegia and contralateral pain and temperature sensation deficits (anaesthesia). The loss of sensation is caused by the sensory nerve fibres of the spinothalamic tract crossing the spinal cord. The most common cause is penetrating trauma such as a gunshot wound or stab wound to the spinal cord. Other causes are tumours, epidural haematomas, tuberculosis, and multiple sclerosis. We report on a 65-year-old woman with Brown-Sequard syndrome secondary to a cervical epidural haematoma following minor trauma.

CASE REPORT

In October 2008, a 65-year-old woman presented with sudden-onset hemiplegia of the right side and anaesthesia of the left side. The patient did not have any previous trauma or medical co-morbidities (such as hypertension or diabetes mellitus), but gave a history of sudden voluntary hyperextension of the neck.

On clinical examination, the motor power of the right-side limbs was grade 0/5. There was anaesthesia

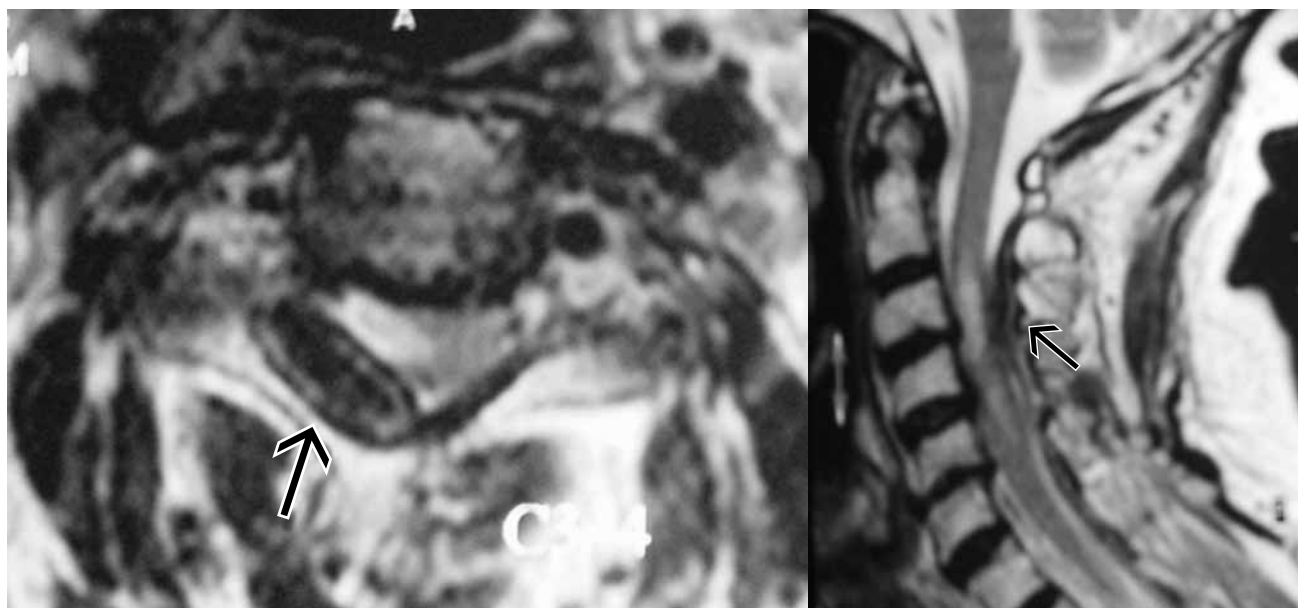


Figure T2-weighted magnetic resonance images showing an epidural haematoma (arrows) extending from the C3 to C5 levels compressing the spinal cord.

of the left side below C3. The patient had spasticity with hyper-reflexia and positive Babinski reflex on the right side. Her bladder and bowel functions were normal. She was initially examined by a neurologist and suspected to have a cerebrovascular incident. Computed tomography (CT) of the brain was normal. Magnetic resonance imaging (MRI) of the cervical spine showed an isointense mass extending from the C3 to C5 levels compressing the right side of the spinal cord (Fig.).

The patient underwent open-door laminoplasty. The spinal cord was compressed by the haematoma extending from the C3 to C5 levels laterally to the foramen. The haematoma was evacuated, and palpations in the spinal cord were immediately appreciated. Postoperatively, the patient was immobilised with a hard cervical collar, and physiotherapy was started. At the 2-year follow-up, the patient had regained normal sensory functions and a power of 5/5 in all 4 limbs.

DISCUSSION

About 40% of cervical epidural haematomas do not have any demonstrable aetiology and are referred to as idiopathic and spontaneous.¹ The diagnosis must exclude other causes such as neoplasm and systemic diseases,² anticoagulant therapy,¹ hypertension,³ pregnancy,⁴ and vascular malformations.³ Cervical

epidural haematoma occurs most commonly in patients aged 50 to 80 years,⁵ and rarely in those younger than 16 years.⁶ The male-to-female ratio is 1.5:1.⁵

There is controversy as to whether the source of the haematoma is arterial or venous. Proponents of a venous origin maintain that the sudden increase in intrathoracic and intra-abdominal pressure leads to the rupture of the thin-walled epidural veins. Injury to the epidural veins may occur during coughing, sneezing, defecation, micturition, vomiting, and coitus.⁷⁻⁹ However, as the epidural venous pressure is less than the intrathecal pressure, the haematoma is unlikely to cause Brown-Sequard syndrome.¹ In addition, extreme movements at the cervicodorsal junction could result in tearing of the arteries. The high arterial pressure can lead to compression of the dural sac and clinical syndromes,¹ and even an active bleeding arterial haematoma.¹⁰

Acute onset of radiating neck pain is the most common symptom; the location depends on the involvement of specific nerve roots and the spinal cord. The second most common symptom is gradual weakness of the limbs below the level of compression.¹¹ Brown-Sequard syndrome as a result of cervical epidural haematoma is rare.¹²

Myelography used to be the diagnostic modality of choice,^{13,14} but there is a risk of lumbar puncture and its results are non-specific.^{15,16} MRI is the diagnostic tool of choice.¹⁷ Spinal angiography may

be useful in planning surgery for patients with a vascular anomaly. The differential diagnoses include neoplasia, transverse myelitis, aortic aneurysm, epidural abscesses, and acute cervical disc herniation. Hemiparesis at presentation may be confused with a cerebrovascular incident.¹⁸

Prompt diagnosis and surgical decompression is vital to facilitate neurological recovery, although recovery without any surgical intervention has

been reported.^{19,20} Laminectomy is the preferred procedure; hemilaminectomy or laminoplasty can also be used depending on the extent and location of the haematoma.²¹

DISCLOSURE

No conflicts of interest were declared by the authors.

REFERENCES

1. Beatty RM, Winston KR. Spontaneous cervical epidural hematoma. A consideration of etiology. *J Neurosurgery* 1984;61:143–8.
2. Harris DJ, Fornasier VL, Livingston KE. Hemangiopericytoma of the spinal canal. Report of three cases. *J Neurosurg* 1978;49:914–20.
3. Foo D, Chang YC, Rossier AB. Spontaneous cervical epidural hemorrhage anterior cord syndrome, and familial vascular malformation: case report. *Neurology* 1980;30:308–11.
4. Yonekawa Y, Mehdorn HM, Nishikawa M. Spontaneous spinal epidural hematoma during pregnancy. *Surg Neurol* 1975;3:327–8.
5. Foo D, Rossier AB. Preoperative neurological status in predicting surgical outcome of spinal epidural hematomas. *Surg Neurol* 1981;15:389–401.
6. Vallee B, Besson G, Gaudin J, Person H, Le Fur JM, Le Guyader J. Spontaneous spinal epidural hematoma in a 22-month-old girl. *J Neurosurg* 1982;56:135–8.
7. Correa AV, Beasley BA. Spontaneous cervical epidural hematoma with complete recovery. *Surg Neurol* 1978;10:227–8.
8. Marinella MA, Barsan WG. Spontaneously resolving cervical epidural hematoma presenting with hemiparesis. *Ann Emerg Med* 1996;27:514–7.
9. Williams JM, Allegra JR. Spontaneous cervical epidural hematoma. *Ann Emerg Med* 1994;23:1368–70.
10. Lowrey JJ. Spinal epidural hematomas. Experiences with three patients. *J Neurosurg* 1959;16:508–13.
11. Clarke DB, Bertrand G, Tampieri D. Spontaneous spinal epidural hematoma causing paraplegia: resolution and recovery without surgical decompression. *Neurosurgery* 1992;30:108–11.
12. Narberhaus B, Rivas I, Vilalta J, Abos J, Ugarte A. Transient Brown-Sequard syndrome due to spontaneous spinal epidural hematoma [in Spanish]. *Neurologia* 2002;17:384–7.
13. Gold ME. Spontaneous spinal epidural hematoma. *Radiology* 1963;80:823–8.
14. Solymosi L, Wappenschmidt J. A new neuroradiologic method for therapy of spinal epidural hematomas. *Neuroradiology* 1985;27:67–9.
15. Mustafa MH, Bernstein RA. Spontaneous spinal epidural hematoma, Brown-Sequard syndrome, and factor XI deficiency. *Ann Intern Med* 1987;106:477–8.
16. Case records of the Massachusetts General Hospital. Weekly clinicopathological exercises. Case 14-1982. An 81-year-old woman with severe lumbar pain and sciatica. *N Engl J Med* 1982;306:855–60.
17. Holtas S, Heiling M, Lonntoft M. Spontaneous spinal epidural hematoma: findings at MR imaging and clinical correlation. *Radiology* 1996;199:409–13.
18. Adamson DC, Bulsara K, Bronec PR. Spontaneous cervical epidural hematoma: case report and literature review. *Surg Neurol* 2004;62:156–60.
19. Galzio RJ, Zenobii M, D'Ecclesia G. Spontaneous spinal epidural hematoma: report of a case with complete recovery. *Surg Neurol* 1980;14:263–5.
20. Hentschel SJ, Woolfenden AR, Fairholm DJ. Resolution of spontaneous spinal epidural hematoma without surgery: report of two cases. *Spine (Phila Pa 1976)* 2001;26:E525–7.
21. Awada A, Russell N, Fayed N, Naufal R, al Kohlani H. Spontaneous cervical epidural hematoma: case report. *Spinal Cord* 1998;36:71–2.