

Right Brain: A reading specialist with alexia without agraphia

Teacher interrupted

Jason Cuomo, MA
Murray Flaster, MD, PhD
José Biller, MDCorrespondence to
Mr. Cuomo:
jcuomo@lumc.edu

Reading to children was a source of fulfillment in the life of M.P., a 40-year-old aunt, kindergarten teacher, and reading specialist. Whether in the classroom, the reading room, or the living room, M.P. found joy in the dual role of teacher and storyteller. For her, it was an important means of relating to those under her care. But all of that changed when, on a Thursday morning, M.P. found herself standing at the front of her class and holding in her hands an indecipherable mystery.

It was the attendance sheet. The same sheet she had used for years, and to hear M.P. tell it, it might as well have been covered in hieroglyphs. Moments later, she found that her lesson plans, which she had spent a distinguished career in devising, were equally incomprehensible. By this time, panic had begun to set in, but the watershed moment came as she surveyed the task she had set for herself earlier in the week: Halloween was just around the corner, and she had a classroom to decorate. “I couldn’t figure it out, which is not like me,” she recalls, a sadness creeping into her voice. “How can you not figure out Halloween?”

The school principal was as perplexed as she, and M.P. was promptly discharged from work and into the care of her mother, S.P. Over the next 2 days, new difficulties began to surface. Some were related to her inability to read: for instance, she could no longer tell time. Others manifested themselves in her activities of daily living, as when it took M.P. several hours to pack her travel bag for the move to her mother’s house that Friday.

By Saturday morning, M.P. was having significant problems finding words, and her thinking had slowed. When her confusion gave way to anxiety and agitation, S.P. decided that her daughter was going to the emergency room. It was there that, after a fitful day spent in the waiting room, M.P. was first seen by a physician and promptly admitted. Exhausted from her part in the ordeal, S.P. left the hospital and went to sleep.

Not 1 hour went by before her reprieve was interrupted by the phone’s ringing. “I’m screwed!” M.P. exclaimed into the receiver. “It’s a stroke.”

Alexia without agraphia, also commonly referred to as “word blindness,” is a rare neurologic syndrome

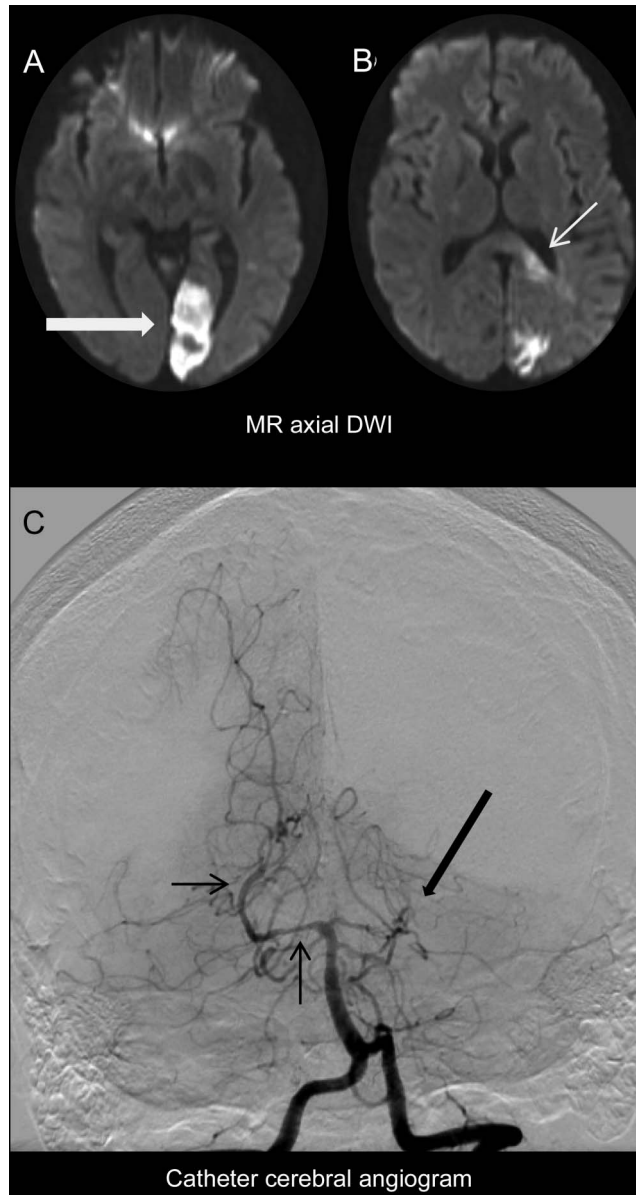
in which patients lose the ability to read but can still write and comprehend the spoken word. These deficits are also frequently accompanied by a right homonymous hemianopsia, as well as color anomia and various apraxias. It was first described in 1892 by Joseph Jules Déjerine, who hypothesized that this unique pattern of deficits is caused by subcortical lesions that functionally isolate the left angular gyrus, or “language zone,” from the visual cortex. This unique deficit may be brought about by a number of different patterns of lesions, including 1) a single lesion to the splenium of the corpus callosum that stretches posterolaterally so as to interrupt white matter tracts running from the visual cortices of both hemispheres to the left angular gyrus, 2) lesions to both the splenium and the left primary visual cortex, or 3) lesions involving both the splenium and the lateral geniculate nucleus. In each case, the language zone is robbed of its visual inputs but remains intact. Etiologies of these lesions include posterior cerebral artery territory infarct, tumor, or demyelinating disorders such as multiple sclerosis or acute disseminated encephalomyelitis.

M.P.’s alexia without agraphia resulted from biopsy-negative probable primary angiitis of the CNS (figure, A–C). It is noteworthy that these lesions do not interrupt other sensory inputs to the language zone—a fact that M.P. has worked diligently to exploit in the months following her stroke.

Once an avid reader, M.P. was not willing to let her life’s passion go so easily, and she immediately set about teaching herself to read again using all the tools of her profession. One can only imagine her dismay when these efforts met with little success. Recalling her own vexation at her daughter’s situation, S.P. relates, “Ironically, with the knowledge of all these different reading programs—sight words and phonics and all these nuances—it didn’t help her at all with her own disability.” M.P. made use of flash cards with word captions, writing exercises, and a number of other techniques, and while these tools together with occupational therapy aided her in recovering her ability to perform everyday tasks, she was still unable to read.

From the Department of Neurology, Loyola University Chicago, Stritch School of Medicine, Maywood, IL.

Go to Neurology.org for full disclosures. Funding information and disclosures deemed relevant by the authors, if any, are provided at the end of the article.



(A, B) Echoplanar axial diffusion-weighted MRI (DWI) shows left posterior cerebral artery territory diffusion restriction including the left visual cortex (large arrow) and the splenium of the corpus callosum (small arrow). (C) Catheter angiogram, left vertebral artery injection, anterior posterior projection shows occlusion of the left posterior cerebral artery (large arrow) and constrictions and dilations of the right posterior cerebral artery consistent with probable primary angiitis of the CNS.

But where conventional wisdom had failed her, innovation did not, and M.P. soon discovered that her other senses might prove beneficial. Her discovery was this: when shown a word, M.P. could decipher it letter-by-letter with the help of tactile cues such as letter tracing. “She sort of picked up this tactile approach—truthfully—herself,” her mother says with pride. “She’s the one who reinvented the wheel!”

To see this curious adaptation in practice is to witness the very unique and focal nature of her deficit. Given a word, M.P. will direct her attention to the first letter, which she is unable to recognize. She will then place her finger on the letter and begin to trace

each letter of the alphabet over it in order until she recognizes that she has traced the letter she is looking at. “That is the letter M,” she declares, after tracing the previous 12 letters of the alphabet with her finger while deciphering a word in front of her. Three letters later, she is able to shorten this exercise with a guess: “This word is ‘mother,’” she announces proudly.

Nor are such intuitions uncommon for M.P. when looking at written words, for although she cannot read a word by sight, it may nevertheless elicit emotions that seem surprisingly appropriate. For instance, when shown the word “dessert” in writing, M.P. exclaimed, “Oooh, I like that!” When shown the word “asparagus”

moments later, however, her response was rather different. “I’m not doing this word! Something’s upsetting me about this word!” she exclaims.

Nor have these intuitions been without utility. S.P. relates a recent anecdote in which, during an afternoon therapy session, her daughter was shown 2 letters from the mailbox at home. Nonplussed, M.P. quickly handed one letter back to her mother and tucked the other into her purse, saying, “This is my friend, and this is your friend.” When asked who these friends were, she could not say, but their names nevertheless provoked an emotional response that served as a powerful contextual clue.

Ten months after her stroke, we met with M.P. again and asked her what it is like, as a reading instructor, to live with alexia without agraphia. She replied that what she misses most is not the pleasure of reading books on her own, but that of reading books to children. She recalls with tears in her eyes one occasion on which she felt this loss most poignantly, saying, “One day my mom was with the kids in the family, and they were all curled up next to each other, and they were reading. And I started to cry, because that was something I couldn’t do. I could be there, but I couldn’t pick up the book and read it. That’s something that I’d always done, and it’s something I had a lot of pleasure from. And I couldn’t do it.”

Despite this great loss, M.P. is still an active and valued member of her community. She has a job at

a local fitness center, where she works at the front desk and sells memberships. She volunteers in the park district, where her friends are always looking for ways that she might contribute. S.P. had recently hosted a well-attended birthday party for her daughter. M.P.’s goal afterwards was to write thank-you notes to each of her guests. She is even preparing to write her own story, a memoir of a teacher with pure alexia, to get the word out about her condition and to raise funds for stroke research.

One year after the day of her stroke, M.P.’s story comes full circle: Halloween is again around the corner, and this year she will be helping her fellow volunteers in the park district prepare for the festivities. “I’m going to pick up the goody bags and stuff them. As long as I can keep the dog away, I’ll be successful.”

AUTHOR CONTRIBUTIONS

Jason R. Cuomo was involved in the design of the study, in data collection and analysis, and in drafting and revising the manuscript. Dr. Murray Flaster was involved in the design of the study, in data analysis, and in revising the manuscript. Dr. José Biller was involved in the evaluation and care of this patient, in the conceptualization and design of the study, in data collection and analysis, and in revising the manuscript.

STUDY FUNDING

No targeted funding reported.

DISCLOSURE

J. Cuomo and M. Flaster report no disclosures. J. Biller is the editor of the *Journal of Stroke and Cerebrovascular Diseases* and the chief editor of *Frontiers in Neurology*. Go to Neurology.org for full disclosures.

Neurology®

Right Brain: A reading specialist with alexia without agraphia: Teacher interrupted

Jason Cuomo, Murray Flaster and José Biller

Neurology 2014;82:e5-e7

DOI 10.1212/01.wnl.0000438218.39061.93

This information is current as of December 30, 2013

Updated Information & Services	including high resolution figures, can be found at: http://www.neurology.org/content/82/1/e5.full.html
Subspecialty Collections	This article, along with others on similar topics, appears in the following collection(s): All Neuro-ophthalmology http://www.neurology.org/cgi/collection/all_neuroophthalmology Infarction http://www.neurology.org/cgi/collection/infarction Visual processing http://www.neurology.org/cgi/collection/visual_processing
Permissions & Licensing	Information about reproducing this article in parts (figures, tables) or in its entirety can be found online at: http://www.neurology.org/misc/about.xhtml#permissions
Reprints	Information about ordering reprints can be found online: http://www.neurology.org/misc/addir.xhtml#reprintsus

Neurology® is the official journal of the American Academy of Neurology. Published continuously since 1951, it is now a weekly with 48 issues per year. Copyright © 2013 American Academy of Neurology. All rights reserved. Print ISSN: 0028-3878. Online ISSN: 1526-632X.

