

Paragrammatic Speech without a Comprehension Deficit? A Case Report

PAUL ELING

Department of Comparative and Physiological Psychology

KEES DE BOT

Institute of Applied Linguistics

AND

ANTOINE KEYSER AND CATRIENTJE VAN DER SANDE

Institute of Neurology, St. Radboud Hospital, University of Nijmegen

In this article we present a case report of a patient, who had a peculiar pattern of language use following a stroke. The two most prominent features were (1) language switches during spontaneous speech in the first months postonset, when the patient mixed English, German, and French words and utterances into his mother tongue (Dutch); (2) clearly disturbed speech output, showing signs of word-finding problems and paragrammatism but hardly any paraphasias, while at the same time no evidence of a language disturbance could be obtained with standard clinical aphasia tests. © 1987 Academic Press, Inc.

NEUROLOGICAL EXAMINATION

In November 1982, a 71-year-old right-handed man (H.B.) developed a right-sided hemiplegia that was accompanied by dysphasic symptoms. He had previously experienced a number of transient ischemic attacks resulting in a transient paresis of the right hand.

Neurological examination on admission revealed a deviation of head

The work reported here was performed within the project "Aphasia in Adults" of the Max Planck Institute for Psycholinguistics, which is supported by the Dutch Organization for the Advancement of Pure Research (ZWO) and the German Max Planck Gesellschaft. The first author is now working at the Department of Comparative and Physiological Psychology, Catholic University of Nijmegen, P.O. Box 9104, 6500 HE Nijmegen, The Netherlands, to which address requests for reprints may be sent.

and eyes toward the left. A central paresis of the facial musculature was found, together with other signs of a right-sided hemiplegia. In addition a hemianesthesia of the right side of the body existed. Muscular tone of the right-side extremities was raised; on the right, an extensor response of the plantar reflex was found, while on the left an indifferent reaction was obtained.

On the EEG asymmetric background activity was seen with a localized focus of hypofunction at the left frontotemporal region. This disturbance was not seen on an EEG registration made previously in 1978. A Doppler ultrasonography examination revealed an insufficiency of the right-side common carotid artery.

On the CT scan—taken 10 days postonset (see Fig. 1)—a hypodense area was visible in the left hemisphere at the location of the anterior limb of the internal capsula. The caudate nucleus was also involved. A diagnosis of cerebral infarction in the area of the anterior limb of the left internal capsula and caudate nucleus was maintained, either as a consequence of thrombosis at that site or of embolization.

After a few days the patient recovered from his hemiplegia, except for some residual paresis of the right leg. The receptive language problem accompanied by a fluent production of incomprehensible language which was observed on admission was reduced considerably within a period of 3 weeks. The patient's comprehension improved, and he showed hardly any errors on the Token Test.

The patient's history mentions that in 1972 he suffered from a seizurelike event consisting of convulsions in the left half of the body. For half an hour afterward, a left-sided hemiparesis and some difficulties in speaking remained present, but subsequently disappeared completely. Just before this event the patient had complained about a left-sided brachialgia and lack of force in the left hand. Neurological examination a few hours after the seizurelike event revealed a pyramidal syndrome in the left half of the body and an extensor response of the left plantar reflex. The EEG registration showed nonspecific disturbances due to brain stem dysfunction. In addition deep temporal foci of hypofunction were recorded bilaterally.

Angiography at that time revealed a stenosis of the left subclavian artery. In addition a stenosis of the left vertebral artery was seen. On the left-side carotid angiogram a small carotid syphon was observed with several filling defects. The main stem of the middle cerebral artery on the left side appeared severely stenosed, and there appeared to be an occlusion of the posterior parietal cortical artery. The physician in charge maintained the following diagnosis: stenosis in the left subclavian artery, causing a stealing from the posterior fossa. In addition he diagnosed a thrombosis of the carotid syphon, which extended partly into the intracranial distribution of the internal carotid artery. From 1972 to 1982 the patient was seen at regular intervals by a neurologist because of pain complaints

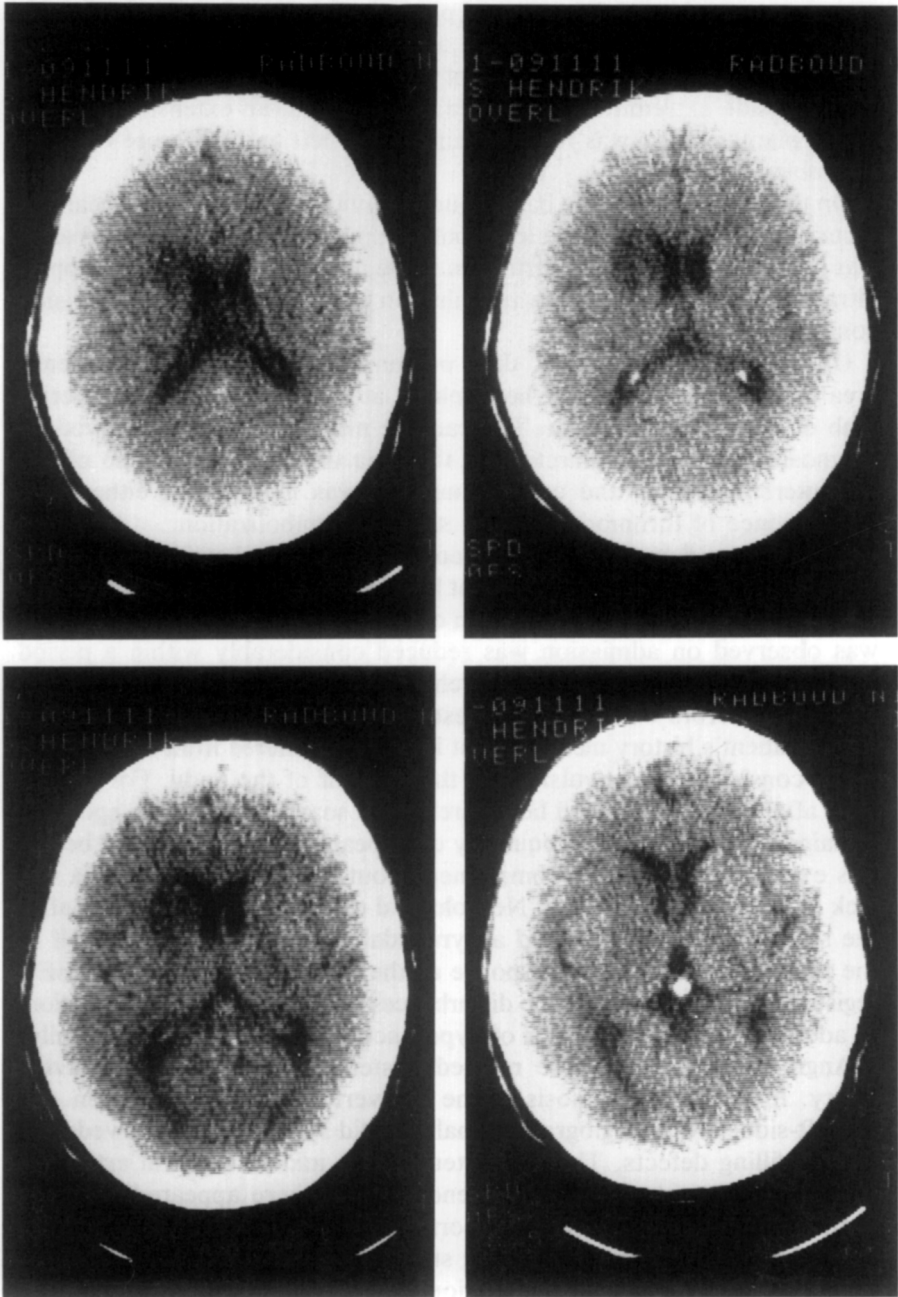


FIG. 1. CAT scan of the patient revealing a hypodense area localized in the leftside anterior limb of the internal capsule and caudate nucleus.

in the lower extremities. No language disturbances were observed during this period.

LANGUAGE EXAMINATION

According to reports from the patient and his wife, H. B. did not have any language problems before his stroke in November 1982, apart from the short period (approximately half an hour) after the seizurelike event in 1972. In the first weeks postonset the patient showed spontaneous switches to English, German, and French during conversation. Perhaps he also spoke some Japanese, but since these incomprehensible parts had not been recorded we were not able to check this. It is certain that the patient can speak some Japanese. He had worked for several years in Japan, and he had taught himself to speak Japanese. As a representative of a business company he had worked in several other countries as well. Furthermore, in connection with his interest in the Olympic Games, he kept up an intensive correspondence with many people abroad. From these letters it becomes clear that H.B. was able to express himself in several languages without having full mastery of any of them.

Example of Spontaneous Speech and Language Switches:

November 11, 1984 (18 Days Postonset)

Therapist: Ja, en U hebt weinig tijd om dat te doen . . .

Mr. B.: (*Dutch*) Nou ja, eh, voor de in . . . (*English:*) it is hard (*Dutch:*) ja 't is wel aardig (*German:*) aber nicht für (*English:*) me (*Dutch:*) Goed, als 't is (*English:*) for me (*Dutch:*) dan okee, maar het is niet zo.

Translation:

Therapist: Yes, and you don't have much time to do that . . .

Mr. B.: Well, yes, eh, for the in... it is hard, yes, it may be nice but not for me. Okay, if it is for me, then okay, but it is not so.

In the first few weeks his speech was fluent but not completely correct. There were few paraphasias and neologisms. He had only a small number of errors on the Token Test and for these reasons no formal aphasia test was taken. After approximately 4 weeks the language switches disappeared, but it was noted that his spontaneous speech remained defective. His word-finding problem in particular seemed to result in interruptions of utterances, leading to paragrammatic constructions. During the first weeks the Token Test was presented to H.B. regularly in Dutch as well as in English and German. He made hardly any errors in the languages tested. The Paradis-Goldblum Bilingual Aphasia Test was administered, and again no sign of any language disorders was found, apart from a clear inability to produce words starting with a particular phoneme, and inability to translate between two foreign languages.

Two years postonset we had the impression that his spontaneous speech had still not returned to a normal level, and the Dutch version of the Aachener Aphasic Test (AAT) was administered, including the Token Test. No significant problems were observed, neither in speech comprehension nor in production, during formal testing. Nevertheless, transcriptions of his spontaneous speech showed that many sentences were grammatically not well formed and the impression was that the underlying deficit might be a word-finding problem. However, it should be noted that traditional confrontation naming tests did not indicate any word-finding problems.

Example of Spontaneous Speech and Paragrammatic Errors:

September 24, 1986 (Approximately 2 Years Postonset)

Mr. B.: Ja het is de taal hé het blijft zitten als ik als u mij nu aanspreekt dan moet ik soms een uur moet ik erover doen om datgene net te zeggen wat ik zou willen zeggen da's ko kolder dat heb ik vroeger nooit gehad ja helemaal zo en dan zeg ik nou dan laat maar weer gaan en dan krijg je toch een verkeerd beeld van mijn persoon in ieder geval ja dan krijg je die vent die kan niet eh die kan nie kan niet meekomen of wat dan ook en dat vind ik jammer jammer omdat het niet aangepast aan de logische gang van zaken maar daar kan ik niets aan doen.

Translation:

Mr. B.: Yes it is the language you know it stays where it is when I when you talk to me then I need sometimes one hour need I to say what I would like to say that's non nonsense I never had that before yes completely so and then it comes in the end but that is too long for me and then I say well and just let go and then one gets a wrong picture of of me in any case yes then you get that guy he cannot he cannot keep up or what have you and that's what I regret regret because it does not adjust on the logical course of events but there is nothing I can about it.

In order to study word finding and production in more detail, we assembled a list of words on the basis of Dutch association norms (de Groot, 1980), and asked H.B. to give us associations. Of the 70 words presented we obtained a prompt and acceptable response in 58 cases. In most other cases he produced a circumscription, e.g., *rocket*, "apparatus that goes to the moon;" *blanket*, "I lie under it."

The patient himself is aware of having some difficulties in speech production. When he received speech remediation he had a clear preference to talk about his stamp collection, since he believed he would have the fewest problems when he talked about this subject. There is no evidence, however, that he makes fewer errors in that situation. He has mentioned that sometimes during speech he is "blocked," he cannot continue until after several seconds (in the order of 10–20 sec). One of us has observed one such "block." The "errors" in his speech, however, are much more frequent and the pauses are usually shorter, perhaps due to a strategy to fill gaps.

No other neuropsychological tests were administered. The patient returned home after 3 weeks, and apart from a minor problem with his right foot no other consequences of the cerebrovascular accident were noted, neither in the neurological examination nor by the patient and his wife.

In the literature on bilingual aphasia, only a few cases are similar to H.B. Cases of code switching are mentioned by Pick (1909), Hegler (1931), Gloning and Gloning (1965), L'Hermitte, Hécaen, Dubois, Culioli, and Tabouret-Keller (1966), and Perecman (1984). Unfortunately, in most cases very little information is provided about linguistic aspects of switching behavior. On the basis of the descriptions available, H.B. is best compared with case 4 of L'Hermitte et al. (1966) and the case of Perecman (1984). Perecman's explanation of code switching as a compensatory strategy seems relevant for our case as well. On the other hand, the occurrence of code switching without any observable comprehension deficit is extremely rare.

CONCLUSION

In summary, patient H.B. showed some peculiar language problems as a result of an infarction of the internal capsule in the left hemisphere. He mixed several languages: when talking in Dutch, for instance, without being aware of the moment of switching he suddenly found himself talking in English. This phenomenon gradually disappeared after approximately 4 weeks.

A second prominent feature of his speech was the contamination of sentences, where in the middle of a sentence a new sentence is started and the final part of the first sentence serves—with or without duplication—as the beginning of the next sentence. Apart from this, he also produced constructions that can be considered paragrammatic. On formal testing, no signs of language disorder are obtained. The second phenomenon is thus restricted to conditions of ongoing conversations and the impression is that the underlying deficit might be a word-finding problem.

The pattern of results obtained thus far seems to suggest that paragrammatic errors can be observed without a significant number of paraphasias and neologisms (they were hardly observed after the initial stage). Also, a comprehension deficit does not necessarily accompany paragrammatic speech. A final suggestion appears to be that "paragrammatic" errors might be due to word-finding problems and not to grammatical processes. In that case they might be considered to be an artefact rather than a "negative" symptom, a syntactic deficit.

REFERENCES

- De Groot, A. 1980. *Mondelinge Woordassociatie Normen: 100 woordassociaties op 460 nederlandse zelfstandige naamwoorden*. Lisse, Swets, & Zeitlinger.

- Gloning, I., & Gloning, K. 1965. Aphasien bei Polyglotten. *Wiener Zeitschrift für Nervenheilkunde*, **22**, 362–397.
- Hegler, C. 1931. Zur Aphasie bei Polyglotten. *Deutsche Zeitschrift für Nervenheilkunde*, **117**, 236–239.
- L'Hermitte, R., Hécaen, H., Dubois, J., Culioli, A., & Tabouret-Keller, A. 1966. Le problème de l'aphasie des polyglottes, remarques sur quelques observations. *Neuropsychologia*, **4**, 315–329.
- Perecman, E. 1984. Spontaneous translation and language mixing in a polyglot aphasic. *Brain and Language*, **23**, 43–63.
- Pick, A. 1909. Fortgesetzte Beiträge zur Pathologie des sensorischen Aphasie. *Archiv für Psychiatrie und Nervenkrankheiten*, **37**, 216–241, 468–487.