



ORIGINAL ARTICLE

Three Cases of Imported Neurocysticercosis in Northern Italy

Maria Teresa Giordani, MD,* Francesca Tamarozzi, PhD,[†] Federico Cattaneo, MD,[†] and Enrico Brunetti, MD[†]*Infectious and Tropical Diseases Unit, San Bortolo Hospital, Vicenza, Italy; [†]Department of Infectious Diseases, IRCCS San Matteo Hospital Foundation-University of Pavia, Pavia, Italy

DOI: 10.1111/jtm.12066

Background. Neurocysticercosis (NCC) is an important cause of adult-onset seizures in endemic areas, whereas it is emerging in some nonendemic areas as well because of extensive immigration.

Method. We describe three cases of imported NCC recently admitted to San Bortolo Hospital in Vicenza, located in Northern Italy.

Results. All patients were immigrants. One patient was human immunodeficiency virus positive with severe immunosuppression. The diagnosis of NCC was made on the basis of magnetic resonance results; failure of anti-*Toxoplasma*, antitubercular, and antifungal therapy; and regression of the cystic lesions after empiric therapy with albendazole. Serology was positive in only one case. In one patient, NCC was diagnosed by biopsy of the brain lesion.

Conclusion. In nonendemic countries, NCC should be included in the differential diagnosis of all patients coming from endemic areas with seizures, hydrocephalus, and compatible lesions on brain imaging. Long-term follow-up is required but may be difficult to implement because these patients tend to move in search of employment. Screening of patient's household contacts for *Taenia solium* infection should always be carried out.

Neurocysticercosis (NCC), caused by the larval stage (cysticercus) of the pork tapeworm *Taenia solium*, primarily involves the central nervous system and is the most common cause of acquired epilepsy in the developing world.¹ NCC is endemic to many countries but in Italy, as in Western Europe in general, the few cases reported are mostly imported from endemic areas.^{2–4}

Methods and Results

We describe the complex presentation of three cases of NCC, one of which occurred in a human immunodeficiency virus (HIV)-positive patient. The difficulties of the diagnostic and clinical management

process and the increasing relevance of this imported infection outside the endemic areas are discussed.

Patient 1

A 34-year-old man from Senegal, who had been living in Italy for 6 years, was admitted to San Bortolo Hospital, Vicenza, Italy, in February 2010 because of seizures, of which he had a history since 2008.

Magnetic resonance (MR) in T1- and T2-weighted images (WIs) showed a brain lesion consisting of two adjacent cysts isointense with the cerebral spinal fluid (CSF), surrounded by edema, and showing ring enhancement after gadolinium (Figure 1A–C). The serology for *T solium* both on serum and CSF was negative (Immunoblotting, LD Bio, Lyon, France performed at the Parasitology Laboratory, San Matteo Hospital Foundation, Pavia, Italy), as was ova and parasite (O&P) fecal examination. No further lesions compatible with parasitic infections were found, with the possible exception of a pulmonary nodule and a single calcification in the right hepatic lobe on ultrasound. Fundoscopic examination was negative.

The cerebral lesion was surgically removed in April 2010 and its pathological examination showed a

Part of this material was presented as a poster at the 21st ECCMID/27th ICC, Milan, Italy (P866, page S211).

Corresponding Author: Maria Teresa Giordani, MD, Infectious and Tropical Diseases Unit, San Bortolo Hospital, via Rodolfi 37, I-36100 Vicenza, Italy. E-mail: giordanimt@gmail.com

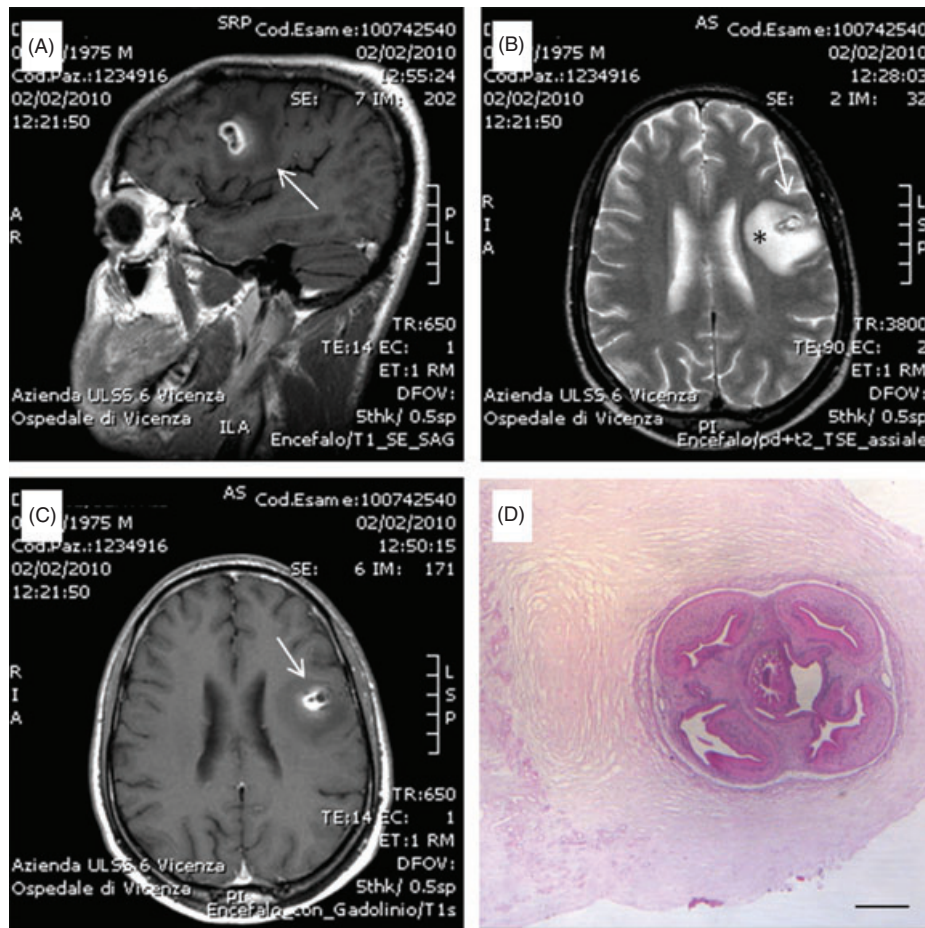


Figure 1 Case 1. (A–C) Magnetic resonance (MR) showing a cortical–subcortical lesion in the left frontal lobe having multiple cystic areas with content isointense with cerebrospinal fluid (CSF) (arrows) and surrounded by edema (star). (A) T1-weighted image (WI); (B) T2-WI; and (C) ring enhancement of the cyst wall after gadolinium. (D) Hematoxylin–eosin-stained histology section of brain lesion showing *Cysticercus cellulosae* scolex within degenerated material. Original magnification 20×, bar scale 500 μm.

T. solium viable larva and degenerated parasitic material within a cystic cavity (Figure 1D). After surgery the patient was treated with albendazole 400 mg bid for 8 days, praziquantel 1.5 g once on the fourth day, dexamethasone 4 mg bid for 8 days, and carbamazepine 200 mg tid (the latter started before neurosurgery).

Patient 2

A 24-year-old African HIV-2-positive man from Burkina Faso, an observant Muslim, who had been living in Italy for 8 years, was admitted to San Bortolo Hospital in May 2010 with fever, pneumonia, and sepsis. He had an extremely low CD4 count (24 /mm³).

During hospitalization the patient had a seizure. A computed tomography (CT) scan of the brain revealed a hypodense cortical–subcortical lesion in the left frontal-basal lobe, whereas a previous brain CT examination done in June 2009 after a car accident showed a negative result. MR (Figure 2A and B) revealed two adjacent cysts, isointense with CSF

in T1-WI and T2-WI, surrounded by edema and ring enhancement after gadolinium. Empirical anti-*Toxoplasma* therapy with sulfadiazine/pyrimethamine and antifungal and antitubercular therapy were ineffective, and after a repeat MR scan with unchanged findings (Figure 2C), NCC was suspected. Serology for *Toxocara canis*, *Echinococcus granulosus*, *Toxoplasma gondii*, *Schistosoma* spp., *Strongyloides stercoralis* (IgG, indirect fluorescent antibody test), *Coxiella burnetii*, *Aspergillus* spp., and *Bartonella* spp., and circulating antigens for *Cryptococcus* and *Cytomegalovirus* were negative, as were QuantiFERON-TB test and O&P fecal examination. Serology for *T. solium* was also negative (immunoblotting on serum and CSF, LD Bio, Lyon, France, performed at the Parasitology Laboratory, San Matteo Hospital Foundation, Pavia, Italy). The low platelet count precluded cerebral biopsy; therefore, the patient was started on empiric treatment with albendazole 15 mg/kg in two divided doses plus low-dose steroidal therapy with dexamethasone 4 mg bid. An ophthalmologic

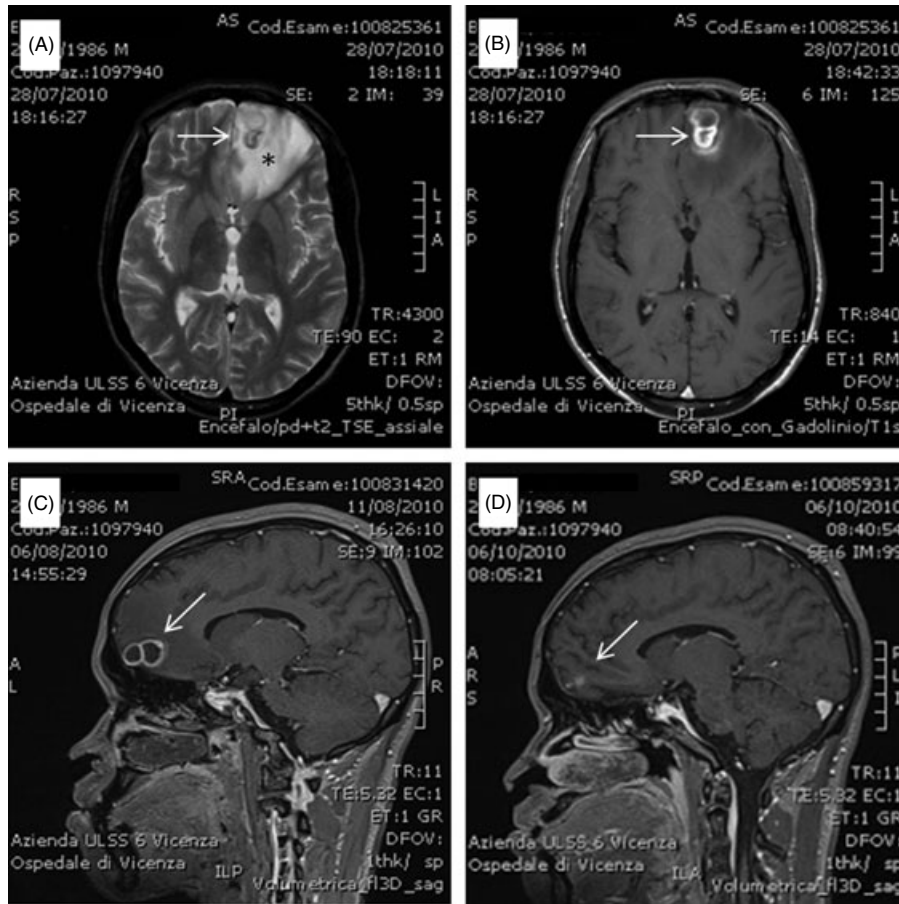


Figure 2 Case 2. (A and B) Pretreatment magnetic resonance (MR) showing a frontal-basal lesion on the left hemisphere with multiple cystic areas with content isointense with cerebrospinal fluid (CSF) (arrows) and surrounded by edema (star). (A) T2-weighted image (WI) and (B) T1-WI. (C) T1-WI MR executed 3 weeks later showing the lesion unchanged (arrow) after anti-*Toxoplasma*, broad-spectrum antibiotic and antifungal and antitubercular therapy. (D) T1-WI MR executed 48 days after start of albendazole and steroidal therapy showing substantial reduction of the lesion size with disappearance of the cystic component and perilesional edema (arrow).

evaluation including fundoscopic examination was performed before and after treatment started, with a negative result. The therapy was well tolerated and no paradoxical reactions occurred. After 48 days of treatment, near-complete disappearance of the brain lesion was seen on MR (Figure 2D). The serology for *T solium* was repeated 6 months after treatment (ELISA IgG Tenia Solium, DRG Instruments, Marburg, Germany, and Immunoblotting, LD Bio, performed at the Parasitology Laboratory, Don Calabria Hospital, Negrar, Verona, Italy) which again returned negative.

Patient 3

A 55-year-old woman born and raised in Brazil, previously diagnosed with NCC and treated with ventriculo-peritoneal drainage in 1999 in her country, was admitted to San Bortolo Hospital following progressive loss of consciousness in February 2012.

A brain CT scan showed hydrocephalus, multiple small calcifications in the cerebral parenchyma,

and inhomogeneous space-occupying lesions in the cerebellum (Figure 3A and B) and in the right parietal-occipital area. MR showed a cystic lesion surrounded by marked edema in the cerebellar vermis (Figure 3C) and confirmed the hydrocephalus (Figure 3C) and right parietal-occipital cystic lesion surrounded by edema (Figure 3D). Serology for *T solium* returned positive in serum and liquor in two repeated tests (ELISA Ig G Tenia Solium, DRG Instruments, and Immunoblotting, LD Bio, performed at the Parasitology Laboratory, Don Calabria Hospital, Negrar, Verona, Italy). Analysis of the CSF showed signs of disruption of blood-brain barrier (proteins 72 mg/dL and WBC 300/field, mainly lymphocytes). No ocular localizations were found during the fundoscopic examination.

The patient underwent surgical replacement of the ventricular drainage and medical therapy with intravenous dexamethasone 4mg bid and oral albendazole 15 mg/kg/day in two divided doses for 1 month. The neurological conditions improved quickly, no

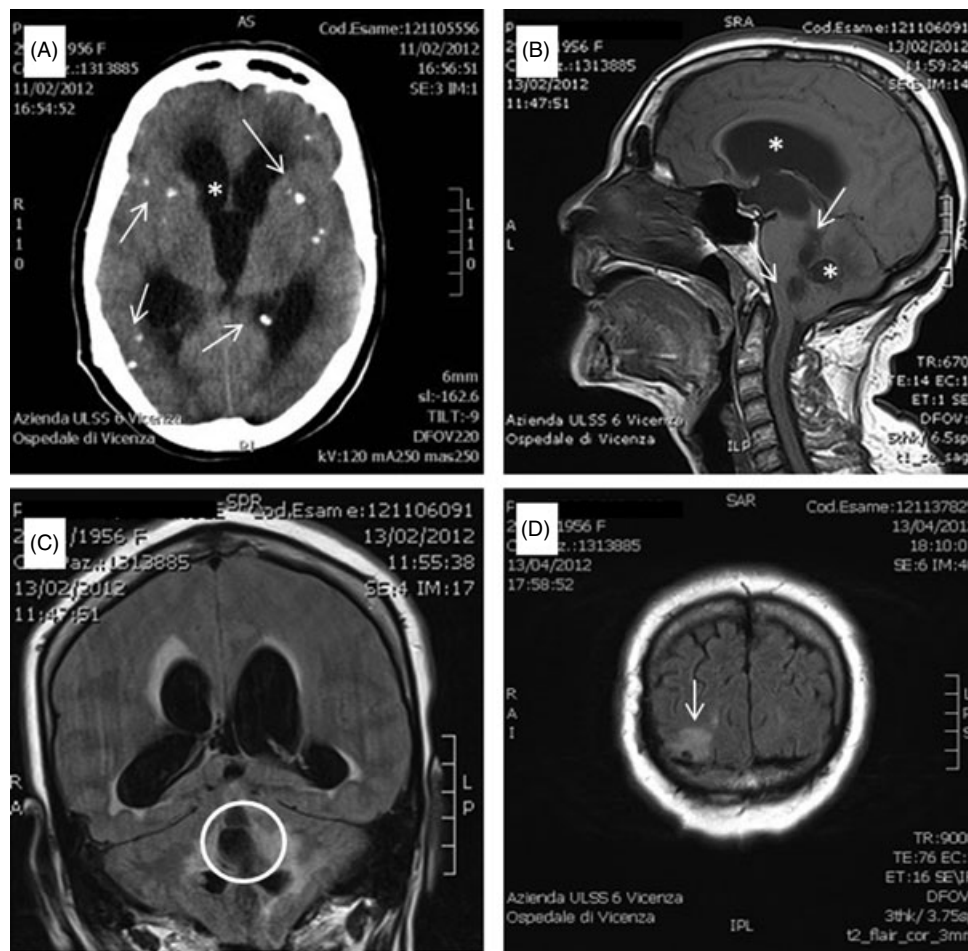


Figure 3 Case 3. (A) TC showing multiple calcified nodules in both hemispheres (arrows) and ventricular dilation (star). (B) T1-weighted image (WI) showing cystic lesion in the medulla oblongata (arrow) surrounded by edema and ventricular dilation (star). (C) T2-WI magnetic resonance (MR) showing the details of an extraparenchymal intraventricular cyst in the IV ventricle (circle). (D) T2-WI MR showing a small parietal-occipital cystic lesion in the right surrounded by edema (arrow).

paradoxical reactions to the treatment were recorded, and on discharge she did not show any neurological deficit. A follow-up was strongly recommended on her return to Brazil.

Discussion

Human NCC is considered a rare disease in Italy, but the last review on Italian cases dates back to 1986,⁵ and although notification of *T solium* infection and/or NCC in humans is mandatory in Italy, there is no national register for human cases. Seven autochthonous and 27 imported cases of NCC were reported in Italy from 1990 to 2011.⁶

The infection with the adult parasite is often long-lasting and asymptomatic, and the cystic larval forms can persist in the brain for years without causing symptoms, which may eventually develop, most of the times as a consequence of cyst degeneration and induction of perilesional inflammation.^{7,8}

In patient 1, the long period between immigration and development of seizures is not surprising; particularly, in the case of a single granuloma, seizures can be considered a late manifestation of a disease acquired many years before.⁹ On the contrary, patient 2, who had a previous negative CT scan in 2009, could have been infected in Italy. Indeed, carriers of *T solium* may represent the source of the infection in nonendemic countries, particularly for close contacts, in the absence of infected swine in the territory.^{4,10,11}

The diagnosis and treatment of NCC are complex and made more difficult owing to the poor knowledge of this disease in nonendemic countries.¹² Moreover, even when NCC is suspected, a negative serology does not rule out the infection, as patients with only one lesion are often seronegative.¹² In a review of case reports and case series of patients with single cysticercus granulomas in nonendemic areas, 41% of cases had a negative serology.⁹ The behavior of serology in HIV-positive patients is also still unclear.^{13,14} In

Table 1 Summary of the epidemiological, clinical, laboratory, and instrumental data of the three patients

	Age/ gender	Country of origin	Length of immigration	Clinical presentation	Classification	Neuroimaging	EITB	Comorbidities	Treatment
Case 1	34 years/M	Senegal	8 years	Recurrent seizures	Single parenchymal lesion, active	Single viable parenchymal lesion with two adjacent cysts, edema	Negative on serum and CSF	—	Surgery and steroids, ABZ (8 days), and PZQ (single)
Case 2	24 years/M	Burkina Faso	6 years	Single seizure, delirium	Single parenchymal lesion, active	Single viable parenchymal lesion with two adjacent cysts, edema	Negative on serum (before and after therapy)	HIV2/AIDS	Steroids and ABZ (60 days)
Case 3	55 years/F	Brazil	1 month	Lethargy, intracranial hypertension, meningoen- cephalitis	Multiple parenchymal active and calcified lesions, extra- parenchymal NCC	Multiple cerebral lesions, calcified nodules, intraventricular cyst, ventricular dilatation	Positive on serum and CSF	—	Ventricular drainage, steroids, and ABZ (28 days)

EITB = enzyme-linked immunoelectrotransfer blot; CSF = cerebrospinal fluid; NCC = neurocysticercosis.

these cases, the importance of repeating the serological tests after treatment of a seronegative case to detect seroconversion has been pointed out,¹⁵ but it was not diagnostic in our case. To make matters worse, *T solium* serology is not available in many European centers, including our hospital; therefore, samples need to be sent to a referral laboratory.

The imaging of brain lesions is the cornerstone of NCC diagnosis. The epidemiology of brain lesions varies between geographical areas, with single lesions being mainly found in India and multiple cysticerci in different stages being found in Asia, Africa, and Latin America.¹⁰ In our series, this is the case in patient 3, from Brazil, while the limited number of cysts in the patients from Sub-Saharan Africa may result from mild infection.¹⁰ A set of diagnostic criteria to classify NCC cases as definitive or probable has been formalized by a group of experts.¹⁶ All three cases were accordingly classified as definitive NCC (Table 1).

The differential diagnosis of NCC includes noninfectious (neoplasm, vascular malformations, and scars) and infectious lesions [bacterial or fungal abscess, neuro-toxoplasmosis, cerebral toxocariasis, cryptococcosis, tuberculosis (TB), and strongyloidiasis]. NCC in HIV-infected patients poses the most difficult problems in the differential diagnosis and in the therapeutic approach, as different pathogens can coexist and produce cerebral lesions having similar appearance on CT and MR.¹⁷ In HIV-positive patients with a CD4 count <200/mm³, toxoplasmosis is the most frequent cause of cerebral necrotic lesions. However, these are more often multiple and lack a clear cystic appearance. The lack of response to anti-*Toxoplasma*

therapy can be a valid diagnostic aid, while the result of serology for *Toxoplasma* can be misleading. Massive infections with *Mycobacterium tuberculosis* and *Strongyloides stercoralis* are other possible causes of cerebral lesions.^{18,19} In our case, these etiologies were ruled out by serology, unsuccessful TB treatment, and stool examination. Although *S stercoralis* serology can be negative in immunocompromised patients with hyperinfection syndrome and disseminated strongyloidiasis, treatment with albendazole is generally poorly effective, and gastrointestinal and cutaneous symptoms are more frequent.^{19,20} Albendazole and praziquantel are commonly used to treat active NCC and treatment should be based on NCC staging and presence or absence of eye involvement, taking into account both the risk of adverse reactions after treatment due to inflammation exacerbation and the benefit of treatment in patients with recurrent seizures.^{6,21,22} Patient 1 received pharmacological therapy after surgery, therefore a short treatment was considered appropriate. In HIV patients, treatment of cerebral parenchymal abscesses is recommended to avoid the development of a calcified lesion,^{23,24} and the concomitant use of steroids is mandatory in these cases to reduce the risk of a paradoxical reaction.²⁵ Furthermore, a long-term treatment was chosen in this case given the presence of a viable lesion^{26,27} and the patient's general condition.

Finally, in patient 3, emergency drainage was needed prior to any other therapy because of mental impairment due to ventricular dilatation.²⁸ Treatment with dexamethasone and albendazole with a prolonged course of 4 weeks was decided in this case of

extraparenchymal NCC,²⁹ which is known to have an aggressive behavior, and to reduce the edema and avoid the complications of arachnoiditis.²⁴

Conclusion

NCC should be included in the differential diagnosis of seizures, hydrocephalus, and compatible lesions on brain imaging in nonendemic countries, especially in patients from endemic areas, and in their household contacts.^{11,30} In developed countries, the risk of autochthonous transmission is small because of the high hygienic standards and control of meat production; however, household contacts of people carrying *T solium* are at higher risk.¹¹ The absence of pork consumption should not be a sufficient epidemiological element to exclude NCC.¹⁰ Indeed, the source of infection in these cases is most likely a contaminated food source, such as a contaminated handler, and in any case all household contacts of diagnosed NCC should be tested for infection. Unfortunately, this is not always possible because of the high mobility of immigrants. For the same reason, a long-term follow-up is difficult to obtain.

NCC should always be included in the differential diagnosis of brain lesions in HIV-positive patients especially if empiric antitoxoplasmosis therapy fails, and the interactions between NCC and HIV deserve further study.

Acknowledgments

We are particularly grateful to Sam Goblirsch, MD, for reviewing the manuscript. We also thank the Department of Neuroradiology, Vicenza Hospital and Daniela Danieli, MD, for providing the images and Alessandro Segna, MD, for reviewing the neurosurgical aspects.

Declaration of Interests

The authors state that they have no conflicts of interest.

References

1. Commission on Tropical Diseases of the International League Against Epilepsy. Relationship between epilepsy and tropical diseases. *Epilepsia* 1994; 35:89–93.
2. Chatel G, Gulletta M, Scolari C, et al. Neurocysticercosis in an Italian traveler to Latin America. *Am J Trop Med Hyg* 1999; 60:255–256.
3. Raffaldi I, Scolaro C, Mignone F, et al. An uncommon cause of seizures in children living in developed countries: neurocysticercosis—a case report. *Ital J Pediatr* 2011; 37:9.
4. Del Brutto OH. Neurocysticercosis in Western Europe: a re-emerging disease? *Acta Neurol Belg* 2012; 112:335–343.
5. Bussone G, La Mantia L, Frediani F, et al. Neurocysticercosis: clinical and therapeutic considerations. Review of Italian literature. *Ital J Neurol Sci* 1986; 7:525–529.
6. Del Brutto OH, Garcia HH. Neurocysticercosis in nonendemic countries: time for a reappraisal. *Neuroepidemiology* 2012; 39:145–146.
7. Garcia HH, Gonzalez AE, Evans CA, Gilman RH. *Taenia solium* cysticercosis. *Lancet* 2003; 362:547–556.
8. de Souza A, Nalini A, Kovoov JM, et al. Natural history of solitary cerebral cysticercosis on serial magnetic resonance imaging and the effect of albendazole therapy on its evolution. *J Neurol Sci* 2010; 288(1-2):135–141.
9. Del Brutto OH, Nash TE, Garcia HH. Cysticerci-related single parenchymal brain enhancing lesions in non-endemic countries. *J Neurol Sci* 2012; 319(1-2):32–36.
10. Winkler AS. Neurocysticercosis in sub-Saharan Africa: a review of prevalence, clinical characteristics, diagnosis, and management. *Pathog Glob Health* 2012; 106:261–274.
11. Moore AC, Lutwick LI, Schantz PM, et al. Seroprevalence of cysticercosis in an orthodox Jewish community. *Am J Trop Med Hyg* 1995; 53:439–442.
12. Garcia HH. Neurocysticercosis in immigrant populations. *J Travel Med* 2012; 19:73–75.
13. Garcia HH, Rodriguez S, Gilman RH, et al. Neurocysticercosis: is serology useful in the absence of brain imaging? *Trop Med Int Health* 2012; 17:1014–1018.
14. Foyaca-Sibat H, Cowan LD, Carabin H, et al. Accuracy of serological testing for the diagnosis of prevalent neurocysticercosis in outpatients with epilepsy, Eastern Cape province, South Africa. *PLoS Negl Trop Dis* 2009; 3:e562.
15. Dournon N, Epelboin L, Brion MC, et al. Seroconversion of neurocysticercosis occurring after anti-helminthic treatment. *J Travel Med* 2012; 19:383–386.
16. Del Brutto OH, Rajshkhar V, White AC Jr, et al. Proposed diagnostic criteria for neurocysticercosis. *Neurology* 2001; 57:177–183.
17. Lattuada E, Lanzafame M, Concia E, Vento S. Intracranial mass lesions in HIV/AIDS patients from developing countries endemic for neurocysticercosis. *Int J STD AIDS* 2007; 18:144–145.
18. Masdeu JC, Tantulavanich S, Gorelick PP, et al. Brain abscess caused by *strongyloides stercoralis*. *Arch Neurol* 1982; 39:62–63.
19. Buonfrate D, Requena-Mendez A, Angheben A, et al. Severe strongyloidiasis: a systematic review of case reports. *BMC Infect Dis* 2013; 13:78.
20. Mascarello M, Gobbi F, Angheben A, et al. Prevalence of *strongyloides stercoralis* infection among HIV-positive immigrants attending two Italian hospitals, from 2000 to 2009. *Ann Trop Med Parasitol* 2011; 105: 617–623.
21. Garcia HH, Evans CA, Nash TE, et al. Current consensus guidelines for treatment of neurocysticercosis. *Clin Microbiol Rev* 2002; 15:747–756.
22. Coyle CM, Tanowitz HB. Diagnosis and treatment of neurocysticercosis. *Interdiscip Perspect Infect Dis* 2009; 2009:180742.
23. Bhigjee AI, Rosemberg S. Optimizing therapy of seizures in patients with HIV and cysticercosis. *Neurology* 2006; 67(12 Suppl 4):S19–S22.
24. Nash TE, Garcia HH. Diagnosis and treatment of neurocysticercosis. *Nat Rev Neurol* 2011; 7:584–594.

25. Prasad S, MacGregor RR, Tebas P, et al. Management of potential neurocysticercosis in patients with HIV infection. *Clin Infect Dis* 2006; 42:e30–e34.
26. Garcia HH, Pretell EJ, Gilman RH, et al. A trial of antiparasitic treatment to reduce the rate of seizures due to cerebral cysticercosis. *N Engl J Med* 2004; 350: 249–258.
27. Del Brutto OH, Roos KL, Coffeyn C, et al. Meta-analysis: cysticidal drugs for neurocysticercosis: albendazole and praziquantel. *Ann Intern Med* 2006; 145:43–51.
28. Nash TE, Pretell EJ, Lescano AG, et al. Perilesional brain oedema and seizure activity in patients with calcified neurocysticercosis: a prospective cohort and nested case-control study. *Lancet Neurol* 2008; 7:1099–1105.
29. Figueroa JJ, Davis LE, Magalhaes A. Extraparenchymal neurocysticercosis in Albuquerque, New Mexico. *J Neuroimaging* 2011; 21:38–43.
30. Brunetti E, White AC Jr. Cestode infestations: hydatid disease and cysticercosis. *Infect Dis Clin North Am* 2012; 26:421–435.