

Tao Xie, MD, PhD
Issam Awad, MD
Un Jung Kang, MD
Peter Warnke, MD

DBS REDUCED HEMICHOREA ASSOCIATED WITH A DEVELOPMENTAL VENOUS ANOMALY AND MICROBLEEDING IN STN



Developmental venous anomaly (DVA) is the most common vascular malformation and is usually asymptomatic. Movement disorders associated with DVA have rarely been reported, except a case of hemichorea and hemiballism caused by DVA in the contralateral putamen associated with hyperglycemia.¹ The abnormal movements in that case nearly resolved after treatment with insulin and risperidone. We report a case of DVA who presented with hemichorea without metabolic derangement but microbleeding surrounding the DVA in the contralateral subthalamic nucleus (STN) area. The lesion was unresectable and deep brain stimulation (DBS) of globus pallidus interna (GPi) helped control the pharmacologically refractory symptoms.

This study provides Class IV evidence. It is a single observational study without controls.

Case report. A 22-year-old Caucasian man presented to our clinic with a 4-year history of hemichorea, with some myoclonic dystonic features, which started in his left hand and then gradually involved his whole left arm and left leg as well as his face to a lesser extent. His left hand function was severely impaired and his gait was mildly unsteady with occasional falls. He also felt socially embarrassed. He had no family history of neurologic diseases. He had type I diabetes, which was well-controlled by an insulin pump.

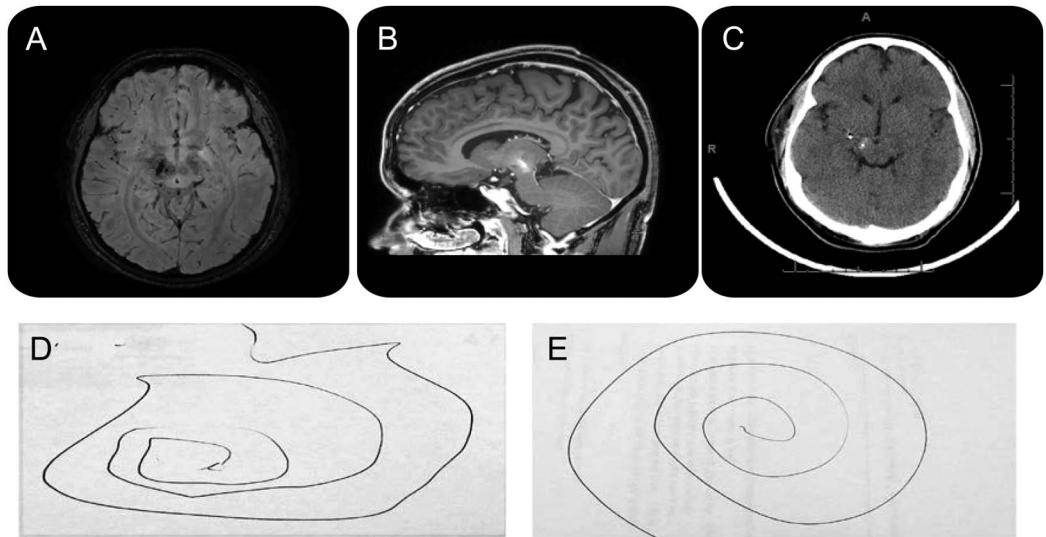
On examination, he had no other motor or sensory deficit. A brain MRI/magnetic resonance angiography showed a large DVA in the right cerebral peduncle–substantia nigra–STN–thalamic areas, which was confirmed by cerebral angiography. MRI VenBold also demonstrated punctate foci of susceptibility in the right STN and substantia nigra areas, suggesting microbleeding and small cavernous malformations (CMs) (figure, A and B). He was then treated with the maximum tolerated dose of clonazepam 2 mg TID, trihexyphenidyl 4 mg TID, and tetrabenazine 37.5 mg TID, but without benefit. He declined trying neuroleptics. Surgical resection was not an option given its location.

After a thorough discussion among the patient, our DBS team, and the neurovascular team, DBS

was pursued. A single trajectory DBS electrode was successfully placed to the right posteroventral GPi (stereotactic parameters related to the anterior and posterior commissure line were x/y/z of +21.9/+2.2/−2.1 mm) guided by the fusion of stereotactic head CT with MRI and a superimposed digital Schaltenbrand Atlas. The trajectory and functional target were carefully selected so as to avoid the cerebrovascular anomaly, with the final target 7 mm lateral to the most lateral part of the DVA (figure, C). There was good suppression of the abnormal movements in response to intraoperative macrostimulation. Postoperatively, his symptoms were well-suppressed by the DBS contacts of C+1− over the course of 10 months follow-up so far (figure, D and E, illustrating his improvement in drawing an Archimedes spiral after DBS at his 10-month postoperative visit, on 3.6 volts/120 μs/60 Hz). He responded better at 60 Hz than 130 Hz.

Discussion. DVA can have concomitant CM or telangiectasia,^{2,3} thrombosis with venous ischemia, or hemorrhage.⁴ There was only one previously reported case of abnormal movement caused by a DVA around the putamen area associated with hyperglycemia.¹ CMs of basal ganglia were previously reported in association with movement disorders.⁵ We report the first case of a movement disorder associated with DVA in the STN area, which was likely triggered by microbleeding associated with concomitant CM. Since our case involved a predominant DVA in an eloquent area and microbleeding rather than an overt CM, a resection strategy was not possible. Our case responded well to GPi DBS treatment. The improvement in motor performance was possibly associated with an increase in activation of those cortical areas involved in motor decision-making (supplementary motor area and anterior cingulate cortex) and execution (sensorimotor area), as demonstrated in a previous report using bilateral GPi DBS to improve chorea and motor performance in Huntington disease.⁶

On one hand, our case should raise the awareness of DBS treatment option in movement disorders caused by DVA and vascular complications in the basal ganglia, as the pharmacologic treatment of the movement disorders caused by these relatively common structural lesions could be difficult. On the other hand, we also



Brain MRI VenBOLD (A) and Sag Reformat (B) imaging before deep brain stimulation (DBS) placement show developmental venous anomaly and microbleeding, and head CT after DBS placement shows globus pallidus interna DBS location (C). Spirals drawn before (D) and 10 months after (E) DBS treatment show significant improvement in hand function with DBS treatment.

have to bear in mind that the DBS electrode trajectory and target should be chosen carefully so as to avoid the vascular anomaly, which was possible in this case, but may not always be possible with DVA or other cerebrovascular anomalies with complications causing movement disorders.

From the Department of Neurology (T.X.) and Department of Neurosurgery (I.A., P.W.), University of Chicago Medical Center, Chicago, IL; and Department of Neurology (U.J.K.), Columbia University Medical Center, New York, NY.

Author contributions: Tao Xie: drafting and revising the manuscript for content and analysis of data, intraoperative monitoring, DBS programming. Issam Awad: revising the manuscript for content and analysis of data. Un Jung Kang: revising the manuscript for content and analysis of data. Peter Warnke: revising the manuscript for content and analysis of data, performing the surgery.

Study funding: No targeted funding reported.

Disclosure: T. Xie and I. Awad report no disclosures. U. Kang is on the medical advisory board of CVS/Caremark. P. Warnke reports being Associate Editor of the Journal of Neurology, Neurosurgery and Psychiatry. Go to Neurology.org for full disclosures.

Received June 26, 2013. Accepted in final form October 14, 2013.

Correspondence to Dr. Xie: txie@bsd.uchicago.edu

© 2014 American Academy of Neurology

1. Kalia LV, Mozessohn L, Aviv RI, et al. Hemichorea-hemiballism associated with hyperglycemia and developmental venous anomaly. *Neurology* 2012;78:838–839.
2. Abla A, Wait D, Uschold T, Lekovic GP, Spetzler RF. Developmental venous anomaly, cavernous malformation, and capillary telangiectasia: spectrum of a single disease. *Acta Neurochir* 2008;150:487–489.
3. Ku MG, Rhee DY, Park HS, Kim DN. Repeated intracerebral hemorrhage from developmental venous anomaly alone. *J Korean Neurosurg Soc* 2009;45:46–49.
4. Walsh M, Parmar H, Mukherji SK, Mamourian A. Developmental venous anomaly with symptomatic thrombosis of the draining vein. *J Neurosurg* 2008;109:1119–1122.
5. Gross BA, Batjer HH, Awad IA, Bendok BR. Cavernous malformations of the basal ganglia and thalamus. *Neurosurgery* 2009;65:7–19.
6. Moro E, Lang AE, Strafella AP, et al. Bilateral globus pallidus stimulation for Huntington's disease. *Ann Neurol* 2004;56:290–294.