

# A follow-up $^{18}\text{F}$ -FDG brain PET study in a case of Hashimoto's encephalopathy causing drug-resistant status epilepticus treated with plasmapheresis

Elisa Pari · Fabrizio Rinaldi · Enrico Premi · Maria Codella ·  
Renata Rao · Barbara Paghera · Maria Beatrice Panarotto ·  
Giovanni De Maria · Alessandro Padovani

Received: 25 September 2013 / Revised: 19 December 2013 / Accepted: 19 December 2013  
© Springer-Verlag Berlin Heidelberg 2014

**Abstract** Hashimoto's encephalopathy (HE) is a rare neuropsychiatric syndrome associated with antithyroid antibodies. It may have an acute onset (episodes of cerebral ischemia, seizure, and psychosis) or it may present as an indolent form (depression, cognitive decline, myoclonus, tremors, and fluctuations in level of consciousness). We here describe a case of encephalopathy presenting as non-convulsive status epilepticus associated with Hashimoto's thyroiditis (HT), unresponsive to corticosteroid therapy, with improvement after plasma exchange treatment. A previously healthy 19-year-old woman, presented generalized tonic-clonic seizures. About a month later, she manifested a speech disorder characterized by difficulties in the production and comprehension of language. Within a few days she also developed confusion and difficulties in recognizing familiar places, with gradual worsening over time. EEG revealed a non-convulsive status epilepticus (NCSE). CSF examination showed slightly elevated cell count and four oligoclonal bands. MRI was unremarkable, and  $^{18}\text{F}$ -FDG brain PET showed widespread hypometabolism, mostly in posterior regions bilaterally. Laboratory and ultrasound findings showed signs of HT. Treatment with steroid was introduced without any improvement. After five sessions of plasma exchange there

was a decrease of antithyroid antibodies, as well as EEG and clinical improvement. Three months after discharge  $^{18}\text{F}$ -FDG brain PET showed a complete normalization of the picture, and the patient was asymptomatic. This report emphasizes the successful treatment of HE with plasma exchange in a patient who presented with NCSE. Based on the actual evidence, the term "Encephalopathy associated with Hashimoto's thyroiditis" may be the most proper. Furthermore, to our knowledge, this is the first case of an adult patient studied twice with an  $^{18}\text{F}$ -FDG brain PET: prior to treatment with plasma exchange, and at 3 months follow-up when the patient was clinically completely asymptomatic. Studies in more patients are needed to clarify the relevance of  $^{18}\text{F}$ -FDG brain PET as a possible diagnostic tool for HE.

**Keywords** Hashimoto encephalopathy · NCSE ·  
 $^{18}\text{F}$ -FDG brain PET · Plasmapheresis · Thyroid antibodies

## Introduction

Hashimoto's encephalopathy (HE) is a rare neuropsychiatric syndrome associated with serologic evidence of antithyroid antibodies suggestive for Hashimoto's thyroiditis. It may have an acute onset, characterized by episodes of cerebral ischemia, seizure, and psychosis, or it may present as an indolent form with depression, cognitive decline, myoclonus, tremors, and fluctuations in level of consciousness. Hashimoto's encephalopathy has been reported in fewer than 200 cases so far [1], but a recent study suggested that the syndrome may be underdiagnosed, proposing an estimated prevalence of 2.1/100,000 [2].

Although the pathophysiological mechanism is not clear, a widespread immunologic process has been proposed. Nevertheless, a direct causal relationship between

---

E. Pari · F. Rinaldi (✉) · E. Premi · M. Codella · R. Rao ·  
A. Padovani  
Neurology Department, University Hospital "Spedali Civili",  
Brescia, Italy  
e-mail: rinaldi.fabrizio.riccardo@gmail.com

B. Paghera · M. B. Panarotto  
Nuclear Medicine Department, University Hospital "Spedali  
Civili", Brescia, Italy

G. De Maria  
Neurophysiology Department, University Hospital "Spedali  
Civili", Brescia, Italy

thyroid antibodies and encephalopathy is unlikely [3], and at present, it is unclear whether antithyroid antibodies represent an immune epiphenomenon in a subset of patients with encephalopathic processes or they are, in fact, causative of the disorder. Therefore, some authors consider the term “Hashimoto’s encephalopathy” inappropriate, and the term “steroid responsive encephalopathy associated with autoimmune thyroiditis” has been suggested, referring to the main treatment for HE [4].

Here we describe a case of encephalopathy presenting as non-convulsive status epilepticus (NCSE) associated with Hashimoto’s thyroiditis, unresponsive to corticosteroid therapy, with a marked clinical and electrophysiological improvement after plasma exchange treatment.

### Case report

In July and August of 2012, a 19-year-old, right-handed, previously healthy woman, born in Romania and living for 2 years in Italy, had two generalized tonic–clonic seizures. She did not have a history of trauma, contagious diseases, or drug or alcohol abuse. The family history, except for a maternal aunt affected by epilepsy, was unremarkable. EEG showed minimal increase of low voltage theta activity in the anterior regions. Neurological examination was within the normal range, and brain magnetic resonance imaging (MRI) did not reveal any abnormal findings.

Therefore, suspecting an idiopathic epilepsy, the patient started therapy with lamotrigine on slow titration (25 mg twice a day). A week later, while taking the medication, the patient had another seizure with similar features. EEG showed slow wave discharges in the fronto-temporal regions of the left hemisphere. Because of the recurrence of the seizures while taking lamotrigine, the drug was replaced with levetiracetam with a gradual progressive increase up to 750 mg twice a day.

About a month later, the patient manifested a new symptomatology. Relatives reported a speech disorder characterized by difficulties in production of language, involving at first the Italian language and then also the native Romanian language. Some days later, she also developed a marked impairment in comprehending both languages, and within a few days also confusion and difficulties in recognizing familiar places, with gradual worsening over time. Therefore, she was referred to our hospital.

Neurological examination at the admission revealed global aphasia with dysgraphia as well as dyslexia in both languages. The patient was only able to repeat bisyllabic words, performing occasionally simple commands, mostly on imitation. Soon after, the patient showed acute personality changes with psychomotor agitation, and occurrences

of despair and crying alternating with laughter and euphoria. Therapy with lacosamide was added, but the patient did not show any clinical improvement.

EEG now revealed continuous high amplitude rhythmic lateralized delta waves in the fronto-temporal regions, with a defined prevalence over the left hemisphere (Fig. 1a). These alterations were markedly reduced by the administration of intravenous benzodiazepine, raising the suspect of a non-convulsive status epilepticus. Therefore, a continuous intravenous infusion of diazepam was started, but the clinical picture showed only a mild and transient improvement.

Results of laboratory examination, including complete blood count, erythrocyte sedimentation rate test, and blood biochemical analyses were within normal limits, except for an increase value of C-reactive protein test. CSF examination showed a slightly elevated cell count (12 cells/ $\mu$ L, normal value <4) and four oligoclonal bands. Glucose and protein levels were normal; PCR was negative for herpesviruses, adenovirus, and enteroviruses. Considering cerebrospinal fluid findings, antiviral therapy with Acyclovir 500 mg three times a day was introduced.

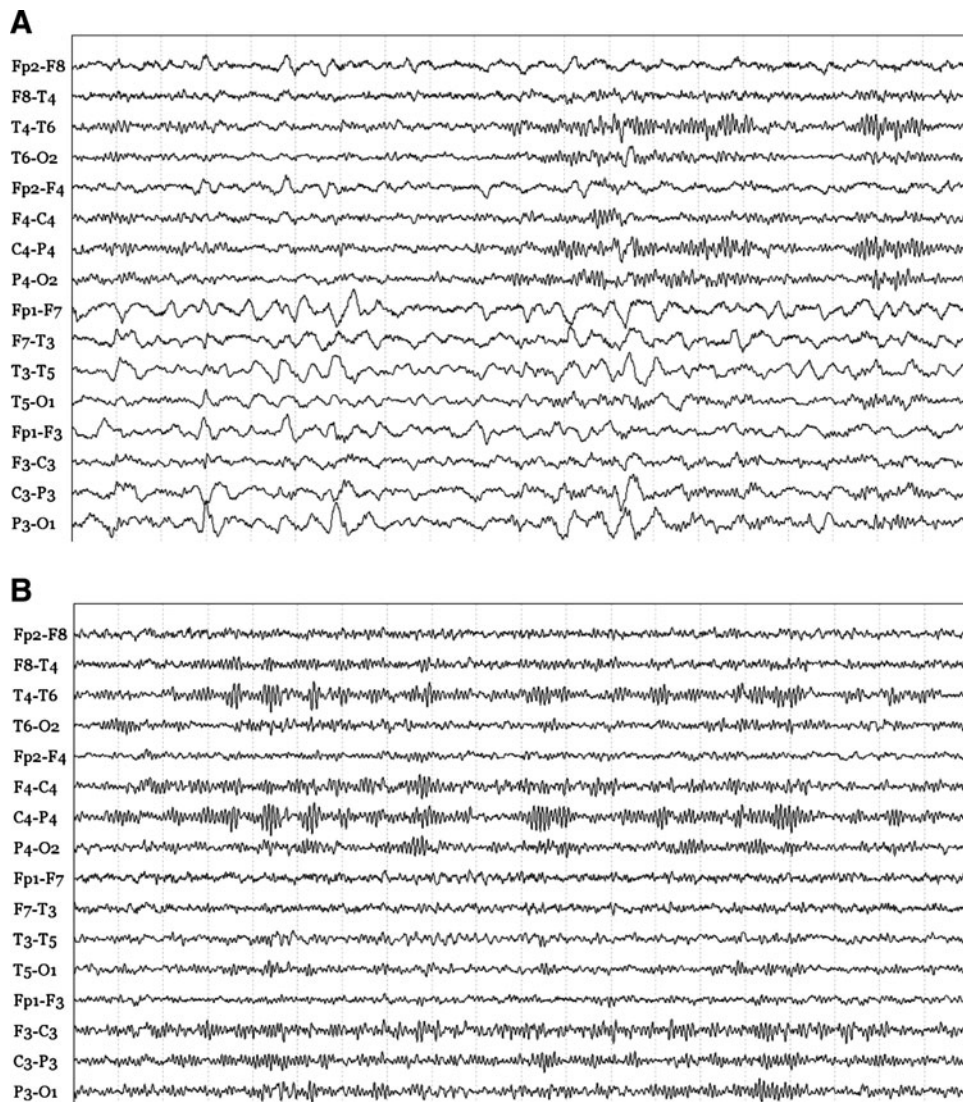
Sudden personality changes, along with persistent seizures, indicated limbic encephalitis, therefore the patient went under further neuroimaging examination.

A second brain MRI study (T1-weighted, T2-weighted, FLAIR, DWI, and contrast enhanced T1-weighted scans) was performed, still unremarkable. Conversely,  $^{18}$ F-FDG brain PET showed a deep hypometabolism in the left temporal lobe, insula, and ipsilateral temporo-occipital junction, and in the right superior parietal lobule (Fig. 2a). Furthermore, a CT scan of chest, abdomen and pelvis in pursuit of a primary neoplasm was also unrevealing. Finally, test results for voltage-gated potassium channel antibodies and anti-N-methyl-D-aspartate (NMDA) receptor antibodies were negative as well.

The clinical and electroencephalographic findings compatible with NCSE in the absence of detectable structural brain damage on MRI and the presence of functional alterations at  $^{18}$ F-FDG brain PET raised the suspicion of a possible encephalitis.

Laboratory findings showed a high serum level of anti-thyroid peroxidase antibodies (anti-TPO) (519 IU/mL; normal range <5.6 IU/mL) and of anti-thyroglobulin (anti-TG) antibodies (>1,000 IU/mL; normal range <4.1). Thyroid function tests revealed a subclinical hypothyroidism with normal levels of fT3 and fT4, and a slight increase of TSH (4.652 mU/L; normal range 0.27–4.20). The thyroid ultrasound showed a diffuse hypoechogenic pattern, consistent with a picture of autoimmune thyroiditis.

In view of the neurologic symptoms, associated with the high titre of antithyroid antibodies and the exclusion of other possible causes of encephalopathy, the patient was



**Fig. 1** **a** EEG showing continuous high amplitude rhythmic lateralized delta waves in the fronto-temporal regions, with a defined prevalence over the left hemisphere. Neurological examination revealed global aphasia with dysgraphia as well as dyslexia. **b** EEG

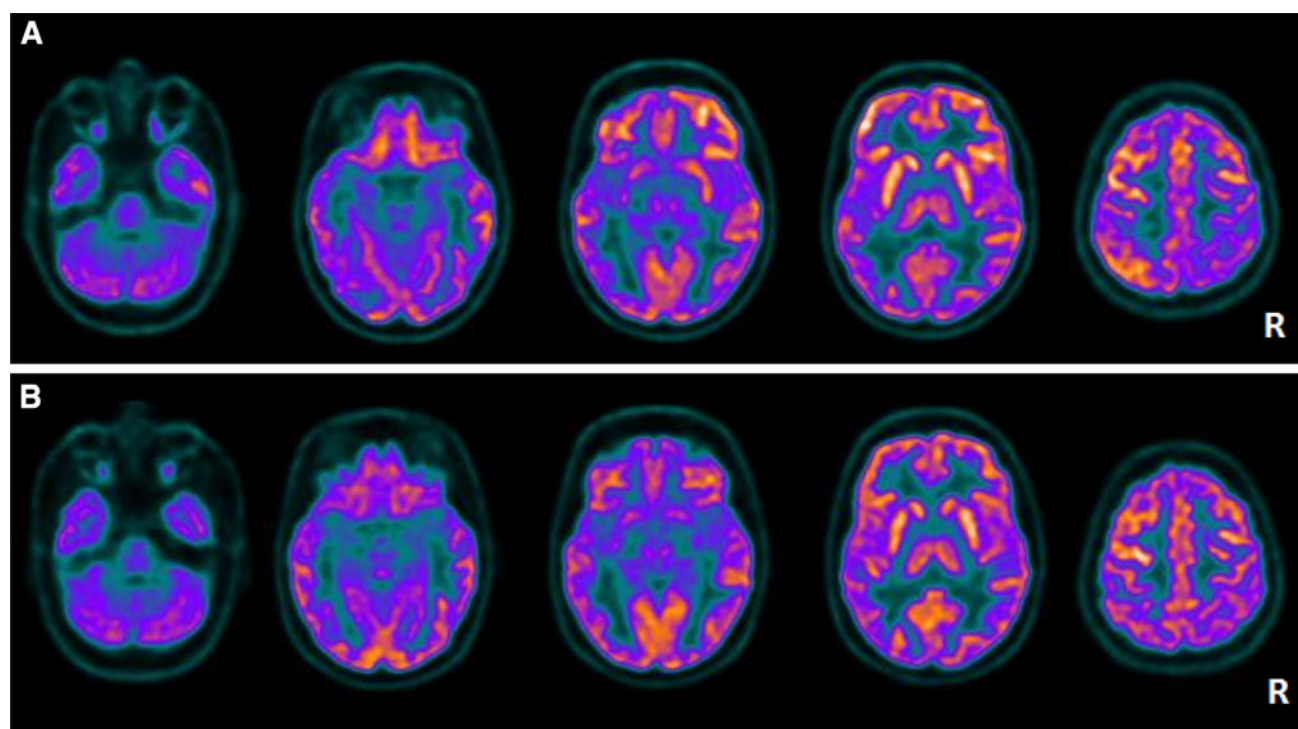
tracing documenting a marked improvement, with mild excess of theta activity in the same areas, 3 months after the treatment with plasmapheresis

diagnosed with HE. Treatment with steroid was initiated (methylprednisolone 1 g/die iv), but the patient did not show any significant improvement. After 8 days of steroid therapy without any benefit, plasmapheresis was performed. A dramatic clinical improvement in the production and comprehension of language was noted, in the absence of further episodes of behavioral agitation or emotional lability.

After five sessions of plasmapheresis there was a decrease of anti-TPO antibodies (30 IU/mL) and anti-TG antibodies (462 IU/mL) and a broad improvement of EEG with restoration of the basic rhythms, although mild excess of theta activity in the left fronto-temporal areas persisted (Fig. 1b).

The patient was then discharged and given levetiracetam 750 mg twice daily, lacosamide 200 mg twice daily and oral prednisone with progressive decalage down to 12.5 mg/day. Two months after discharge, the patient reported a sustained improvement on all parameters, making it possible for her to return to an almost normal routine.

Three months after discharge the patient repeated an  $^{18}\text{F}$ -FDG brain PET that showed a complete normalization of the picture with a normal cerebral glucose metabolism (Fig. 2b). EEG also documented a marked improvement. Clinically, the patient was asymptomatic.



**Fig. 2** **a**  $^{18}\text{F}$ -FDG brain PET showing a deep hypometabolism in the left temporal lobe, insula, and ipsilateral temporo-occipital junction, and in the right superior parietal lobule. **b**  $^{18}\text{F}$ -FDG brain PET

documenting a normalization of brain glucose metabolism 3 months after the treatment with plasmapheresis

## Discussion

The clinical presentation of Hashimoto's encephalopathy can vary, but often includes seizures, neuropsychiatric signs, motor problems, and cognitive impairment. This disease should be suspected when acute personality changes, seizures, and elevated serum levels of anti-thyroid antibodies are observed. EEG findings are usually non-specific. While the most frequently reported changes are generalized slow waves, a few reports showed a more lateralized slowing, which did not necessarily correlate with focal abnormalities detected on neurologic examination or neuroimaging study [5].

However, status epilepticus rarely occurs in patients with Hashimoto's encephalopathy [6]. Our patient exhibited fluctuating clinical presentations, including global aphasia, bizarre behaviour, psychosis, and confusion. Unfortunately, no cognitive evaluation was performed either before or after plasmapheresis. This is a major limitation of the report.

Ictal EEG demonstrated left lateralized high amplitude rhythmic delta waves associated with altered mental status, suggestive of complex partial status epilepticus [7], although the absence of a clear build-up rhythm makes this picture atypical. Furthermore, EEG

recordings performed during sleep showed a marked improvement.

It has been suggested that an autoimmune-complex deposition mediated by the anti-TPO and the anti-thyroglobulin antithyroid antibodies could be responsible for neuronal damage in the brain tissue [8]. This may account for EEG abnormalities, as in our patient; however, it is not clear why these alterations are prevalent in some specific regions. Intriguingly, an  $^{18}\text{F}$ -FDG brain PET performed at baseline revealed a deep hypometabolism in the left temporal lobe, insula, and ipsilateral temporo-occipital junction, and in the right superior parietal lobule. Furthermore, the  $^{18}\text{F}$ -FDG brain PET follow-up 3 months after onset showed a normalization of brain glucose metabolism in parallel with the clinical and electroencephalographic improvement of our patient (Fig. 2).

To our knowledge, our report is the first with an MRI, EEG, and  $^{18}\text{F}$ -FDG brain PET performed both before and after therapy in an adult patient with HE. One report presented  $^{18}\text{F}$ -FDG brain PET in two 14-year-old patients with HE who presented with recurrent seizures and mental decline. PET showed diffuse hypometabolic areas before therapy and a normalization after steroid treatment [9].

The meaning of these findings is not clear, and more studies are needed to clarify the status of cerebral glucose

metabolism in HE and if there is a possible role for  $^{18}\text{F}$ -FDG brain PET in diagnosis of HE.

Our patient exhibited prominent psychiatric signs, seizures, and aphasia, as observed in limbic encephalitis. However, the test result for anti-NMDA-receptor antibodies was negative. Therefore, treatment with corticosteroids was initiated after the results of high antithyroid antibody titres, but our patient responded to treatment with plasmapheresis and corticosteroids rather than the more common treatment with corticosteroids only.

Hashimoto's encephalopathy has historically been considered as being highly responsive to corticosteroid treatment; therefore, the terms "Hashimoto's encephalopathy" and "corticosteroid responsive encephalopathy associated with autoimmune thyroiditis" have been used interchangeably [10]. However, a recent esteem has found that the response to this treatment is far from being pathognomonic, as up to 4 % of cases do not gain any improvement [11]. Therefore, the use of this definition can lead to some confusion and may eventually be inappropriate to use a concept that may not encompass all cases. Based on the actual evidence, the term "Encephalopathy associated with Hashimoto's thyroiditis" may be the most proper, designating an association with the anti-thyroid antibodies that are essential for the diagnosis.

Moreover, the seizures were controlled only with plasmapheresis. To the best of our knowledge, few cases of adult patients and one child with HE treated with plasmapheresis were previously reported [12, 13]. In addition, there are no reports of drug-resistant status epilepticus that responded to plasmapheresis in adults.

In our patient high doses of corticosteroids brought only slight improvements, while the neuropsychological symptoms ceased soon after the start of plasmapheresis, with EEG findings and antithyroid antibody serum levels improving together; and the patient consequently completely returned to baseline.

Indeed, so far we do not have reliable information on the effectiveness of other immune suppressive agents (azathioprine, cyclophosphamide, methotrexate, IV immunoglobulins and plasmapheresis), since data are based on single case reports. It is therefore desirable that further studies are carried out to test the effectiveness and the risk profile of each treatment. Moreover, a randomized, placebo-controlled study is necessary in order to verify the common opinion that HE is a steroid-responsive condition.

This report emphasizes the successful treatment of HE with plasmapheresis in a patient who presented with status epilepticus, and may serve to alert neurologists of the need to consider the possibility of HE during the examination of unresponsive patients with encephalopathies.

Early diagnosis of autoimmune encephalitis is desirable, and  $^{18}\text{F}$ -FDG brain PET could be useful for this purpose. It remains to be determined how early changes on FDG PET are seen in the course of encephalitis and how long they persist after symptoms have been resolved. More studies with serial FDG PET may help to determine the time course of FDG PET findings and to clarify the relevance of PET as an adjunct to lumbar puncture, EEG, and clinical findings in the management of patients with a suspicion of autoimmune encephalitis.

**Conflicts of interest** None.

**Ethical standard** The procedures were approved by a local ethical standards committee on human experimentation.

## References

- Huang W, Xia C, Chatham M (2011) Infectious disease or Hashimoto's encephalopathy flares: a case report. *Seizures* 20:717–719
- Ferracci F, Bertiato G, Moretto G (2004) Hashimoto's encephalopathy: epidemiologic data and pathogenetic considerations. *J Neurol Sci* 217:165–168
- Castillo P, Boeve B, Schäuble B et al (2002) Steroid-responsive encephalopathy associated with thyroid autoimmunity: clinical and laboratory findings. *Neurology* 58(Suppl3):A248
- Mocellin R, Walterfang M, Velakoulis D (2007) Hashimoto's encephalopathy: epidemiology, pathogenesis and management. *CNS Drugs* 21(10):799–811
- Schauble B, Castillo PR, Boeve BF, Westmoreland BF (2003) EEG findings in steroid-responsive encephalopathy associated with autoimmune thyroiditis. *Clin Neurophysiol* 114:32–37
- Tsai M-H (2007) Complex partial status epilepticus as a manifestation of Hashimoto's encephalopathy. *Seizure* 16(8):713–716
- Meierkord H, Holtkamp M (2007) Non-convulsive status epilepticus in adults: clinical forms and treatment. *Lancet Neurol* 6:329–339
- Henchey R, Cibula J, Helveston W, Malone J, Gilmore RL (1995) Electroencephalographic findings in Hashimoto's encephalopathy. *Neurology* 45:977–981
- Maydell BV, Kopp M, Komorowski GV, Joe A, Juengling FD, Korinthenberg R (2002) Hashimoto's encephalopathy—is it underdiagnosed in pediatric patients? *Neuropediatrics* 33(2):86–89
- Tamagno G, Federspil G, Murialdo G (2006) Clinical and diagnostic aspects of encephalopathy associated with autoimmune thyroid disease (or Hashimoto's encephalopathy). *Intern Emerg Med* 1:15–23
- Chong JY, Rowland LP, Utiger RD (2003) Hashimoto's encephalopathy: syndrome or myth? *Arch Neurol* 60:164–171
- Boers PM, Colebatch JG (2001) Hashimoto's encephalopathy responding to plasmapheresis. *J Neurol Neurosurg Psychiatry* 70:132
- Bektas Ö, Yılmaz A, Kendirli T, Sıklar Z, Deda G (2012) Hashimoto's encephalopathy causing drug-resistant status epilepticus treated with plasmapheresis. *Pediatr Neurol* 46(2):132–135. doi:10.1016/j.pediatrneurol.2011.11.009