

Restoration of brain function in an elderly man

Shigetoshi Hosaka,¹ Hiroshi Higuchi,² Takato Kagawa³

¹Ohchi Hospital, Ohchi gun, Japan

²Department of Internal Medicine, Ohchi Hospital, Shimane, Japan

³Department of Neurosurgery, National Hospital Organization Hamada Medical Center, Shimane, Japan

Correspondence to

Dr Shigetoshi Hosaka, hosaka-shigetoshi@ohchihospital.jp

DESCRIPTION

An 84-year-old man who hit his head 2 months previously presented with indistinct consciousness, right-partial paralysis and aphasia. He had been in good health with no evidence of coagulopathy or haemorrhagic diathesis. CT showed a diffuse isodense lesion in the left frontoparietal region with brain shift (figure 1A). A diagnosis of chronic subdural haematoma (SDH) was made and he was treated with burr hole drainage four times.¹ The initial drainage was applied to treat the SDH, and the others were required for treatment of bleeding after drainage. After 127 days, CT revealed gradual shrinkage of the haematoma, brain shift and a separate membrane around the SDH (figure 1B). The patient still showed the same clinical disturbances. The follow-up CT demonstrated the disappearance of brain shift after 189 days (figure 1C). At this time, he became alert and had no paresis and no difficulty in speech. CT after 520 days showed only a small area of haematoma (figure 1D) without treatment after the initial

four rounds of neurosurgery.² He recovered and is now able to drive a car safely.

Learning points

- ▶ Chronic subdural haematoma (SDH) should be considered in cases of consciousness disturbance, paralysis and gait disturbance among elderly patients.
- ▶ A long follow-up period was necessary for recovery from the brain lesion in this case.

Contributors SH, HH and TK contributed in the patient management and in the editing of the manuscript.

Competing interests None.

Patient consent Obtained.

Provenance and peer review Not commissioned; externally peer reviewed.

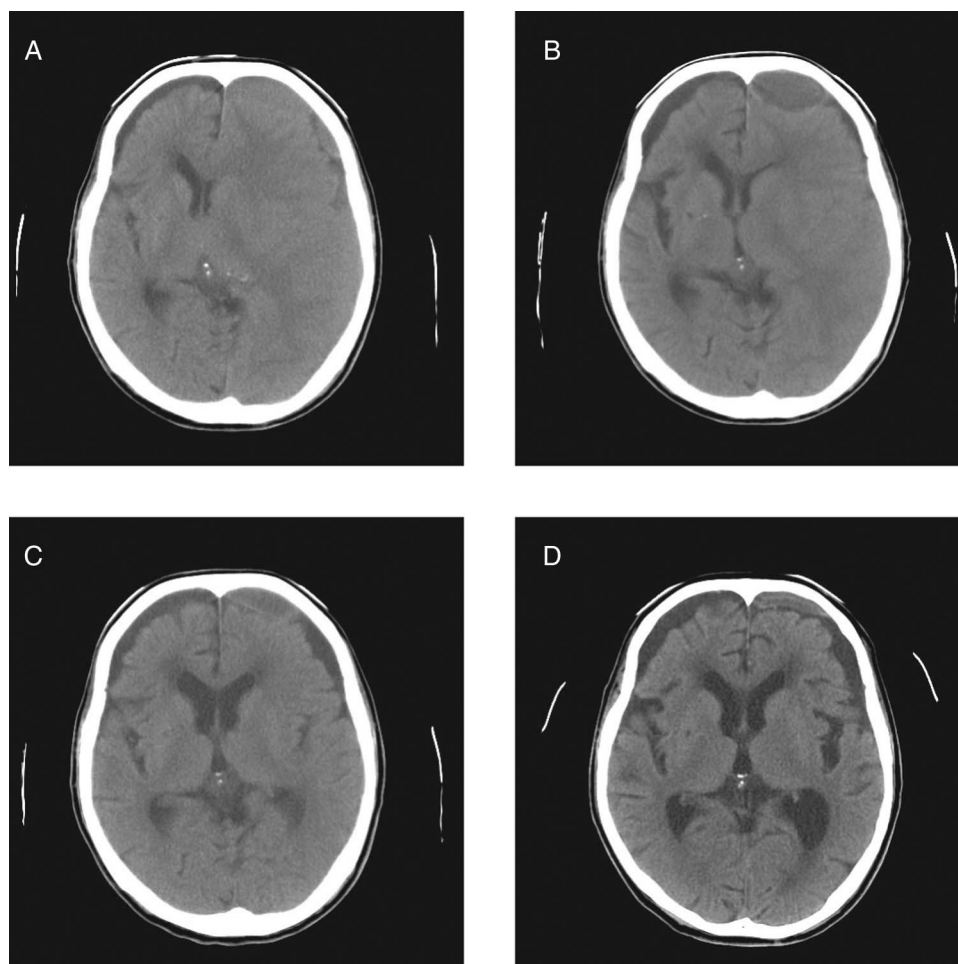


Figure 1 Recovery of brain damage. (A) Cerebral CT scan on admission. (B) Cerebral CT scan on day 127. (C) Cerebral CT scan on day 189. (D) Cerebral CT scan on day 520.



CrossMark

To cite: Hosaka S, Higuchi H, Kagawa T. *BMJ Case Rep* Published online: [please include Day Month Year] doi:10.1136/bcr-2013-202118

REFERENCES

- 1 Santarius T, Kirkpatrick P, Ganesan D, *et al*. Use of drains versus no drains after burr-hole evacuation of chronic subdural haematoma: a randomized controlled trial. *Lancet* 2009;347:1067–73.
- 2 Parlato C, Guarracino A, Moraci A. Spontaneous resolution of chronic subdural hematoma. *Surg Neurol* 2000;53:312–17.

Copyright 2014 BMJ Publishing Group. All rights reserved. For permission to reuse any of this content visit <http://group.bmj.com/group/rights-licensing/permissions>.
BMJ Case Report Fellows may re-use this article for personal use and teaching without any further permission.

Become a Fellow of BMJ Case Reports today and you can:

- ▶ Submit as many cases as you like
- ▶ Enjoy fast sympathetic peer review and rapid publication of accepted articles
- ▶ Access all the published articles
- ▶ Re-use any of the published material for personal use and teaching without further permission

For information on Institutional Fellowships contact consortiasales@bmjgroup.com

Visit casereports.bmj.com for more articles like this and to become a Fellow