

CASE REPORT

Extrapyramidal syndrome

Akhila Kumar Panda, Kiran Bala, Lomesh Bhirud

Department of Neurology,
Institute of Human Behaviour
& Allied Sciences (IHBAS),
Delhi, Delhi, India

Correspondence to

Dr Akhila Kumar Panda,
drakhilapanda@gmail.com

SUMMARY

Organophosphate (OP) poisoning is a common occurrence in the rural areas of developing countries like India. Acute cholinergic crisis is one of the important causes of mortality related to OP poisoning. Delayed peripheral neuropathy, extrapyramidal syndromes and neuropsychiatric manifestations are the major consequences of secondary neuronal damage. This case illustrates a 14-year-old girl who ingested 50 mL of OP pesticide and developed extrapyramidal symptoms in the form of parkinsonism and hand dystonia in spite of immediate medical attention. MRI of the brain with T2, fluid attenuated inversion recovery and diffusion-weighted sequences revealed bilateral symmetrical basal ganglia hyperintensities. Further follow-up revealed a significant clinical improvement with marked resolutions of the brain lesions. The reversible extrapyramidal symptoms with disappearance of neuroimaging findings without neuropathy or neuropsychiatric manifestations are unusual in OP poisoning.

BACKGROUND

Organophosphate (OP) poisoning is a leading cause of suicidal death in the rural areas of developing countries.¹ Clinical manifestations of OP poisoning depend on the type of compound, amount of ingestion, route of administration, length of exposure, time of accessibility of healthcare system and expertise management. Cholinergic excitotoxicity due to irreversible inhibition of acetylcholine (ACh) esterase and neurotransmitter deficits are the leading causes of secondary neuronal damage.² Cholinergic crisis and intermediate syndrome are the main reasons for death in acute OP poisoning. The chronic and longstanding exposure results in delayed polyneuropathy known as OP-induced delayed polyneuropathy (OPIDP). In addition, a few cases have been reported regarding atypical central nervous system (CNS) manifestations including choreoathetosis, parkinsonism, opisthotonus, torticollis, facial grimacing and neuropsychiatric features.³ The role of neuroimaging in extrapyramidal manifestation of OP poisoning is unclear.⁴ The correlation between neuroimaging and severity of illness is also debated.

CASE PRESENTATION

A 14-year-old girl, self-deliberately ingested approximately 50 mL of OP pesticide at her home. She was found in a state of poor respiratory effort with vomits, stool and sweat all over her body. She was hospitalised within 2 h of ingestion. In the emergency room, her Glasgow Coma Scale outcome score was 5 (E2M2V1), blood pressure 90/60 mm Hg, pulse rate 50 bpm and respiratory

rate was 10/min. Respiratory examination revealed diffuse bilateral pulmonary crackles and wheeze in both lung fields. She received immediate medical attention with mechanical ventilation followed by gastric lavage, intravenous infusion of atropine and pralidoxime therapy. She was on respiratory support for 4 weeks, after which she gradually recovered and was shifted to the medicine ward. She was noticed to have a change in gait in the form of walking with short-shuffling narrow-based steps with reduced arm swing along with bilateral hand dystonia. Her speech became hypophonic and monotonous.

General physical examination revealed a thinly built body with normal vital parameters. Cardiovascular, respiratory and gastrointestinal examinations were unremarkable. CNS examination revealed normal higher mental functions. Mini-Mental Status Examination was 28/30 (writing and copying overlapping pentagon were not possible due to hand dystonia). Cranial nerves including fundus examination were normal. Speech was low volume and monotonous, suggestive of hypokinetic dysarthria. Motor system examinations showed moderate cogwheel rigidity in upper and lower limbs along with mild axial rigidity. The power of lower and upper limbs were normal. Deep tendon reflexes were normal in all four limbs with bilateral flexor plantar response. She had generalised bradykinesia and bilateral upper limb dystonia along with dystonic tremor. She developed extrapyramidal gait in the form of slow, short-

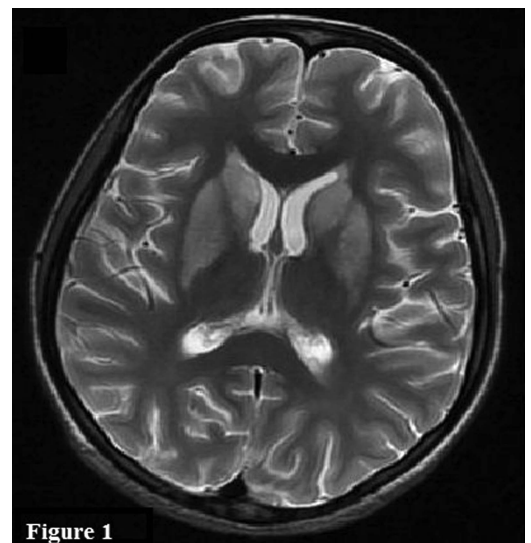


Figure 1 T2-weighted sequence of MRI of the brain showing symmetrical hyperintensity in bilateral basal ganglia.



CrossMark

To cite: Panda AK, Bala K, Bhirud L. *BMJ Case Rep* Published online: [please include Day Month Year] doi:10.1136/bcr-2013-009752

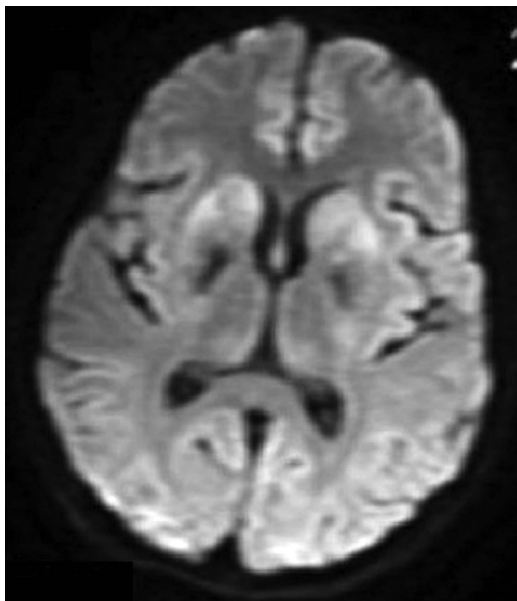


Figure 2 Diffusion-weighted image showing restriction diffusion in bilateral basal ganglia.

shuffling narrow based with turning en bloc and decreased arm swing without start hesitation, freezing or festination. Sensory, cerebellar and autonomic functions were normal.

Routine investigations including complete blood count, liver, renal and thyroid function test were normal. MRI of the brain with T2 and fluid attenuated inversion recovery (FLAIR) sequences showed bilateral symmetrical basal ganglia hyperintensities with diffusion restriction in diffusion-weighted sequence (figures 1 and 2). T1-weighted image showed symmetrical hypointensity in bilateral globus pallidus (figure 3). Nerve conduction study (NCS) revealed no abnormalities. Serum

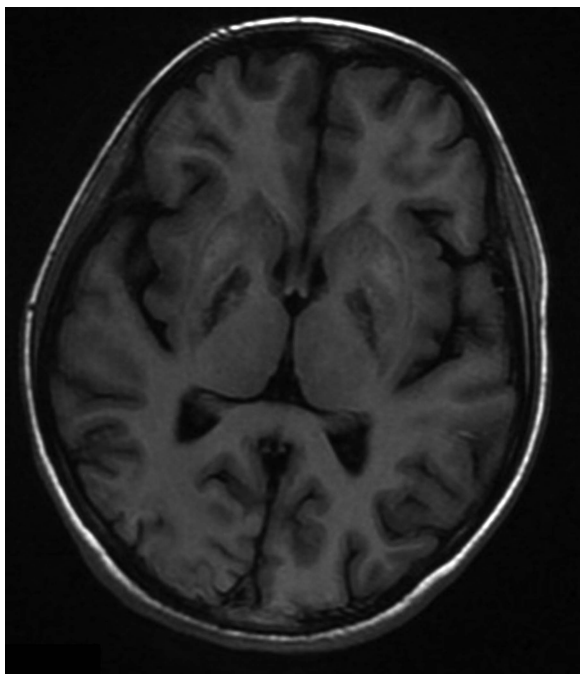


Figure 3 T1-weighted sequence showing hypointense lesion in bilateral basal ganglia.

ceruloplasmin, copper and 24-h urinary copper levels were within normal limits. Her chest X-ray and abdomen ultrasonogram were non-contributory.

She was subsequently treated with trihexiphenidyl (2 mg twice daily), low dose of levodopa and carbidopa combination (125 mg twice daily), amantadine (100 mg twice daily), neuro-rehabilitation including physiotherapy and occupational therapy. After 2 weeks of treatment, her limb rigidity, bradykinesia and gait abnormality gradually improved and speech became clear, but hand dystonia persisted.

OUTCOME AND FOLLOW-UP

Follow-up after 1 month showed recovery from extrapyramidal symptoms (EPS) including rigidity, gait abnormality, speech and facial expression, except the presence of minimal hand dystonia. MRI of the brain showed marked resolutions of basal ganglia hyperintensity (figures 4 and 5). NCS remained normal without evidence of OPIDP.

DISCUSSION

OP inhibits acetyl cholinesterase in synapses and red cell membrane and butyrylcholine esterase in plasma. Increased Ach at synapses of cholinergic neurons leads to profound excitotoxicity. It results in dysfunction of neurons due to over-activation of muscarinic acetylcholine receptors (mAChR) and disrupts the harmony between glutamatergic and GABA(γ -aminobutyric acid)ergic activity.² In addition to glutamatergic excitotoxicity, immunomodulatory effects in the brain may play a role in OP-induced CNS damage.⁵ The EPS in OP poisoning results due to imbalance between cholinergic and dopaminergic neurons in basal ganglia and substantia nigra.³ The basal ganglia is more vulnerable to toxin, metabolic abnormalities as well as to vascular insult because it is rich in mitochondria, vascular supply, neurotransmitters and chemical content compared with other areas of the brain.⁶ Similar to other environmental toxins,

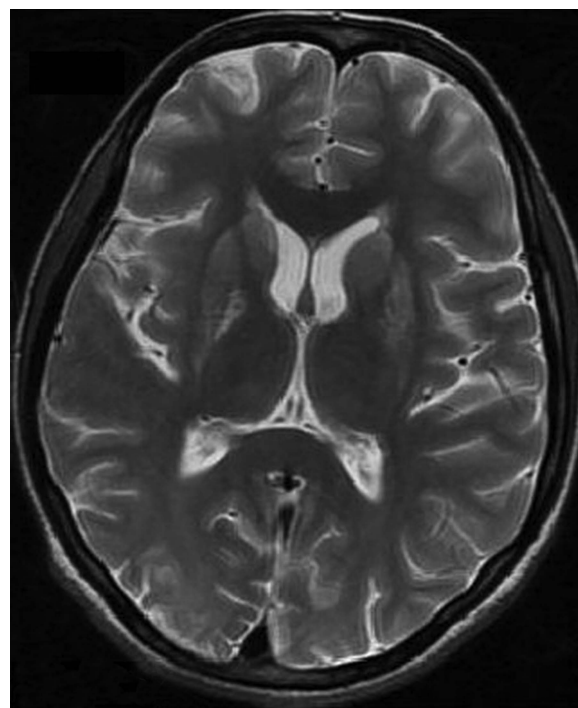


Figure 4 Follow-up (after 4 weeks) MRI of the brain with T2-weighted sequence showing a significant resolution of basal ganglia lesion.

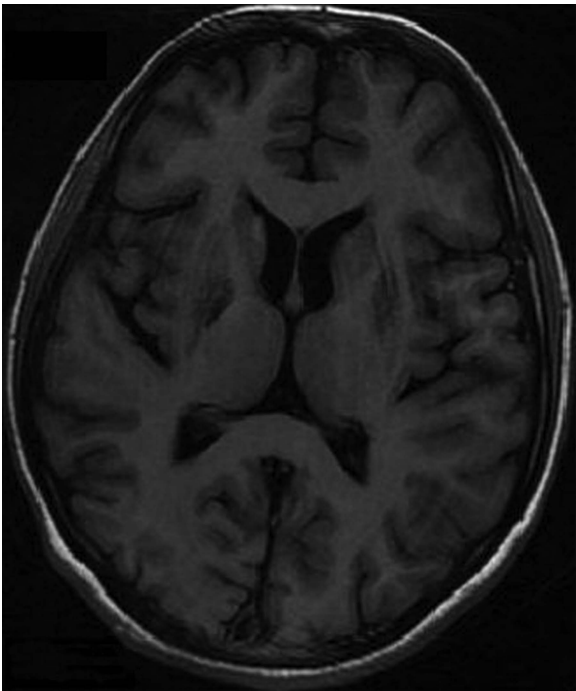


Figure 5 Follow-up (after 4 weeks) MRI with T1-weighted sequence showing a significant resolution of basal ganglia lesion.

OP may be responsible for early involvement of basal ganglia leading to EPS. Few published studies have demonstrated the reversible OP-induced secondary parkinsonism.^{7–9}

Bilateral symmetrical basal ganglia hyperintensity can be found in certain neurodegenerative or metabolic conditions such as Wilson's disease, Huntington's disease, methylmalonic acidemia, mitochondrial diseases, Leigh's disease, extrapontine myelinolysis, Creutzfeldt-Jakob disease and environmental toxins such as carbon monoxide, cyanide or methanol.⁶ However, proper clinical history and investigations narrow the diagnosis.

Goel *et al* demonstrated EPS in OP poisoning. They found symmetrical bilateral basal ganglia hyperintensity in T1, T2 and proton density images which persisted even in the follow-up imagings.¹⁰ In contrast, our case showed bilateral symmetrical basal ganglia hyperintensity in T2, FLAIR and diffusion-weighted sequences and hypointensity in T1-weighted image. The follow-up image showed a resolution of lesion along with clinical improvement suggesting definite clinoradiological correlations. However, the correlation between neuroimaging and severity of illness is controversial.

Learning points

- ▶ Apart from the delayed neurological manifestations of polyneuropathy and neuropsychiatric symptoms, extrapyramidal syndromes including parkinsonism and dystonia are the possible unusual clinical manifestations of organophosphate (OP) poisoning.
- ▶ Symmetrical bilateral basal ganglia hyperintensity is a rare neuroimaging finding.
- ▶ The imbalance between cholinergic and dopaminergic neurons in basal ganglia and substantia nigra might be responsible for the extrapyramidal symptoms in OP poisoning.
- ▶ Neuroimaging has a controversial role in the prognostication of OP poisoning.

Contributors AKP participated in the conception, design and interpretation of data; drafting the article and revising it critically for important intellectual content; and in the final approval of the version published. KB and LB participated in acquisition of the data or analysis; drafting the article and revising it critically for important intellectual content; and in the final approval of the version published.

Competing interests None.

Patient consent Obtained.

Provenance and peer review Not commissioned; externally peer reviewed.

REFERENCES

- 1 Jeyaratnam J. Acute pesticide poisoning: a major global health problem. *World Health Stat Q* 1990;43:139–44.
- 2 Chen Y. Organophosphate-induced brain damage: mechanisms, neuropsychiatric and neurological consequences, and potential therapeutic strategies. *Neurotoxicology* 2012;33:391–400.
- 3 Hsieh BH, Deng JF, Ger J, *et al*. Acetylcholine esterase inhibition and extra pyramidal syndrome: a review of neurotoxicity of organophosphate. *Neurotoxicology* 2001;22:423–7.
- 4 Eddleston M, Buckley NA, Eyer P, *et al*. Management of acute organophosphorus pesticide poisoning. *Lancet* 2008;371:597–607.
- 5 Eisenkraft A, Falk A, Finkelstein A. The role of glutamate and the immune system in organophosphate-induced CNS damage. *Neurotox Res* 2013;24:265–79.
- 6 Hegde AN, Mohan S, Lath N, *et al*. Differential diagnosis for bilateral abnormalities of the basal ganglia and thalamus. *Radiographics* 2011;31:5–30.
- 7 Muller-Vahl KR, Kolbe H, Dengler R. Transient severe parkinsonism after acute organophosphate poisoning (letter). *J Neurol Neurosurg Psychiatry* 1999;66:253–4.
- 8 Davis KL, Yesavage JA, Berger PA. Single case study: possible organophosphate-induced Parkinsonism. *J Nerv Ment Dis* 1978;166:222–5.
- 9 Joubert J, Joubert PH, van der Spuy M, *et al*. Acute organophosphate poisoning presenting with choreo-athetosis. *J Toxicol Clin Toxicol* 1984;22:187–91.
- 10 Goel D, Singhal A, Srivastav KR, *et al*. Magnetic resonance imaging changes in a case after acute organophosphate poisoning. *Neurol India* 2006;54:207–9.

Copyright 2014 BMJ Publishing Group. All rights reserved. For permission to reuse any of this content visit <http://group.bmj.com/group/rights-licensing/permissions>.
BMJ Case Report Fellows may re-use this article for personal use and teaching without any further permission.

Become a Fellow of BMJ Case Reports today and you can:

- ▶ Submit as many cases as you like
- ▶ Enjoy fast sympathetic peer review and rapid publication of accepted articles
- ▶ Access all the published articles
- ▶ Re-use any of the published material for personal use and teaching without further permission

For information on Institutional Fellowships contact consortiasales@bmjgroup.com

Visit casereports.bmj.com for more articles like this and to become a Fellow