

CASE REPORT

Simultaneous occurrence of internal capsule infarct and cerebellar haemorrhage in a patient with hemiplegia

Nikhil Pande,¹ Ganapathiraman Vivek,² Manjunath Hande,¹ Vasudeva Acharya¹

¹Department of Medicine, Kasturba Medical College, Manipal University, Manipal, Karnataka, India

²Department of Cardiology, Kasturba Medical College, Manipal University, Manipal, Karnataka, India

Correspondence to

Dr Ganapathiraman Vivek, vivekgraman@gmail.com, vivekgraman@yahoo.co.in

SUMMARY

A 68-year-old woman with hypertension with no history of cerebrovascular events presented with a left-sided hemiplegia which had developed acutely 2 days ago. She was not on maintenance therapy with antiplatelets or anticoagulants. A CT scan showed acute ischaemic infarction of the right internal capsule and cerebellar haemorrhage. Cardiac evaluation was normal. Doppler ultrasonography of the extracranial carotid and vertebral arteries showed diffuse arteriosclerotic changes, but did not reveal any haemodynamic occlusion. The simultaneous development of dual strokes was considered to be an extension of the same arteriosclerotic process to the intracranial carotid and basilar arteries.

BACKGROUND

Stroke is the second leading cause of death worldwide, and the leading cause of acquired disability in adults in most of the regions.¹ Primary brain haemorrhage and lacunar infarction share a common pathogenetic basis of arteriosclerotic damage to small perforating arteries. The two types of stroke, however, hardly ever occur simultaneously. We describe a hypertensive patient with poor compliance to antihypertensive therapy, who developed primary haemorrhage and infarction in different regions of the brain simultaneously. The unusual presentation of concurrent ischaemic and haemorrhagic strokes and the consequent diagnostic and therapeutic challenges encountered are described in this report.

CASE PRESENTATION

A 68-year-old woman with hypertension, on irregular medication, presented with a sudden onset of giddiness and a fall. She sustained an abrasion over her left leg as a result but did not suffer any head injury. She also vomited twice, and her relatives noticed that she was completely unable to move the left side of her body. She received supportive care at a local health care facility and was referred to our hospital when there was no improvement in her symptoms. She denied any history of substance abuse. There was no history suggestive of cerebrovascular events in the past. Family history was unremarkable. She had not received any form of antiplatelet or anticoagulant therapy in the past, including at the local facility where she was seen immediately after the onset of stroke.

On arrival at our hospital 2 days after the onset of symptoms, the patient appeared mildly dehydrated but was haemodynamically stable. She could not tell her name, but was responding appropriately to verbal and written commands. Neurological examination confirmed dense hemiplegia of the left upper and lower limbs with left-sided upper motor neuron facial palsy. The cardiovascular examination was normal.

INVESTIGATIONS

Cranial CT performed at admission showed a well-defined hyperdensity in the cerebellar vermis consistent with intraparenchymal haemorrhage (figures 1 and 2). An intra-axial hypodense area was also seen within the genu of the right internal capsule suggestive of an acute infarct. Small vessel ischaemic changes were noted involving the periventricular white matter. The brain stem was normal in attenuation.

Doppler ultrasonography of the extracranial carotid and vertebral arteries showed arteriosclerotic lesions but no haemodynamically significant occlusion. Routine laboratory tests revealed random blood glucose of 162 mg/dL; however, subsequent values and glycated haemoglobin were normal. Complete blood counts, erythrocyte

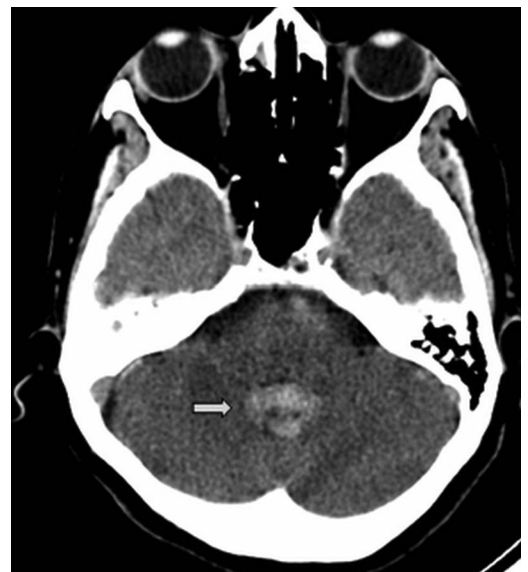

Figure 1 Cranial CT scan showing a well-defined hyperdensity in vermis (arrow), suggestive of intraparenchymal haemorrhage.



CrossMark

To cite: Pande N, Vivek G, Hande M, et al. *BMJ Case Rep* Published online: [please include Day Month Year] doi:10.1136/bcr-2013-201489

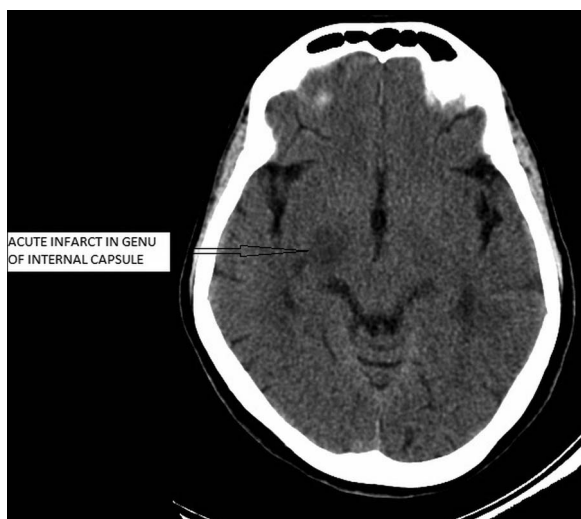


Figure 2 Cranial CT scans showing a well-defined intra-axial hypodensity in genu of right internal capsule (arrow), suggestive of infarct.

sedimentation rate and liver and renal function tests were within normal limits. Prothrombin time and activated partial thromboplastin time were also normal.

MRI with diffusion weighted images (DWI) and gradient echo sequences was planned but could not be performed in view of intense claustrophobia.

Serum troponin-T level was raised (0.162 ng/mL). However, electrocardiography showed normal sinus rhythm with no evidence of ischaemic heart disease. Transthoracic echocardiography ruled out the presence of any wall motion abnormalities, vegetations or thrombi.

DIFFERENTIAL DIAGNOSIS

Simultaneous right capsular infarct and cerebellar vermian haemorrhage, secondary to arteriosclerotic small vessel disease, on a background of poorly controlled hypertension.

TREATMENT

Multiple antihypertensive drugs were employed to maintain a blood pressure below 140/90 mm Hg. Antiplatelet agents such as aspirin were deliberately avoided to prevent enlargement of the haematoma. Intravenous furosemide and mannitol were administered as an anti-oedema measure, and were subsequently tapered after repeated CT imaging showed no expansion of the haematoma. Neurosurgical evacuation of the haematoma was deferred in favour of intensive monitoring for signs of neurological deterioration.

OUTCOME AND FOLLOW-UP

There was no further deterioration in the patient's condition. At the time of discharge 1 week later, her speech had improved significantly, and slight improvement in the power of her left upper and lower limbs was noted. The patient was also impressed with the need for compliance to anti-hypertensive therapy to prevent stroke recurrence in the future.

DISCUSSION

Stroke is a heterogeneous entity comprising several distinct forms of cerebrovascular disease, and distinguishing between haemorrhagic and ischaemic stroke is critical in terms of acute management, prognosis and secondary prevention. Although

various scoring systems have been devised to help differentiate between infarction and haemorrhage, none provide sufficient accuracy to guide treatment.² The only reliable method of differentiating is early cerebral imaging. In resource-limited settings, this is best performed by CT as MRI is expensive and may not be routinely available. Lumbar puncture may be useful in confirming subarachnoid haemorrhage if imaging is equivocal, but it has no place in differentiating ischaemic and haemorrhagic stroke.

This case was presented with many unique diagnostic and therapeutic challenges in view of the fact that ischaemic and haemorrhagic strokes occurred simultaneously. The vascular territories of the two events were distinct ruling out the possibility of partial haemorrhagic transformation of a pre-existing infarct. Clinically, the patient presented principally with manifestations of an internal capsular infarct and only subtle cerebellar signs such as dysarthria, giddiness, nausea and vomiting. Cerebellar haemorrhages are notorious for sudden neurological worsening, and the size of haematoma (>3 cm), the presence of hydrocephalus, visible brain stem distortion and systolic blood pressure greater than 200 mm Hg predict poor outcome.³ Fortunately, our patient displayed none of these features and did not suffer any neurological worsening.

The challenge posed in the treatment of such a patient stems from the fact that antiplatelet agents cannot be administered for ischaemic infarct due to the risk of haematoma expansion. Concurrently, aggressive lowering of blood pressure to prevent continued bleeding runs the risk of infarction of the ischaemic penumbra. Imaging in such patients is best performed with MRI with DWI or gradient echo sequences but cost and non-availability are major limitations along with claustrophobia in MRI machine which makes CT scan a much more practical investigation. A CT scan with density measurement can also provide a fairly accurate time interval during which the event occurred.

Such patients are also at an increased risk of contracting deep vein thrombosis and require compression pneumatic devices and active physiotherapy since anticoagulation is contraindicated.

There exist only a few case reports in the literature of dual strokes occurring simultaneously. Toyoda *et al*⁴ reported this occurrence in a patient on chronic haemodialysis who received unfractionated heparin. Balci *et al*⁵ reported a similar case in a patient with uncontrolled hypertension with atrial fibrillation who did not survive the episode.

Learning points

- ▶ Possibility of concurrent haemorrhagic stroke should be considered before antithrombotic treatment is initiated for ischaemic stroke.
- ▶ Repeated imaging is necessary for cerebellar haemorrhage as there is a risk of hydrocephalus or brainstem compression.
- ▶ Treatment in a patient with concurrent infarction and haemorrhage must be tailored on an individual basis.

Contributors NP, VA, GV and MH were involved in the concept, design, definition of intellectual content and literature search. In addition, NP and GV were involved in data acquisition. NP, VA, GV and MH were, in addition, involved in the preparation, editing and review of the manuscript. VA and MH were involved in clinical care of the patient.

Competing interests None.

Patient consent Obtained.

Provenance and peer review Not commissioned; externally peer reviewed.

REFERENCES

- 1 Feigin VL. Stroke in developing countries: can the epidemic be stopped and outcomes improved? *Lancet Neurol* 2007;6:94–7.
- 2 Weir CJ, Murray GD, Adams FG, *et al.* Poor accuracy of stroke scoring systems for differential clinical diagnosis of intracranial haemorrhage and infarction. *Lancet* 1994;344:999–1002.
- 3 StLouis EK, Wijdicks EF, Li H, *et al.* Predictors of poor outcome in patients with a spontaneous cerebellar hematoma. *Can J Neurol Sci* 2000;27:32–6.
- 4 Toyoda K, Kumai Y, Fujii K, *et al.* Simultaneous onset of haemorrhagic and ischaemic strokes in a haemodialysis patient. *J Neurol Neurosurg Psychiatry* 2002;72:673–4.
- 5 Balci K, Utku U, Asil T, *et al.* Simultaneous onset of hemorrhagic and ischemic strokes. *Neurologist* 2007;13:148–9.

Copyright 2014 BMJ Publishing Group. All rights reserved. For permission to reuse any of this content visit <http://group.bmj.com/group/rights-licensing/permissions>.

BMJ Case Report Fellows may re-use this article for personal use and teaching without any further permission.

Become a Fellow of BMJ Case Reports today and you can:

- Submit as many cases as you like
- Enjoy fast sympathetic peer review and rapid publication of accepted articles
- Access all the published articles
- Re-use any of the published material for personal use and teaching without further permission

For information on Institutional Fellowships contact consortiasales@bmjgroup.com

Visit casereports.bmj.com for more articles like this and to become a Fellow