



Case Report

Vaginal cesarean section for second-trimester therapeutic abortion

Shinya Karakida^a, Toshio Sasaki^a, Kentaro Kai^{a,b,*}, Kei Harada^c, Shinichiro Yoshimura^d,
Michiharu Kono^a, Hisashi Narahara^b

^aDepartment of Obstetrics and Gynecology, Kenwakai Otemachi Hospital, Fukuoka 803-0814, Japan

^bDepartment of Obstetrics and Gynecology, Oita University Faculty of Medicine, Oita 879-5593, Japan

^cDepartment of Neurosurgery, Kenwakai Otemachi Hospital, Fukuoka 803-0814, Japan

^dDepartment of Anesthesiology, Kenwakai Otemachi Hospital, Fukuoka 803-0814, Japan

Accepted 4 February 2013

Abstract

Objective: Pregnancy does not increase the risk of bleeding from a brain arteriovenous malformation (AVM), but once an AVM has bled during pregnancy, the rate of rebleeding during the same pregnancy is high. Therefore, termination of the pregnancy is an option for patients in whom the AVM is located in an eloquent area. We report a woman with an intracerebral hemorrhage from a brain AVM who underwent a second-trimester therapeutic abortion by vaginal cesarean section.

Case report: A 30-year-old multiparous woman visited our emergency department at 17 weeks of gestation complaining of a sudden-onset headache with vomiting. She had no history of headaches or seizures. Based on the clinical presentation, computed tomography and magnetic resonance imaging, we made a clinical diagnosis of Spetzler–Martin Grade III AVM. Before undergoing stereotactic radiosurgery as a primary treatment, we advised her to terminate her pregnancy and performed a vaginal cesarean section at 19 weeks of gestation. Two months later, the patient underwent gamma knife surgery for the underlying lesion, without complications. Follow-up angiography and magnetic resonance imaging showed that the AVM had disappeared completely.

Conclusion: Although its indications are limited, vaginal cesarean section is a useful option for terminating a pregnancy that compensates for the disadvantages of dilatation and curettage and systemic abortifacients.

Copyright © 2013, Taiwan Association of Obstetrics & Gynecology. Published by Elsevier Taiwan LLC. All rights reserved.

Keywords: arteriovenous malformation; pregnancy termination; stereotactic radiosurgery; vaginal cesarean section; vaginal hysterotomy

Introduction

Intracerebral hemorrhage (ICH) during pregnancy from a brain arteriovenous malformation (AVM) is rare, but ICH has a high maternal mortality rate and it predominates as a non-obstetric cause of maternal mortality during pregnancy [1]. Pregnancy in itself does not increase the risk of bleeding from a brain AVM [2], but once an AVM has bled during pregnancy, the rate of rebleeding during the same pregnancy has been reported to be 27% [3]. In cases in which the brain AVM is

located in an eloquent area, the high risk of morbidity justifies termination of the pregnancy, because any rebleeding is highly likely to cause severe neurological problems. However, a second-trimester termination of pregnancy for a woman with an acute cerebrovascular disorder poses a great challenge for clinicians. We present here the case of a woman with ICH from a brain AVM who underwent a second-trimester therapeutic abortion by vaginal cesarean section.

Case report

A 30-year-old, gravida 1 para 1, right-handed woman visited our emergency department at 17 weeks of gestation in June 2009 complaining of a sudden-onset headache with vomiting. She had no history of headache or seizures. One

* Corresponding author. Department of Obstetrics and Gynecology, Oita University Faculty of Medicine, 1-1 Idaigaoka, Hasama-machi, Yufu, Oita 879-5593, Japan.

E-mail address: kenta9sp@oita-u.ac.jp (K. Kai).

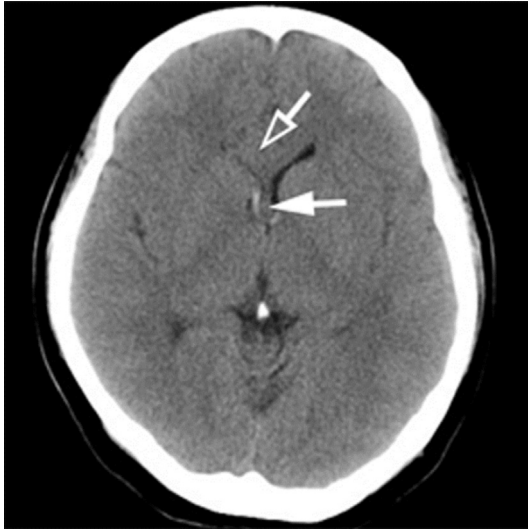

Fig. 1. A CT scan at admission (17 weeks of gestation) showed a small hemorrhage along the margin of the right lateral ventricle (solid arrow) and a space-occupying lesion displacing the right frontal horn of the lateral ventricle posteriorly (open arrow).

year earlier, she had a full-term pregnancy and uneventful vaginal delivery. The initial neurological examination showed a consciousness level of E4V5M6 (Glasgow Coma Scale) with both pupils equal in size and no focal neurological deficit. Her vital signs were: blood pressure 128/78 mmHg, pulse 96 beats/min, body temperature 37.1 °C, and percutaneous oxygen saturation (SpO₂) 98% (room air). Computed tomography revealed a right small ICH with rupture into the right lateral and third cerebral ventricles and an unknown space-occupying lesion displacing the right frontal horn of the lateral ventricle posteriorly (Fig. 1). Brain magnetic resonance imaging (MRI) revealed an AVM encroaching on the right cingulate gyrus and corpus callosum (Fig. 2A). Based on the size of the malformation (2.5 cm), its location in an eloquent area, and the presence of deep venous drainage delineated as a flow void by magnetic resonance angiography, we made a clinical diagnosis of a Spetzler–Martin Grade III AVM.

The deep brain location of the AVM made it impossible to remove surgically and its small size required no adjunct endovascular embolization, therefore, we selected stereotactic radiosurgery (gamma knife surgery). The initial hemorrhage in the eloquent area occurred at 17 weeks of gestation, which did not exceed the limit of fetal viability, suggesting that the

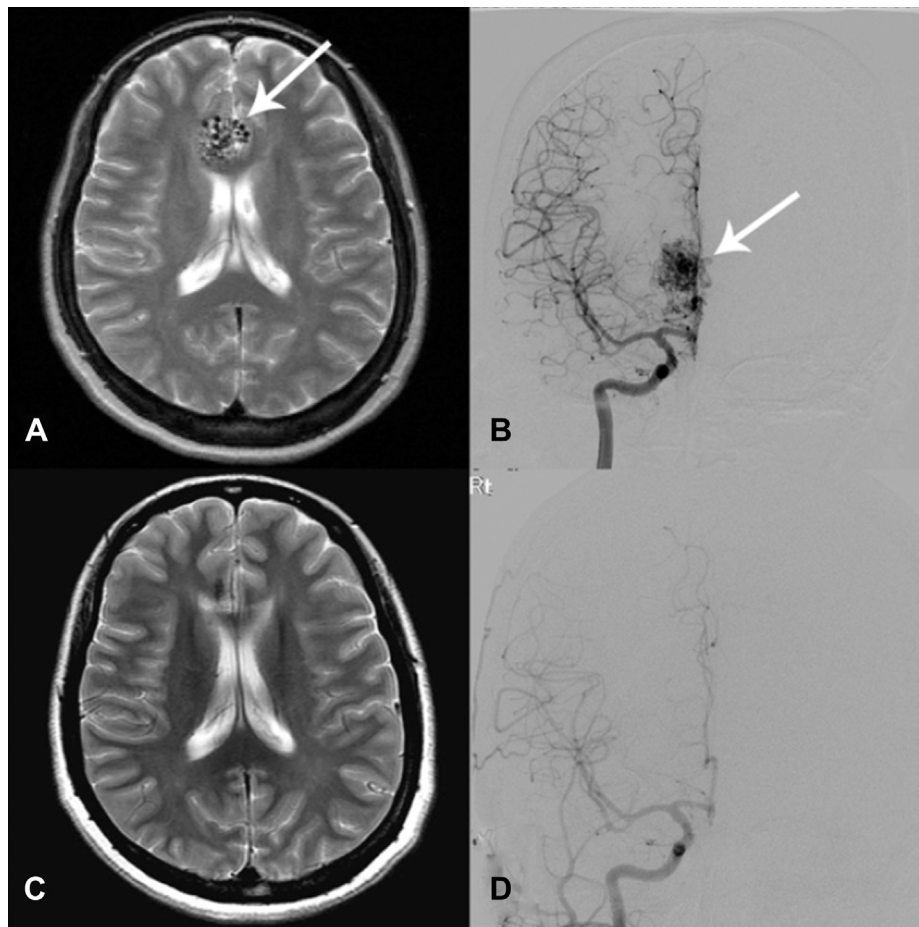


Fig. 2. (A) Magnetic resonance imaging showed an arteriovenous malformation (AVM) encroaching on the right cingulate gyrus and corpus callosum. (B) The AVM was supplied by the branches of the right anterior cerebral artery and drained into the superior and inferior sagittal sinuses. Follow-up magnetic resonance imaging (C) and angiography (D) at 2 years after radiosurgery showed complete disappearance of the AVM.

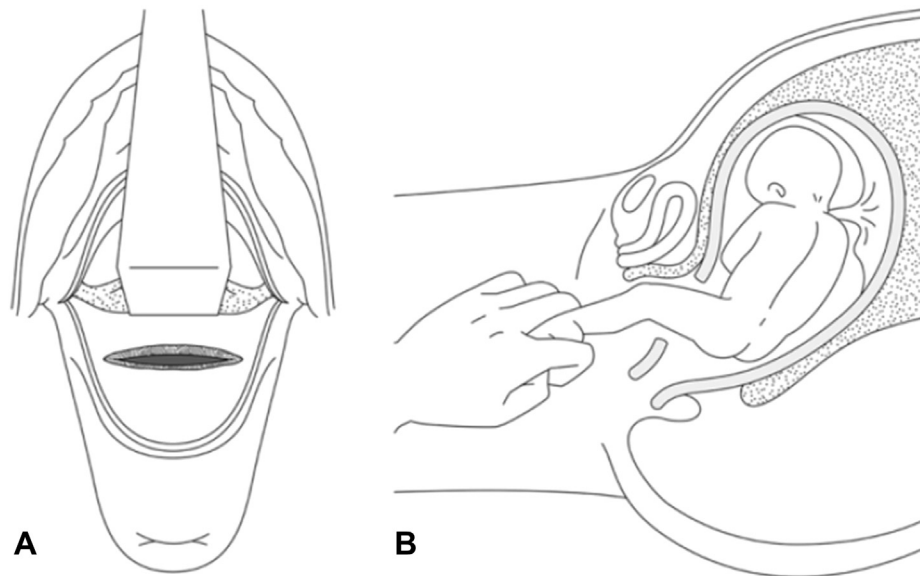


Fig. 3. (A) Scheme showing the bladder and vesicouterine serosal reflection elevated using a retractor and the transverse low segment incision just above the internal cervical os. (B) Scheme showing how the fetus was delivered via an incomplete breech presentation.

pregnancy could lead to subsequent rebleeding, which could cause severe neurological deficits for the patient. Therefore, we advised a therapeutic abortion based on neurological principles.

In choosing a technique for pregnancy termination, we regarded control of the patient's blood pressure as one of the top priorities. Therefore, it was necessary that the patient avoid the stress of labor. A technique requiring the least amount of time, with a minimum of pain and bleeding was desired. The patient did not agree with destruction of the fetus by dilatation and evacuation, therefore, we performed a vaginal cesarean section at 19 weeks of gestation. A targeted ultrasound examination before the operation demonstrated a singleton fetus in cephalic presentation. The placenta was anterior and the amniotic fluid index was 10 cm.

The patient was premedicated with intravenous (i.v.) midazolam at 0.05 mg/kg. Anesthesia induction was achieved with propofol at 0.8 mg/kg in combination with fentanyl at 5 µg/kg i.v. The laryngeal mask airway clearance was facilitated by treatment with rocuronium bromide at 1 mg/kg i.v. Anesthesia was maintained with 1% sevoflurane in 80:20 air:O₂ and infusions of remifentanyl at 0.25 µg/kg/min. Ephedrine at 4 mg/dose i.v. and phenylephrine at 0.1 mg/dose i.v. were used to reduce any hypotensive response during surgery. The patient was ventilated mechanically to maintain the lower limit of normal end-expiratory CO₂ (36–37 mmHg).

The anterior and posterior lips of the cervix were grasped with a double-toothed tenaculum. A transverse incision was made in the mucosa overlying the anterior cervix. The bladder and vesicouterine serosal reflection were pushed cephalad and a transverse incision of the cervix was made carefully to avoid rupturing the membrane. The incision was extended laterally using the fingers (Fig. 3A). After rupture of the membrane with Kocher forceps, the surgeon performed an internal cephalic removal, preventing leakage of amniotic fluid. Grasping

one fetal foot with the hand, the surgeon pulled the fetus out from the uterine cavity in an incomplete breech presentation (Fig. 3B), aided by modest transabdominal fundal pressure. After removal of the fetus and placenta and curettage of the uterine cavity, the cervix and the vaginal mucosa were sutured separately. The operation took 29 minutes and resulted in 350 mL bleeding.

On postoperative Day 2, the patients complained of a mild headache despite the control of postoperative pain and blood pressure in an intensive care unit. Computed tomography revealed a small amount of rebleeding in the right lateral ventricle. Conservative management with tranexamic acid and carbazochrome sodium sulfonate completely improved the patient's condition. On postoperative Day 19, a cerebral angiogram showed a right cingulate gyrus and corpus callosum AVM, measuring 2.0 cm in diameter, supplied by the branches of the right anterior cerebral artery and draining into the superior and inferior sagittal sinuses (Fig. 2B). There were no associated arterial aneurysms.

Two months later, the patient underwent gamma knife surgery for the underlying lesion, without complication. A standard prescription dose of 21 Gy was delivered to the 55% isodose curve with a maximum point dose of 38.4 Gy. The target volume was 2.7 cm³. A follow-up angiogram and MRI showed that the AVM in the right anterior cerebral artery branches had disappeared completely (Fig. 2C and D). During this period, there were no complications from the radiation surgery. We surmise that waiting 3 years after the radiation surgery without any complication will allow the patient to conceive another child safely, if desired.

Discussion

Vaginal cesarean section, defined as an extraction of the fetus via a vaginal hysterotomy, was commonly performed in

Sweden in the late 1940s for legal abortions. In 1939, Fuchs first described this method with a transverse low segment incision just above the internal cervical os [4]. Vaginal hysterotomy was subsequently abandoned as an abortion technique because of the ready availability of less-invasive procedures. To the best of our knowledge, in 1980 Fianu et al were the last to report on postabortum endometriosis with a vaginal cesarean section [5].

The present case allows a reevaluation of the vaginal cesarean section method from three aspects. First, this procedure requires less time than methods such as the use of systemic abortifacients. Second, the patient does not experience labor, which is beneficial to patients with a serious central nervous system complication such as an AVM. Finally, the fetus is delivered intact, which can be important if the termination is performed because of a fetal abnormality. Further, with skill in vaginal operative techniques, this method can be used in any gynecological department. Although its indications are

limited, vaginal cesarean section is a useful option that compensates for the disadvantages of dilatation and evacuation and the administration of systemic abortifacients.

References

- [1] Dias MS, Sekhar LN. Intracranial hemorrhage from aneurysms and arteriovenous malformations during pregnancy and the puerperium. *Neurosurgery* 1990;27:855–66.
- [2] Horton JC, Chambers WA, Lyons SL, Adams RD, Kjellberg RN. Pregnancy and the risk of hemorrhage from cerebral arteriovenous malformations. *Neurosurgery* 1990;27:867–72.
- [3] Sadasivan B, Malik GM, Lee C, Ausman JI. Vascular malformations and pregnancy. *Surg Neurol* 1990;33:305–13.
- [4] Schariot G, Wolter F. [The vaginal transverse low segment hysterotomy for second trimester therapeutic abortion (author's translation)]. *Geburtshilfe Frauenheilkd* 1976;36:687–90.
- [5] Fianu S, Ingelman-Sundberg A, Nasiell K, Rosen J, Vaclavinkova V. Surgical treatment of post abortum endometriosis of the bladder and postoperative bladder function. *Scand J Urol Nephrol* 1980;14:151–5.