

Global Aphasia without Hemiparesis Caused by a Dural Arteriovenous Fistula

Jumpei Togawa¹, Takekazu Ohi² and Satoru Kawarazaki³

Abstract

A 61-year-old Japanese woman with chronic renal failure suddenly became silent at the end of hemodialysis. On a neurological examination, she was unable to respond to one-step commands, state the names of objects, repeat single words, read words aloud or write her name. Because she exhibited no paralysis of the extremities, we diagnosed her as having global aphasia without hemiparesis (GAWH). Cerebral angiography showed a dural arteriovenous fistula (AVF) in the left isolated transverse sinus with leptomeningeal venous drainage (Borden type 3, Lalwani grade 4). This case highlights dural AVF as an etiology of GAWH.

Key words: global aphasia without hemiparesis, dural arteriovenous fistula, venous infarction

(Intern Med 53: 135-138, 2014)

(DOI: 10.2169/internalmedicine.53.1072)

Introduction

Global aphasia is usually accompanied by weakness of the right side of the face and right hemiplegia in right-handed patients (1). Global aphasia without hemiparesis (GAWH) is a rare syndrome in which these symptoms are not observed. The pathogenic mechanisms underlying the development of GAWH are still not fully understood, and it has been previously reported that cerebral infarction, subarachnoid hemorrhage and brain tumors can cause GAWH (2-9).

Dural arteriovenous fistulas (AVFs) are abnormal vascular connections located within the dura matter that can result in life-threatening brain edema, hemorrhage and venous infarction (10-13). Dural AVFs with retrograde leptomeningeal venous drainage are regarded as high-risk lesions having the potential to cause hemorrhage and serious neurological deficits (10-13).

We herein report a case of GAWH caused by a dural AVF. To our knowledge, this is the first clinical report of GAWH caused by a dural AVF.

Case Report

A 61-year-old Japanese woman was transferred to our hospital after suddenly becoming silent at the end of hemodialysis.

She had a medical history of hypertension, diabetes mellitus, hypothyroidism, chronic renal failure and early Alzheimer's disease and exhibited only a mild disturbance of memory with no problems engaging in ordinary conversation. She had no history of either drinking or smoking.

On a neurological examination, the patient's spontaneous speech was markedly impaired; she said only the Japanese word for "ouch!" when her skin was pinched and spoke no other words spontaneously. She was unable to repeat single words, respond to one-step commands, read single words aloud or write single words or her name. She exhibited non-fluent aphasia without comprehension. Because she had no paralysis, we diagnosed her as having GAWH.

The patient's complete blood cell count and blood chemistry parameters were within the normal ranges, except for moderate anemia and renal failure. A lumbar puncture was performed, and the white blood cell count, protein level and glucose level were found to be normal. No Herpes simplex virus DNA was detected in the cerebrospinal fluid (CSF).

¹Department of Neurology, Otsu Red Cross Hospital, Japan, ²Department of Neurology, Kyoto Hakuikai Hospital, Japan and ³Department of Neurosurgery, National Hospital Organization Kyoto Medical Center, Japan

Received for publication May 28, 2013; Accepted for publication August 22, 2013

Correspondence to Dr. Jumpei Togawa, togawa-kyt@umin.org

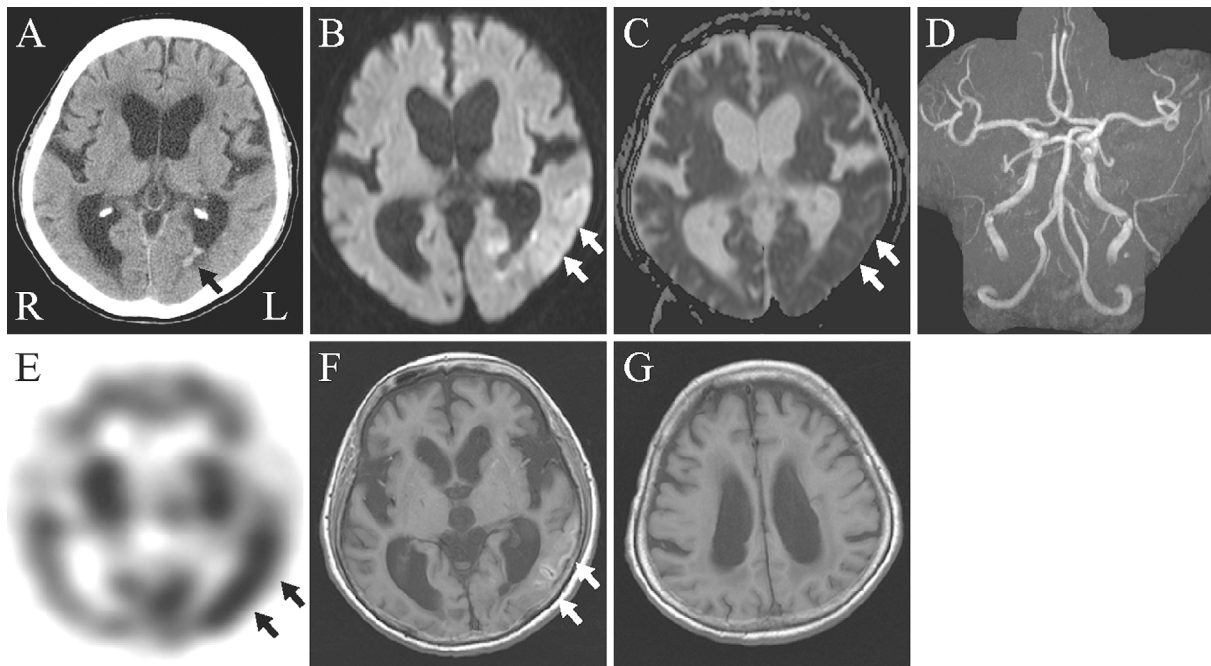


Figure 1. Head CT (A), brain MRI (B, C) and MRA (D) performed on admission, IMP-SPECT of the brain (E) performed two days after admission and brain MRI (F, G) performed three weeks after admission. A: Plain head CT performed on admission revealed a hemorrhage in the left lateral cerebral ventricle (arrow). B: DWI showed HISA in the left temporal lobe (arrows). C: The left temporal lobe exhibited iso or low intensity signals on ADC mapping (arrows). D: MRA showed intact cerebral arteries. E: IMP-SPECT performed two days after admission demonstrated hyperperfusion in the left temporal lobe (arrows). F: T1-weighted MRI performed three weeks after admission demonstrated laminar necrosis in the left temporal lobe (arrows). G: The precentral gyrus was spared.

Carotid artery ultrasonography and an echocardiogram and electrocardiogram revealed no abnormal findings. Electroencephalography showed no paroxysmal activity.

Head computed tomography (CT) disclosed a hemorrhage in the left lateral cerebral ventricle (Fig. 1A), and brain magnetic resonance imaging (MRI) demonstrated a high-intensity signal area (HISA) in the left temporal lobe on a diffusion-weighted image (DWI) (Fig. 1B). On apparent diffusion coefficient (ADC) mapping, the left temporal lobe exhibited iso or low signal intensity (Fig. 1C). MR angiography (MRA) showed intact cerebral arteries (Fig. 1D).

N-isopropyl-p-[123I]iodoamphetamine (IMP)-single photon emission computed tomography (SPECT) performed two days after admission demonstrated hyperperfusion in the left temporal lobe (Fig. 1E).

Cerebral angiography showed a dural AVF involving the left isolated transverse sinus fed by the left meningeal artery, posterior auricular artery and occipital artery with leptomeningeal venous drainage (Borden type 3, Lalwani grade 4) (Fig. 2). The internal carotid and vertebral arteries were intact bilaterally.

After admission, 10% glycerol (200 mL/day) was administered to prevent brain edema in addition to nicardipine (5 mg/h).

Three weeks after admission, the patient's symptoms were slightly improved. She was able to follow one-step com-

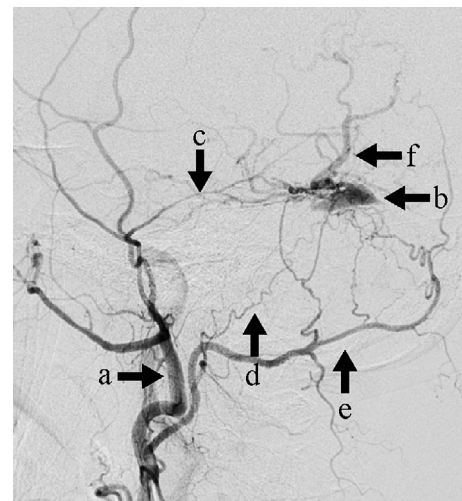


Figure 2. Cerebral angiography of the left external carotid artery. Lateral angiography of the left external carotid artery (a) showed a dural AVF involving the left isolated transverse sinus (b) fed by the left meningeal artery (c), posterior auricular artery (d) and occipital artery (e) with leptomeningeal venous drainage (f) (Borden type 3, Lalwani grade 4).

mands. Her spontaneous speech was still impaired; however, she was able to say to a nurse that she did not want any more food when she finished her dinner. She could some-

times repeat single words, such as “handkerchief,” but not “tangerine.” She could write simple words, but not her name. She read words incorrectly; for example, she said “apple” when she saw “tangerine” written on a paper. A follow-up MRI showed laminar necrosis in the left temporal lobe with sparing of the precentral gyrus (Fig. 1F, G).

She received intravenous embolization therapy six weeks after admission; however, the global aphasia persisted.

Discussion

Van Horn and Hawes reported three patients who developed GAWH in 1982, all of whom were diagnosed with an embolic cerebral infarction. The authors suggested that GAWH is a sign of embolic encephalopathy (3). In 1987, Legatt et al. reported six patients with GAWH, two of whom had an intracranial hematoma and subarachnoid hemorrhage. The authors commented that GAWH has multiple etiologies (4). Pai et al. reported four patients with GAWH in 2011, two of which had a cardioembolic source: one case was due to internal carotid artery occlusion and one case was of an undetermined cause (5). We herein report a patient with GAWH diagnosed as having a dural AVF on cerebral angiography. We speculate that arterial blood passed directly through to the venous side through the dural AVF, causing venous pressure elevation and finally resulting in venous infarction. The dural AVF exhibited retrograde leptomeningeal venous drainage and was classified as Borden type 3 and Lalwani grade 4; such lesions are at a high risk of causing intracranial hemorrhage or nonhemorrhagic neurological deficits (10-13). Brain IMP-SPECT showed hyperperfusion of the left temporal lobe, which is of interest because that area had exhibited hypoperfusion in cases of GAWH due to arterial infarction in a previous report (6). A SPECT study of patients with dural AVFs presenting with venous ischemia showed hypoperfusion in the lesions (14). Hyperperfusion in dural AVFs is rare. Kuroda et al. reported a case of a dural AVF presenting with postoperative hyperperfusion (15), and Yamada et al. noted that IMP uptake is increased in a rat model of venous hypertension (16). We speculate that IMP uptake was increased in our patient possibly because the first-pass extraction of IMP was decreased due to slow circulation resulting from venous congestion.

A diagnosis of arterial infarction was ruled out due to the absence of cerebral artery occlusion on MRA and cerebral angiography. Encephalitis was also ruled out because the CSF was normal.

Although early studies suggested that the development of GAWH requires two discrete lesions involving the anterior and posterior language areas (3, 7), later studies reported that a single lesion can cause GAWH (2, 5, 8). In our case, a single lesion located in the temporal lobe caused GAWH; this location resembled that observed in cluster 1 in Hanlon's study and case 8 in Bang's study (2, 5). Posterior lesions located in the temporal lobe may disrupt fluency and cause global aphasia in the absence of anterior involve-

ment (17). In addition, our patient had a history of early Alzheimer's disease; therefore, her verbal fluency may have been subclinically impaired before the event (18). Shindo et al. examined the underlying pathogenic mechanism of GAWH using transcortical magnetic stimulation and concluded that GAWH is caused by sparing of the decussated pyramidal tract (9). We speculate that a dural AVF involving an isolated transverse sinus caused laminar necrosis sparing the deep white matter including the pyramidal tract in our patient, so that the motor function was not involved.

Dural AVFs can cause GAWH, especially when they result in venous infarction in the temporal area of the dominant hemisphere. Physicians should consider dural AVFs as a potential cause of GAWH.

The authors state that they have no Conflict of Interest (COI).

References

- Damasio AR. Aphasia. *N Engl J Med* **326**: 531-539, 1992.
- Hanlon RE, Lux WE, Dromerick AW. Global aphasia without hemiparesis: language profiles and lesion distribution. *J Neurol Neurosurg Psychiatry* **66**: 365-369, 1999.
- Van Horn G, Hawes A. Global aphasia without hemiparesis: a sign of embolic encephalopathy. *Neurology* **32**: 403-406, 1982.
- Legatt AD, Rubin MJ, Kaplan LR, Heaton EB, Brust JC. Global aphasia without hemiparesis: multiple etiologies. *Neurology* **37**: 201-205, 1987.
- Pai AR, Krishnan G, Prashanth S, Rao S. Global aphasia without hemiparesis: A case series. *Ann Indian Acad Neurol* **14**: 185-188, 2011.
- Bang OY, Heo KG, Kwak Y, Lee PH, Joo IS, Huh K. Global aphasia without hemiparesis: lesion analysis and its mechanism in 11 Korean patients. *J Neurol Sci* **217**: 101-106, 2004.
- Tranel D, Biller J, Damasio H, Adams HP Jr, Cornell SH. Global aphasia without hemiparesis. *Arch Neurol* **44**: 304-308, 1987.
- Deleval J, Leonard A, Mavroudikis N, Rodesch G. Global aphasia without hemiparesis following prerolandic infarction. *Neurology* **39**: 1532-1535, 1989.
- Shindo A, Satoh M, Naito Y, et al. Global aphasia without hemiparesis: the underlying mechanism examined by transcranial magnetic stimulation. *Neurologist* **19**: 11-14, 2013.
- Borden JA, Wu JK, Shucart WA. A proposed classification for spinal and cranial dural arteriovenous fistulous malformations and implications for treatment. *J Neurosurg* **82**: 166-179, 1995.
- Lalwani AK, Dowd CF, Halbach VV. Grading venous restrictive disease in patients with dural arteriovenous fistulas of the transverse/sigmoid sinus. *J Neurosurg* **79**: 11-15, 1993.
- Davies MA, TerBrugge K, Willinsky R, Coyne T, Saleh J, Wallace MC. The validity of classification for the clinical presentation of intracranial dural arteriovenous fistulas. *J Neurosurg* **85**: 830-837, 1996.
- van Dijk JM, terBrugge KG, Willinsky RA, Wallace MC. Clinical course of cranial dural arteriovenous fistulas with long-term persistent cortical venous reflux. *Stroke* **33**: 1233-1236, 2002.
- Kawaguchi T, Kawano T, Kaneko Y, Ooasa T, Tsutsumi M, Ogasawara S. rCBF study with 123I-IMP SPECT of dural arteriovenous fistula. *No To Shinkei (Brain and Nerve)* **52**: 991-996, 2000 (in Japanese, Abstract in English).
- Kuroda S, Ushikoshi S, Houkin K, Saito H, Kikuchi Y, Abe H. Postoperative hyperperfusion in dural arteriovenous fistula associated with venous ischemia: case report. *Surg Neurol* **49**: 406-411, 1998.

- 16.** Yamada M, Yuzawa I, Fujii K. Iodoamphetamine (IMP) uptake in the brain is increased after experimental cerebral venous hypertension in the rat. *Acta Neurochir Suppl* **86**: 209-212, 2003.
- 17.** Vignolo LA, Boccardi E, Caverni L. Unexpected CT-scan findings in global aphasia. *Cortex* **22**: 55-69, 1986.
- 18.** Greene JD, Patterson K, Xuereb J, Hodges JR. Alzheimer disease and nonfluent progressive aphasia. *Arch Neurol* **53**: 1072-1078, 1996.

© 2014 The Japanese Society of Internal Medicine
<http://www.naika.or.jp/imonline/index.html>