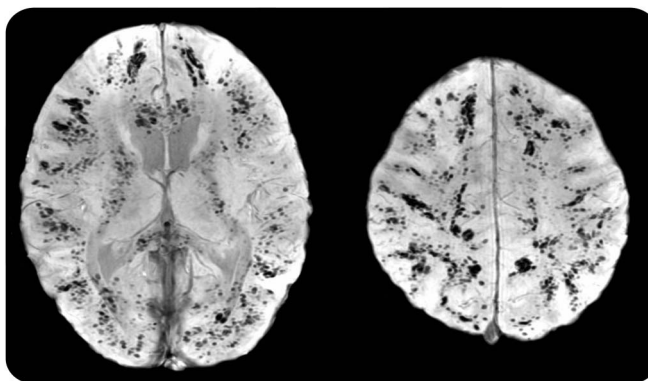


# Diffuse cerebral petechial hemorrhage in an 8-year-old girl with MRSA pneumonia and sepsis

**Figure** Susceptibility-weighted MRI of cerebral hemispheres



Innumerable discrete petechial hemorrhages throughout the cerebral hemispheres demonstrated on axial susceptibility-weighted MRI. The majority of the lesions are located at the gray-white interface.

An 8-year-old girl in septic shock due to necrotizing methicillin-resistant *Staphylococcus aureus* (MRSA) pneumonia developed signs of end-organ damage, new right hemiplegia, and left gaze preference. Susceptibility-weighted MRI demonstrated extensive multifocal petechial hemorrhage preferentially at the gray-white matter interface due to septic microemboli (figure). Mechanisms of hemorrhage include small-vessel occlusion leading to mycotic aneurysm formation with rupture or pyogenic arteritis without aneurysm formation.<sup>1</sup> Intracranial hemorrhage associated with metastatic staphylococcal infections is rarely described<sup>2</sup> and is especially noteworthy with diffuse cerebral petechial hemorrhage in the setting of metastatic MRSA.

*Mitchel T. Williams, MD, Huiyan Jiang, MD*

From the Department of Neurology, Children's Hospital of Michigan, Wayne State University, Detroit.

*Author contributions:* M. Williams: study concept and design, acquisition and interpretation of data, writing of draft manuscript. H. Jiang: discussion of case and revision of manuscript.

*Study funding:* No targeted funding reported.

*Disclosure:* The authors report no disclosures relevant to the manuscript. Go to [Neurology.org](http://Neurology.org) for full disclosures.

*Correspondence to Dr. Williams:* [mitchellwilliams8@gmail.com](mailto:mitchellwilliams8@gmail.com)

1. Masuda J, Yutani C, Waki R, Ogata J, Kuriyama Y, Yamaguchi T. Histopathological analysis of the mechanisms of intracranial hemorrhage complicating infective endocarditis. *Stroke* 1992;23:843–850.
2. Pniitt AA, Rubin RH, Karchmer AW, Duncan GW. Neurologic complications of bacterial endocarditis. *Medicine* 1978;57:329–343.