

Cardiac troponin T elevation associated with transient global amnesia: another differential diagnosis of ‘troponosis’

European Heart Journal: Acute Cardiovascular Care
1–4

© The European Society of Cardiology 2014

Reprints and permissions:

sagepub.co.uk/journalsPermissions.nav

DOI: 10.1177/2048872613519965

acc.sagepub.com

Mikko Jalanko, Fredrik Forsström and Johan Lassus

Abstract

Elevated cardiac troponin (cTn) levels can be detected in a variety of diseases with or without signs of myocardial ischaemia. Acute neurological disorders such as subarachnoid haemorrhage, stroke, transient ischaemic attack, epileptic seizures, and traumatic head injury can cause cTn elevation with and without myocardial wall motion abnormalities. We report a case of transient global amnesia with elevation and dynamic rise of highly sensitive troponin T (hsTnT) without clinical symptoms or signs of ischaemia. Cardiac work up was otherwise normal, with no signs of atherosclerotic coronary artery disease on coronary angiogram. Myocardial systolic function was also normal. In the era of highly sensitive cTn assays, dynamic elevations of cTn are seen in a number of acute conditions unrelated to myocardial ischaemia. Transient global amnesia should be added to the list of acute neurological disorders where cTn release can be present, even in the absence of stress-induced cardiomyopathy.

Keywords

Acute neurological, transient global amnesia, troponin T

Received: 25 November 2013; Accepted: 19 December 2013

Introduction

Elevated cardiac troponin (cTn) levels without demonstrable myocardial ischaemia have been reported in a variety of acute neurological disorders, such as subarachnoid haemorrhage, stroke, transient ischaemic attack, epileptic seizures, traumatic head injury, and encephalitis with and without myocardial wall motion abnormalities.¹ In cases of detected myocardial dysfunction these attacks are labelled neurogenic stunned myocardium and fall under the classification of transient left ventricular (LV) dysfunction syndromes. An overload of endogenous catecholamines inducing cardiac toxicity and transient LV dysfunction has been implicated, which is similar to emotional or physical stress-induced tako-tsubo cardiomyopathy (TTC).² Metaiodobenzylguanidine spectroscopy suggests these stress cardiomyopathy entities have a common neurogenic pathway that leads to transient myocardial dysfunction with normal coronary flow.³

Case presentation

A 75-year-old woman presented to the emergency department with acute memory loss. She had been talking on the phone with relatives about the estate division after her previously deceased brother, when she suddenly started asking repeated questions and couldn't remember what had happened in the evening or morning before. During the phone call, she had become very upset and angry.

As cardiovascular risk factors, this lady had well-controlled hypertension, hypercholesterolaemia, and a family history of coronary artery disease. There was no known

Helsinki University Central Hospital, Helsinki, Finland

Corresponding author:

Johan Lassus, Heart and Lung Center, Division of Cardiology, Helsinki University Central Hospital, PO Box 800, 00029 HUS, Finland.

Email: Johan.Lassus@fimnet.fi

diabetes and no history of smoking. Her previous medical history also included cholecystectomy over a decade ago, gastro-oesophageal reflux disease, and arthrosis of her right knee. Four years ago, the patient had intermittent but repeated symptoms of dizziness, left-sided headache, and a tingling feeling in her left extremities. She was evaluated by a neurologist, a head CT scan was performed with normal result, and mild symptoms of migraine were suspected as the cause. In addition, an exercise test performed 5 years before the current presentation because of mild dyspnoea on exertion showed no signs of obstructive coronary artery disease. Her medications were metoprolol 47.5 mg b.i.d., atorvastatin 10 mg o.d., and acetosalisylic acid 50 mg o.d.

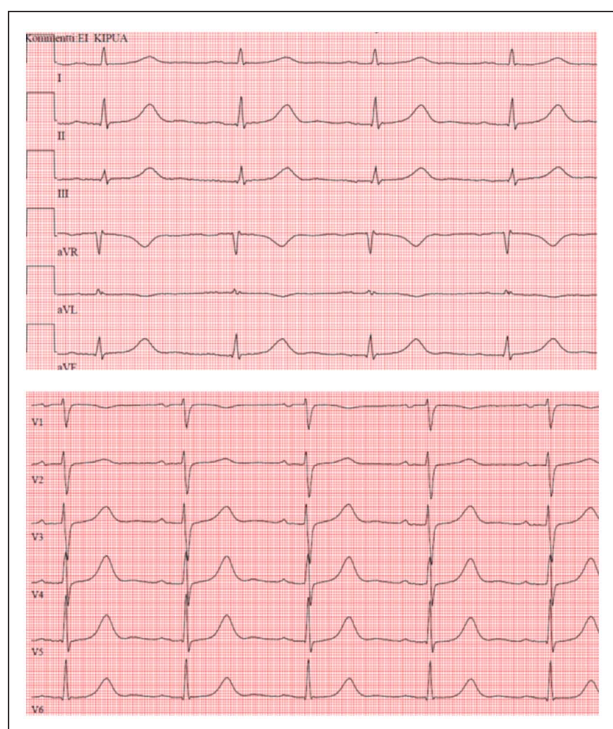


Figure 1. ECG at presentation.

At presentation, the patient remembered calling her relatives, but had amnesia of any events from the last 24 hours. She had no headache or dizziness. According to her husband she had no previous head injury, or recent signs of infection or other symptoms. The patient didn't complain about chest pain or any dyspnoea. General clinical and specific neurological examination was normal, apart from the amnesia. Cardiac auscultation was without murmurs or abnormal findings and no peripheral oedema. Blood pressure was 147/78 mmHg and heart rate was 78 bpm. Body temperature was 37.1°C and body mass index was 33 kg/m². The ECG recorded on admission is shown in Figure 1. Chest X-ray was normal. Laboratory investigations showed 146 g/l haemoglobin, $7.0 \times 10^9/l$ white blood cells, $146 \times 10^9/l$ platelets, 4.7 mmol/l glucose, <3 g/l C-reactive protein, 94 µmol/l creatinine (estimated glomerular filtration rate 51 ml/min), and normal electrolyte and coagulation parameters. Highly sensitive troponin T (hsTnT) was elevated at 227 ng/l (Upper limit of normal [ULN] ULN 14 ng/l).

After consultation of a neurologist, the diagnosis of transient global ischaemia was suggested as the cause of amnesia. There were no clinical symptoms or signs of ischaemic heart disease, and the ECG was considered normal, but hsTnT was clearly elevated and 3 hours later rose further to 440 ng/l.

The patient was admitted to cardiology for further work up because of troponin rise, with suspicion of acute myocardial infarction or possibly stress (tako-tsubo) cardiomyopathy. An echocardiogram showed a normal sized left ventricle (LV end diastolic diameter 47 mm), with normal contractility and no hypokinesia, and LV ejection fraction 60%. There was no LV hypertrophy, and valvular functions were normal. A coronary angiogram, performed to exclude coronary artery disease and acute coronary syndrome, showed normal epicardial vessels with good TIMI 3 flow (Figure 2). LV cineangiography was normal (Figure 3), and LV end diastolic pressure was 7 mmHg. There were no arrhythmias, conduction abnormalities, or abnormal pauses detected on rhythm monitoring.

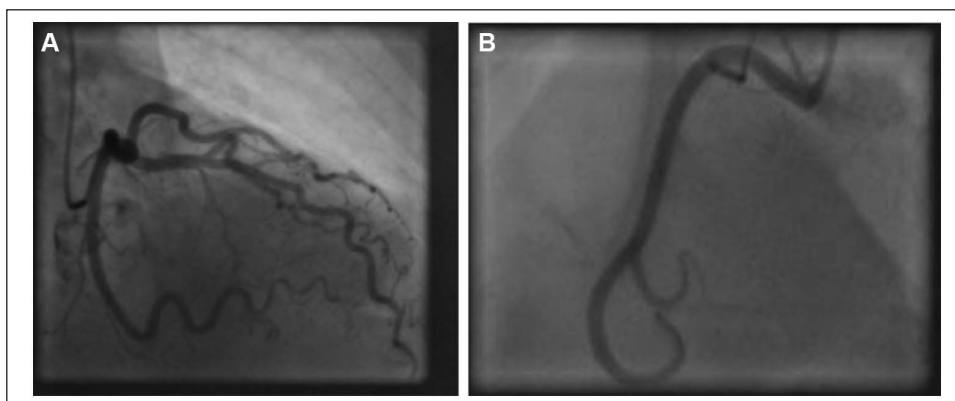


Figure 2. Left (A) and right (B) coronary angiograms of the 75-year-old woman presenting with amnesia and cTnT elevation.

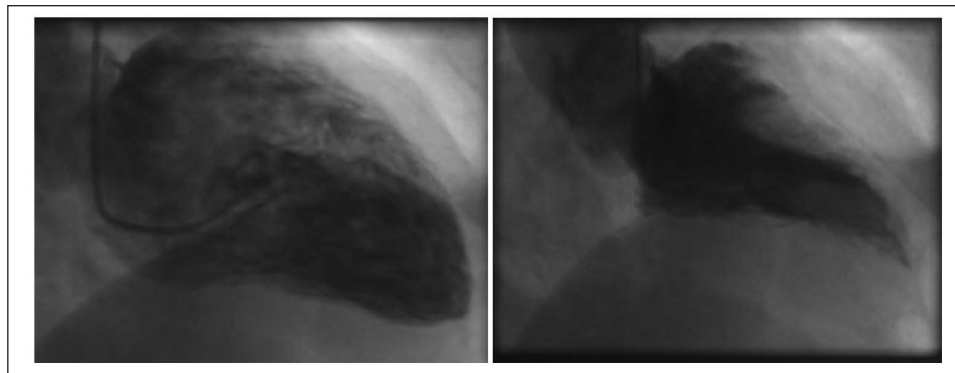


Figure 3. Left ventricular cineangiography showing good myocardial function without disturbed contractility (Left panel: ventricular diastole; right panel: systole).

During the day of presentation, the patient's memory gradually recovered, and by the next morning, there was no evidence of residual amnesia. hsTnT peaked at 440 ng/l and subsequently normalized within 10 days. The patient was ambulatory with no symptoms and was discharged in good condition. There was no recurrence of amnesia or other cerebral symptoms and no cardiac symptoms during follow up.

Discussion

Transient global amnesia (TGA) is a clinical diagnosis defined as a sudden onset of retrograde and especially anterograde amnesia lasting no more than 24 hours. TGA is usually precipitated by emotional stress, strenuous physical activity, acute pain, sexual intercourse, water contact, or temperature change. In women, the preceding event is more often emotional stress, and in men, physical activity often provokes TGA. The annual incidence of TGA is approximately 3–8/100,000 persons, with the majority of attacks occurring in patients 50–70 years of age.⁴ TGA is associated with personality disorders and migraine. Recurrence is rare, with Quinette et al.⁵ reporting a recurrence rate of 3.5%.

Since the recognition of tako-tsubo cardiomyopathy (TTC) as a distinct clinical entity, several case reports about TTC in the setting of acute neurological disease have been published.⁶ Recently, two case reports of patients suffering from TGA and concomitant TTC were published.^{7,8} Differentiating between neurogenic stunned myocardium and TTC can be clinically challenging and is not always straightforward. Indeed, it has very recently been suggested that due to similar epidemiological and pathophysiological patterns, these two entities may be different forms of the same phenomenon and are termed stress cardiomyopathies.^{1,9}

Our patient with TGA had significant acute release of TnT without any findings of myocardial systolic dysfunction. There was no clinical evidence of myocardial ischaemia or an acute coronary event. Imaging exhibited no myocardial wall motion abnormalities and normal LV ejection fraction on both echo cardiogram and LV cineangiograms. Coronary

angiography showed no epicardial (obstructive) coronary artery disease. Elevation of cTn levels with and without neurogenic stunned myocardium has been widely described in various neurological conditions.^{10,11} In the recent universal definition of myocardial infarction, severe acute neurological disease is recognized as one cause of myocardial injury, and cTn elevation of multifactorial or indetermined cause.¹² Since there are no clinical evidence and no ECG changes suggestive of ischaemia, the criteria of myocardial infarction are not fulfilled.

The introduction of more sensitive cardiac troponin (cTnT/I) assays allows earlier detection and risk stratification of patients with myocardial infarction. On the other hand, the increased sensitivity for myocardial necrosis is at the cost of less specificity of mild cTn elevations for acute coronary syndromes or myocardial infarction.¹³ In addition, a significant proportion of patients with various cardiac disorders will have chronic stable elevation of cTn:s. Patients with renal dysfunction also frequently have detectable levels of cTn with or without the presence of manifest cardiac disease. The specificity for acute myocardial injury can be increased by repeated measurements and detection of dynamic changes.¹⁴ Nevertheless, clinicians are often faced with the dilemma of a rise and fall in hsTnT levels without obvious clinical evidence of ischaemia, as in the case of our patient.

TGA certainly classifies as an acute neurological event, but of considerably lesser severity than subarachnoid haemorrhage, stroke, epileptic seizures, or traumatic head injury. All these neurological emergencies, as well as TGA, cause neurohormonal responses including release of stress hormones. While catecholamine excess in its more severe forms causes transient LV dysfunction syndrome or stress cardiomyopathy with typical LV wall motion abnormalities, it has to be recognized that, in milder cases, myocardial injury may be detected by biomarkers even in the absence of disturbances in contractility. This has previously been described for more severe forms of acute neurological disease. Our case suggests that TGA should be added to the list of disorders that can cause elevation of cTnT

without underlying coronary artery disease. We believe that, particularly in the era of sensitive cTn assays, the proportion of patients with acute neurological disorders having detectable cTn levels will increase. In the absence of clinical evidence of ischaemia, antithrombotic medications should be prescribed only after careful consideration of possible bleeding risks. Individualized management and cardiac work up is warranted, to avoid unnecessary investigations and enable focusing on treatment and rehabilitation of the primary, neurological, cause.

In conclusion, elevations of biomarkers of myocardial necrosis occur in various settings of acute severe neurological disease, with or without concomitant disturbance of myocardial contractility. We describe a case with TGA exhibiting a significant rise and fall in hsTnT, with normal left ventricular function and no evidence of coronary artery disease. In the era of sensitive cTn assays, less severe forms of acute neurological disorders, such as TGA, can cause elevations of markers of myocardial injury.

Conflict of interest

The authors declare that there is no conflict of interest.

Funding

This research received no specific grant from any funding agency in the public, commercial, or not-for-profit sectors.

References

1. Porto I, Della Bona R, Leo A, et al. Stress cardiomyopathy (tako-tsubo) triggered by nervous system diseases: a systematic review of the reported cases. *Int J Cardiol* 2013; 167: 2441–2448.
2. Bybee KA and Prasad A. Stress-related cardiomyopathy syndromes. *Circulation* 2008; 118: 397–409.
3. Mikail N, Hess S, Jesel L, et al. Takotsubo and Takotsubo-like syndrome: a common neurogenic myocardial stunning pathway? *Int J Cardiol* 2013; 166: 248–250.
4. Bartsch T and Deuschl G. Transient global amnesia: functional anatomy and clinical implications. *Lancet Neurol* 2010; 9: 205–214.
5. Quinette P, Guillery-Girard B, Dayan J, et al. What does transient global amnesia really mean? Review of the literature and thorough study of 142 cases. *Brain* 2006; 129(Pt 7): 1640–1658.
6. Tsuchihashi K, Ueshima K, Uchida T, et al. Transient left ventricular apical ballooning without coronary artery stenosis: a novel heart syndrome mimicking acute myocardial infarction. Angina Pectoris-Myocardial Infarction Investigations in Japan. *J Am Coll Cardiol* 2001; 38: 11–18.
7. Bobinger T, Kohrman M, Raaz-Schrauder D, et al. Lost memories can break your heart: a case report of transient global amnesia followed by takotsubo cardiomyopathy. *Clin Res Cardiol* 2013; 102: 693–696.
8. Grautoff S, Sitzler M, Weitkamp P, et al. Transient global amnesia and tako-tsubo cardiomyopathy – coincidence or corollary? *Dtsch Med Wochenschr* 2012; 137: 2256–2259.
9. Guglin M and Novotorova I. Neurogenic stunned myocardium and takotsubo cardiomyopathy are the same syndrome: a pooled analysis. *Congest Heart Fail* 2011; 17: 127–132.
10. Thygesen K, Mair J, Katus H, et al. Recommendations for the use of cardiac troponin measurement in acute cardiac care. *Eur Heart J* 2010; 31: 2197–2204.
11. Tanabe M, Crago EA, Suffoletto MS, et al. Relation of elevation in cardiac troponin I to clinical severity, cardiac dysfunction, and pulmonary congestion in patients with subarachnoid hemorrhage. *Am J Cardiol* 2008; 102: 1545–1550.
12. Thygesen K, Alpert JS, Jaffe AS, et al. Third universal definition of myocardial infarction. *Eur Heart J* 2012; 33: 2551–2567.
13. Reichlin T, Hochholzer W, Bassetti S, et al. Early diagnosis of myocardial infarction with sensitive cardiac troponin assays. *N Engl J Med* 2009; 361: 858–867.
14. Thygesen K, Mair J, Giannitsis E, et al. How to use high-sensitivity cardiac troponins in acute cardiac care. *Eur Heart J* 2012; 33: 2252–2257.