

Serial and prolonged EEG monitoring in anti-N-Methyl-D-Aspartate receptor encephalitis

Francisco Pereira da Silva-Júnior*, Luiz Henrique Martins Castro, Joaquina Queiroz Andrade, Carla Guimarães Bastos, Camila Hobi Moreira, Rosa Maria Figueiredo Valério, Carmen Lisa Jorge, Paulo Eurípedes Marchiori, Ricardo Nitrini, Eliana Garzon

Department of Neurology, University of São Paulo, São Paulo, Brazil

ARTICLE INFO

Article history:

Accepted 2 January 2014

Available online xxxx

Keywords:

Encephalitis

Anti-N-Methyl-D-Aspartate receptor

Electroencephalography

HIGHLIGHTS

- Generalized rhythmic delta activity (GRDA) is a common finding in patients with anti-NMDAR encephalitis, but may not be present on a routine 30-min EEG recording.
- Serial and continuous EEG monitoring may be more adequate to detect characteristic patterns (GRDA and extreme delta brush) and seizures in these patients.
- GRDA should not be interpreted as indicative of ictal activity or nonconvulsive status, unless clear frequency, voltage or field evolution, and both electrographic and clinical response to a benzodiazepine are observed.

ABSTRACT

Objective: To describe serial electroencephalographic (EEG) findings of three patients with anti-NMDAR encephalitis.

Methods: Three women (age 15–34 years) with confirmed anti-NMDAR encephalitis underwent serial EEG recordings. Continuous EEG for 72 h was performed in one case and 3-day video-EEG monitoring was obtained in two cases.

Results: Generalized rhythmic delta activity (GRDA) was found in all patients. GRDA persisted for hours, but was not continuous on a 24-h EEG recording, disclosed no frequency, voltage or field evolution, and was not seen on the first EEG of two patients. Extreme delta brush was noted in two patients who presented more severe disease. One patient presented seizures, which were electrographically and clinically different from the GRDA pattern and from dyskinetic movements.

Conclusions: Serial or continuous EEG may be necessary to detect GRDA in anti-NMDAR patients. To avoid unnecessary treatment, this pattern should not be interpreted as indicative of ictal activity, unless there is evidence of its ictal nature.

Significance: Our findings may contribute to the diagnosis of anti-NMDAR encephalitis in cases with characteristic clinical picture.

© 2014 International Federation of Clinical Neurophysiology. Published by Elsevier Ireland Ltd. All rights reserved.

1. Introduction

Anti-N-Methyl-D-Aspartate receptor (NMDAR) encephalitis is characterized by psychiatric symptoms, cognitive impairment, decreased responsiveness, abnormal movements, seizures, hypoventilation and autonomic instability. It can occur in a paraneoplastic setting, most commonly, an ovarian teratoma. Brain MRI

is normal in about 50% of patients, and cerebrospinal fluid analysis (CSF) is usually abnormal, with mild lymphocytic pleocytosis, increased protein levels, and the diagnosis is confirmed by CSF presence of anti-NMDAR antibodies (Dalmau et al., 2011).

The frequency of anti-NMDAR encephalitis is higher than previously appreciated, outnumbering viral etiologies like enterovirus and herpes simplex virus type 1 in younger populations (Gable et al., 2012). Early diagnosis and treatment improve outcome, since immunotherapy and tumor removal are highly effective treatments for this condition (Darnell and Posner, 2009; Florance et al., 2009; Dalmau et al., 2011).

* Corresponding author. Address: R Dr Melo Alves, 55 Apto 123 Cerqueira César, CEP: 01417-010 São Paulo, SP, Brazil. Tel.: +55 11 982025480.

E-mail address: franciscops@hotmail.com (F.P. da Silva-Júnior).

Electroencephalogram (EEG) is useful in anti-NMDAR encephalitis, not only for seizure and status epilepticus detection (Johnson et al., 2010; Dalmau et al., 2011; Kirkpatrick et al., 2011), but also for diagnosis (Florance et al., 2009; Gable et al., 2012). EEG is abnormal in almost all patients, showing disorganized background activity in most cases (Florance et al., 2009; Dalmau et al., 2011). Data on EEG features of patients undergoing prolonged recording or serial recordings is still scarce.

Our aim was to describe the EEG characteristics of three patients with anti-NMDAR encephalitis.

2. Methods

Serial EEG recordings of three female patients with confirmed anti-NMDAR encephalitis were reviewed. Two patients underwent video-EEG for 3 days and, for one of them, continuous EEG monitoring for 72 h was also obtained. Serial and continuous EEGs with concomitant video recordings were performed with 32-channel Nihon Kohden 1200 (Japan) and video-EEG recordings were obtained with 32-channel Bio-logic ver.5.1.18.90 (USA) equipment.

Days after hospital admission on which treatments were carried out were indicated as D_n.

3. Results

3.1. Case histories

3.1.1. Patient 1

A 15-year-old woman presented with a 2-week history of behavioral changes, alternating periods of apathy and agitation, associated with fever, seizures and choreic movements in the arms and legs, blinking and chewing. Brain CT was normal, CSF analysis showed 13 cells, with normal protein concentration. She was intubated and admitted to the intensive care unit (ICU). Acyclovir was initiated for possible herpetic encephalitis, later withdrawn after negative CSF polymerase chain reaction for herpes was received. Brain MRI was unremarkable. The patient received intravenous methylprednisolone (MP, 1 g/day, D_{6–10}) and cyclophosphamide (CYC, 1 g, D₁₀). Anti-NMDAR antibodies were identified in the CSF 2 months after admission. Cervical, thoracic, abdominal and pelvic CT and MRI did not reveal any malignancy. She also received intravenous immunoglobulin (400 mg/kg/day, D_{53–57}), and MP pulse therapy was repeated (D_{87–91} and D_{131–135}). Progressive improvement was observed. Total hospital stay was 140 days. She was discharged with moderate disability (modified Rankin scale-mRS 4), but progressive improvement was observed on follow-up (mild cognitive deficits, mRS 1, one year after discharge).

During hospital admission, she underwent continuous EEG monitoring for 72 h (performed in the third week of hospitalization), video-EEG monitoring for 3 days (80 days after admission), and 35 serial EEG recordings.

3.1.2. Patient 2

A 23-year-old woman complained of concentration difficulty 10 days before admission. Her condition progressively deteriorated, with behavioral changes, fever, delusional thoughts and unresponsiveness. Brain CT and MRI were normal, and CSF analysis showed 56 cells, with normal protein levels. Acyclovir was initiated and the patient was intubated. Seizures and orofacial dyskinesias were witnessed. She received pulse therapy with MP (1 g/day, D_{6–10} and D_{65–69}), CYC (1 g, D₂₄ and D₆₀) and intravenous immunoglobulin (400 mg/kg/day, D_{11–15}). Anti-NMDAR antibodies were detected in the CSF 1 month after admission. Cervical, thoracic, abdominal and pelvic CT were unremarkable. The patient died from sepsis, 71 days after hospital admission.

Fourteen EEG recordings were performed.

3.1.3. Patient 3

This 34-year-old woman presented with a 2-month history of behavioral changes and delusional thoughts, psychomotor slowing and motor focal seizures, followed by orofacial dyskinesias. Brain CT was normal. CSF analysis showed nine cells and normal protein levels. She was admitted to the ICU, and started on acyclovir. Brain MRI disclosed signal changes in FLAIR sequences in the right temporal lobe white matter and in the right precentral cortex. Whole body PET-CT scan did not disclose hypermetabolic lesions. She received immunotherapy with MP (D_{20–24}), CYC (D₂₄) and IV immunoglobulin (D_{69–73}). Diagnosis was confirmed with positive anti-NMDAR antibodies in the CSF 1 month after admission. The patient was discharged after a 3-month hospital stay, with a mRS score 2. When she was readmitted 2 months later to receive another pulse therapy course, she presented mild cognitive deficits (mRS 1).

Twenty-one serial EEG recordings and 72-h video-EEG monitoring were performed.

3.2. Electroencephalographic findings

Diffuse background slowing was the most common EEG finding. Brief bursts of theta or delta activity were often present, mainly over the anterior regions. For Patient 3, these abnormalities predominated in the right hemisphere throughout the illness course.

Generalized rhythmic delta activity (GRDA) was found in all patients (Fig. 1). Delta frequency ranged from 1 to 4 Hz. GRDA could occur continuously on 30-min recordings, but not on continuous EEG monitoring, comprising about 20% of the 24 h EEG recording. This pattern persisted for minutes or hours, at times replaced by long periods of nonspecific irregular theta or delta activity, which lasted for hours, with intermittently superimposed faster (beta/alpha) activity, possibly secondary to sedative medication. For Patient 1, GRDA was recorded in the first EEG, obtained 2 weeks after symptom onset. For Patients 2 and 3, GRDA was not seen in the first EEG recording (2 and 4 days after admission, respectively), but was present in the second EEG, performed, respectively, 2 weeks and two and a half months after disease onset. GRDA was always synchronous, occurred in a monotonous manner not clearly evolving in frequency, voltage or field, was not related to body or facial movements, and did not disappear with intravenous benzodiazepine administration. For Patients 1 and 3, GRDA was still present, in shorter bursts, lasting less than 10 s, in EEGs performed 4 and 7 months after disease onset, when clinical improvement had already occurred. It remained present in the last EEG obtained in Patient 2, 80 days after symptom onset.

Patients 1 and 2 presented bursts of rhythmic beta (14–40 Hz) activity superimposed on rhythmic delta activity (Fig. 2), that lasted for minutes or hours. This recently recognized pattern was coined as “extreme delta brush” (EDB) (Schmitt et al., 2012).

Epileptiform abnormalities were rarely found for Patient 1 (less than one per hour), and were not seen in the other patients' recordings. Patient 1 also presented seizures, detected only on video-EEG monitoring. Four seizures were recorded, characterized by gaze and head deviation to the right or to the left, followed by secondary generalization. EEG analysis was limited by eye movement and muscle artifacts. Ictal correlate in one right versive seizure was rhythmic theta activity over the left hemisphere, with later right hemisphere involvement, followed by postictal background slowing on the left and, after some seconds, on the right hemisphere.

EEG background activity improved in parallel with amelioration of clinical symptoms. No ictal-like patterns were observed.

For Patients 1 and 3, EEGs were also performed 12 and 4 months after hospital discharge. GRDA was not present in any

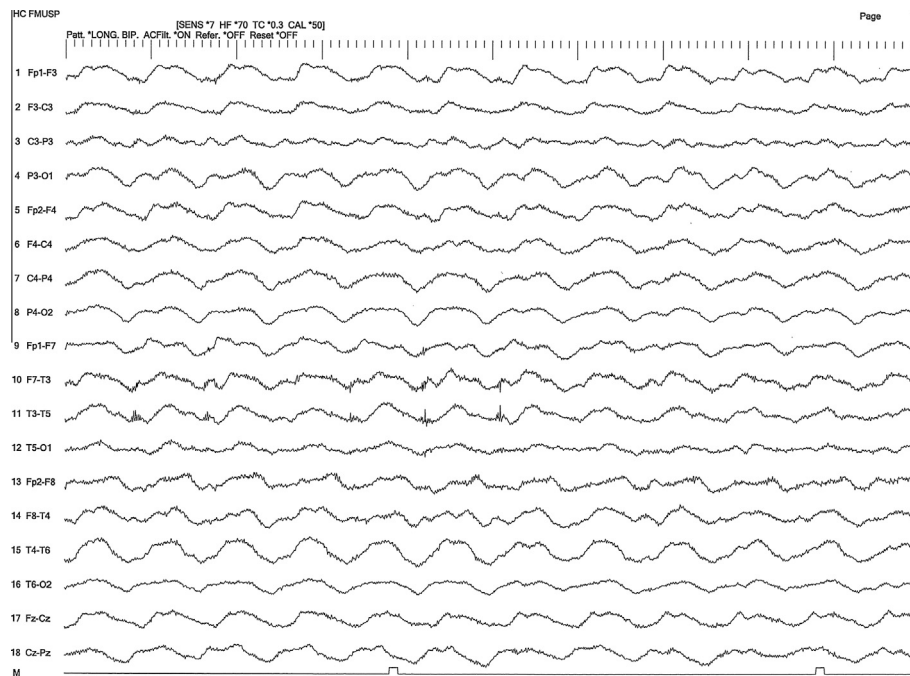


Fig. 1. Ten-second epoch of an electroencephalographic record from a patient with anti-NMDAR encephalitis, showing generalized rhythmic delta activity (Patient 1). Parameters were as follows: sensitivity 7 μ V/mm, time constant 0.3 s and high-frequency filter 70 Hz.

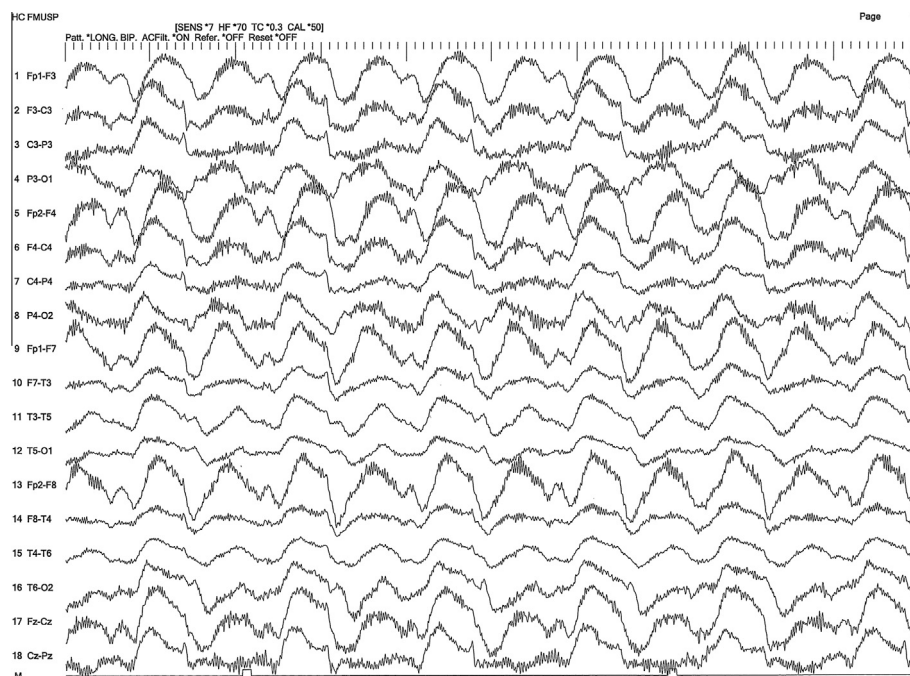


Fig. 2. Ten-second epoch of an electroencephalographic record from a patient with anti-NMDAR encephalitis, showing extreme delta brush (Patient 2). Parameters were as follows: sensitivity 7 μ V/mm, time constant 0.3 s and high-frequency filter 70 Hz.

of these recordings. The only observed abnormality consisted of mild background slowing and excess theta activity.

4. Discussion

Diagnosis of anti-NMDAR encephalitis requires detection of antibodies directed to the NMDAR receptor NR1 subunit, which may not be readily available in many world regions. Clinical

features of this condition are characteristic, and patients with suggestive clinical presentation should receive prompt immunotherapy, as long as infectious diseases are ruled out (Lee et al., 2012). As EEG is widely available, characterization of typical EEG findings may be of great value to corroborate diagnosis, when the clinician faces a possible anti-NMDAR encephalitis case.

In a study addressing the EEG features of 23 patients with anti-NMDAR encephalitis, main findings were diffuse background slowing with polymorphic slow waves and GRDA. EDB pattern was seen

in 30.4% of patients (Schmitt et al., 2012). In our case series, EDB pattern was not seen in Patient 3, who had a milder disease, concordant with previous reports, indicating that this pattern may be a marker of disease severity.

The main strength of this case series is the analysis of continuous and serial EEG recordings, which indicate that neither GRDA nor EDB occur on a continuous basis, but as longstanding bursts lasting minutes or hours. These patterns could be absent on routine, 30-min, EEG recordings, and may remain present for many months after disease onset, when clinical improvement has occurred. Seizures were recorded in only one patient who underwent video-EEG monitoring. Clinical features of seizures were different from dyskinesias presented by the patient. Ictal EEG patterns also differed from GRDA.

The significance of GRDA and EDB are still incompletely understood. GRDA has been recognized as a form of nonconvulsive status epilepticus in a patient with anti-NMDAR encephalitis (Kirkpatrick et al., 2011), and in three patients with other unrelated conditions (Uthman and Bearden, 2008). In all these cases, the authors have shown clearcut EEG activity that evolved in frequency, voltage and field. Electrographic and clinical improvement was noted in response to intravenous benzodiazepine administration.

This was not the case in our patients. In line with our findings, EEG features in an 8-year-old boy with anti-NMDAR encephalitis were recently published. GRDA was the most prominent EEG feature, but electrographic criteria for seizures were not fulfilled (Gataullina et al., 2011). The authors claimed that GRDA in anti-NMDAR encephalitis may represent the effect of the antibody against the NMDAR, leading to reduced NMDA function. Indeed, experimental studies have found that NMDAR blockage in the nucleus reticularis of the thalamus switches neuronal cell firing mode from tonic to rhythmic bursting mode, in the delta frequency range (Zhang et al., 2009). This may be related to antibody binding to the NMDAR.

In parallel with clinical improvement, GRDA occurred less frequently, but could still be noted on prolonged continuous recordings or on routine EEG. The relation of this electrographic pattern and clinical response should be studied in larger cohorts.

This limited case series does not allow conclusions about sensitivity and specificity of GRDA and EDB in anti-NMDAR encephalitis.

However, the finding of these patterns may contribute to establish the diagnosis in a case with a characteristic clinical picture. The role of these EEG findings as markers for treatment response needs further clarification. Prolonged EEG recording appears to be more adequate to quantify the presence of these patterns over extended periods, and may provide additional information regarding response to treatment. While the nature of GRDA and EDB remains unclear, these patterns should not be interpreted as ongoing ictal activity or nonconvulsive status, unless there is other compelling evidence of the ictal nature of these EEG patterns.

Conflict of interest

The authors declare no conflict of interest.

References

- Dalmau J, Lancaster E, Martinez-Hernandez E, Rosenfeld MR, Balice-Gordon R. Clinical experience and laboratory investigations in patients with anti-NMDAR encephalitis. *Lancet Neurol* 2011;10:63–74.
- Darnell RB, Posner JB. Autoimmune encephalopathy: the spectrum widens. *Ann Neurol* 2009;66:1–2.
- Florance NR, Davis R, Lam C, Szperka C, Zhou L, Ahmad S, et al. Anti-N-Methyl-D-Aspartate receptor encephalitis in children and adolescents. *Ann Neurol* 2009;66:11–8.
- Gable MS, Sheriff H, Dalmau J, Tilley DH, Glaser CA. The frequency of autoimmune N-Methyl-D-Aspartate receptor encephalitis surpass that of individual viral etiologies in young individuals enrolled in the California Encephalitis Project. *Clin Infect Dis* 2012;54:899–904.
- Gataullina S, Plouin P, Vincent A, Scalais E, Nuttin C, Dulac O. Paroxysmal EEG pattern in a child with N-methyl-D-aspartate receptor antibody encephalitis. *Dev Med Child Neurol* 2011;53:764–7.
- Johnson N, Henry C, Fessler AJ, Dalmau J. Anti-NMDA receptor encephalitis causing prolonged nonconvulsive status epilepticus. *Neurology* 2010;75:1480–2.
- Kirkpatrick MP, Clarke CD, Sonmez Turk HH, Abou-Khalil B. Rhythmic delta activity represents a form of nonconvulsive status epilepticus in anti-NMDA receptor antibody encephalitis. *Epilepsy Behav* 2011;20:392–4.
- Lee R, Buckley C, Irani SR, Vincent A. Autoantibody testing in encephalopathies. *Pract Neurol* 2012;12:4–13.
- Schmitt SE, Pargeon K, Frechette ES, Hirsch LJ, Dalmau J, Friedman D. Extreme delta brush: a unique EEG pattern in adults with anti-NMDA receptor encephalitis. *Neurology* 2012;79:1094–100.
- Uthman B, Bearden S. Rhythmic diffuse delta frequency activity presenting as an unusual EEG correlate of nonconvulsive status epilepticus: three case studies. *Epilepsy Behav* 2008;12:191–9.
- Zhang Y, Llinas RR, Lisman JE. Inhibition of NMDARs in the nucleus reticularis of the thalamus produces delta frequency bursting. *Front Neural Circuits* 2009;3:20.