



Recovery and outcome of frontal alien hand syndrome after anterior cerebral artery stroke



Dennis A. Nowak^{a,b,*}, Kathrin Bösl^b, Jitka Lüdemann-Podubecka^b, Hans-Jürgen Gdynia^b, Matthias Ponfick^{a,b}

^a Department of Neurology, Philipps-University Marburg, Germany

^b Klinik Kipfenberg, Neurologische Fachklinik, Kipfenberg, Germany

ARTICLE INFO

Article history:

Received 22 November 2013

Received in revised form 3 January 2014

Accepted 5 January 2014

Available online 11 January 2014

Keywords:

Alien hand

Stroke

Rehabilitation

Outcome

Case report

Frontal release

ABSTRACT

Ischemic lesions within the territory of the anterior cerebral artery present with a variety of clinical signs and symptoms. Among these, frontal alien hand syndrome is rare and easily overlooked in the acute clinical setting, but significantly impacts on functional activities of daily life. Given its rareness, very little is known about its long-term outcome. To shed some more light onto this issue, clinical presentation, course of rehabilitation and outcome of two illustrative cases of frontal alien hand syndrome following anterior cerebral artery stroke are presented. Within seven and nine months from symptom onset, respectively, the clinical symptoms of frontal alien hand had resolved completely in both cases. We conclude that frontal alien hand syndrome has a favourable long-term outcome.

© 2014 Elsevier B.V. All rights reserved.

1. Introduction

According to Feinberg and colleagues two different clinical manifestations of the alien hand syndrome can be distinguished [1]. *Frontal alien hand syndrome* may affect the dominant or non-dominant hand and presents with impulsive grasping, groping and compulsive manipulation of environmental objects, all in the presence of frontal release signs [1–3]. In contrast, *callosal alien hand syndrome* usually affects the non-dominant hand and presents with inter-manual intention conflict in the absence of frontal release signs [1,3]. In the acute clinical setting a frontal type alien hand is frequently overlooked given the wide spectrum of clinical signs and symptoms to be encountered after anterior cerebral artery stroke of the of the dominant hemisphere. Given its rareness data to judge upon the long-term outcome of the syndrome are ambiguous [1–3]. Here we present the clinical presentation, rehabilitative course and outcome of two illustrative cases of frontal alien hand syndrome.

2. Case reports

2.1. Case 1

A 54-year-old right-handed Caucasian female was admitted to the neurological rehabilitation unit six days after an acute ischemic

stroke within the territory of the left anterior cerebral artery (Fig. 1a and b).

At this time her neurological status revealed speech hesitation with non-fluent, “staccato”-like speech, right hemiparesis (4/5 in the upper extremity and 3/5 in the lower extremity on the Medical Research Council Scale [4]) with moderate spasticity (2/4 on the modified Ashworth scale [5]), enhanced deep tendon reflexes of the right hemibody with Babinski's sign, palmo-mental reflex on the right, grasping reflex and an alien hand syndrome of the right hand. The alien hand syndrome was characterized by an inability to release the grip of the examiner, continuous groping and grasping for objects in her sight (pencils, mobile phone, drinking cup) and fumbling and buttoning on her clothes. The alien hand severely hampered her daily life activities, e.g. the involuntary grasping and groping interfered with the preparation and execution of tooth and hair brushing or dressing. Bimanual coordination was markedly impaired, e.g. she was unable to eat simultaneously with knife and fork. At times the right hand interfered with motor actions of her left hand. She was well aware that her right hand belonged to her (even when tested blindfolded), but expressed her inability to suppress the involuntary groping and grasping movements for a longer period of time. In an attempt to control the involuntary behaviour of her right hand, she clamped the hand under her thigh, wedged it between her legs or even tried to immobilize it by putting it into a pocket or a bag. There was no ideomotor apraxia (imitation of meaningless gestures [6] or meaningful gestures on command), no visual neglect (line bisection test [7]), no alexia, no writing impairment (right hand) or tactile anomia (both hands).

* Corresponding author at: Klinik Kipfenberg, Neurologische Fachklinik, Kindinger Straße 13, D-85110 Kipfenberg, Germany. Tel.: +49 8465 175 102; fax: +49 8465 175 222.

E-mail address: dennis.nowak@neurologie-kipfenberg.de (D.A. Nowak).

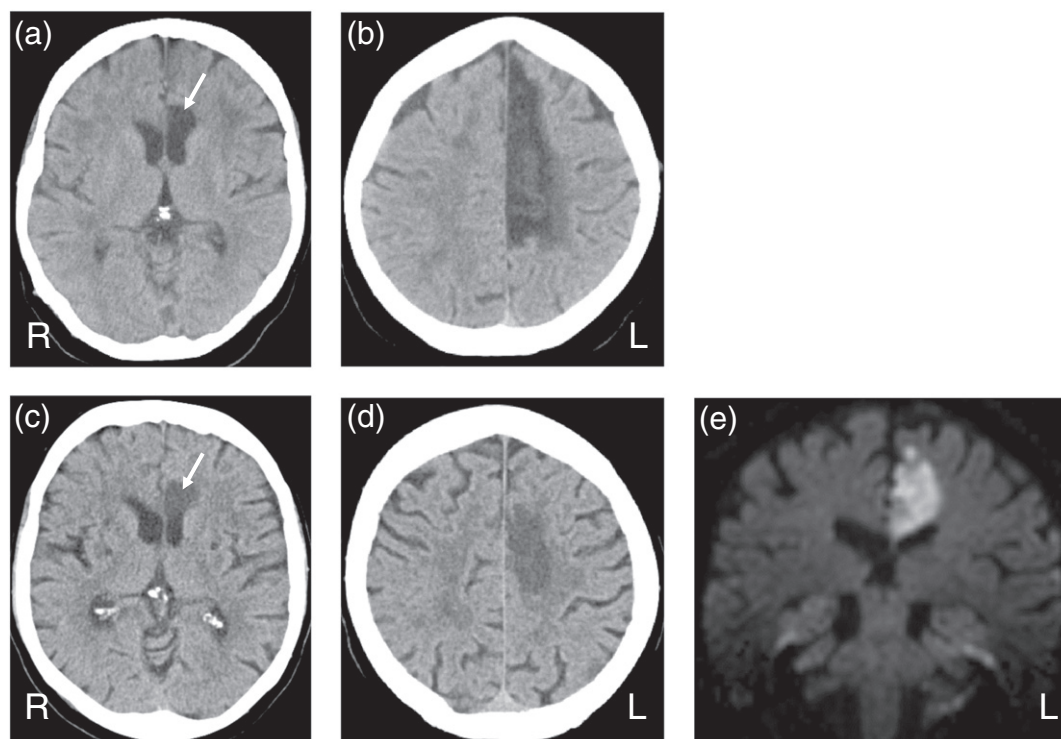


Fig. 1. Axial computed tomography images showing hypodense lesions of the anterior part of the left corpus callosum, left anterior paramedian periventricular white matter (arrow) and adjacent paramedian cortex consistent with an ischemic lesion within the territory of the left anterior cerebral artery in case 1 (a and b) and case 2 (c and d). Coronal diffusion-weighted image demonstrating the ischemic lesion of the anterior part of the corpus callosum and the overlying white matter in case 2 (e).

A 9-week period of rehabilitation commenced and her progress in recovery of daily life activities as assessed by the Functional Independence Measure score [8] is illustrated in Fig. 2. She received daily sessions of physiotherapy, occupational therapy and speech therapy over the entire rehabilitation period. Her neurological examination at discharge ten weeks after symptom onset exhibited a non-fluent speech production, residual right leg paresis (3/5 on the Medical Research Council Scale [4]) with moderate spasticity and grasping reflex. The alien hand syndrome of the right hand with involuntary groping and grasping of environmental objects was still present and hampered bimanual motor actions in daily life.

18 weeks after discharge (28 weeks after symptom onset) her neurological status was markedly improved. Her speech was unimpaired. There was a moderate paresis of the right leg (3/5 on the Medical Research Council Scale [4]) with mild spasticity. The remainder of her neurological status was normal. She was able to wash, dress and prepare meals unassisted. She walked and climbed stairs unassisted. In Fig. 2 her functional capacities in daily life activities as assessed by the Functional Independence Measure score [8] is shown at week 28 after symptom onset. At this time the alien hand syndrome was no longer evident.

2.2. Case 2

A 71-year old right-handed Caucasian female was admitted to the neurological rehabilitation unit one week after an acute ischemic stroke within the territory of the left anterior cerebral artery (Fig. 1c, d and e). Neurological examination showed non-fluent spontaneous speech production with speech hesitation, mildly reduced impetus, paresis of the right leg (2/5 in the lower extremity on the Medical Research Council Scale [4]) with enhanced muscle tone (2/4 on the modified Ashworth scale [5]), palmomental reflex on the right, grasping reflex of the right hand, ideomotor apraxia for meaningless gestures [6] and meaningful gestures, tactile neglect for the right hemi-body and alien hand syndrome of her right hand. The alien hand syndrome was characterized

by frequent impulsive reaching and grasping for objects within her sight (grasping for objects placed on the table in front of her, fumbling and buttoning clothes and shirts she was wearing) and difficulties to voluntarily release objects from the right hand once grasped. The involuntary movements of her right hand interfered with purposeful actions of her left hand and she was unable to suppress them for a longer period of time. Bimanual tasks, such as eating with cutlery or folding a shirt or piece of paper, were severely hampered. She suffered from the unintended movements of her right hand, but did not apply any strategies to control them. Denial of ownership of the right upper limb was not evident. There was no tactile anomia at either hand, no alexia, no visual neglect [7] and no writing impairment (right hand).

A 18-week period of rehabilitation with daily sessions of occupational therapy, physiotherapy and speech therapy commenced. Her rehabilitative course is illustrated in Fig. 2. At discharge 19 weeks after her stroke, she was able to sit and stand unsupported. She washed and dressed with the aid of caregivers. She was able to walk with a walking stick in her left hand for up to 20 m. She comprehended language well, but still suffered from non-fluent speech production with problems to initiate speech. Her neurological examination revealed a residual paresis of the right leg (3/5 on the Medical Research Council Scale [4]), grasping reflex of the right hand, ideomotor apraxia and impulsive reaching and grasping of objects and inability to release objects once grasped with the right hand. The involuntary movements of her right hand still interfered with bimanual motor tasks.

18 weeks after discharge (37 weeks after symptom onset) her neurological status showed non-fluent speech production, moderate paresis of her right leg (3/5 on the Medical Research Council Scale [4]) and ideomotor apraxia. Her alien hand syndrome had resolved. There was no involuntary grasping and groping with her right hand. She had no problems to release objects from her grasp. She washed and dressed with assistance by her caregiver. She was able to prepare meals unassisted and walked with a walking frame for up to 100 m. Her functional status in daily life motor and cognitive activities at this time (37 weeks after symptom onset) can be depicted from Fig. 2.

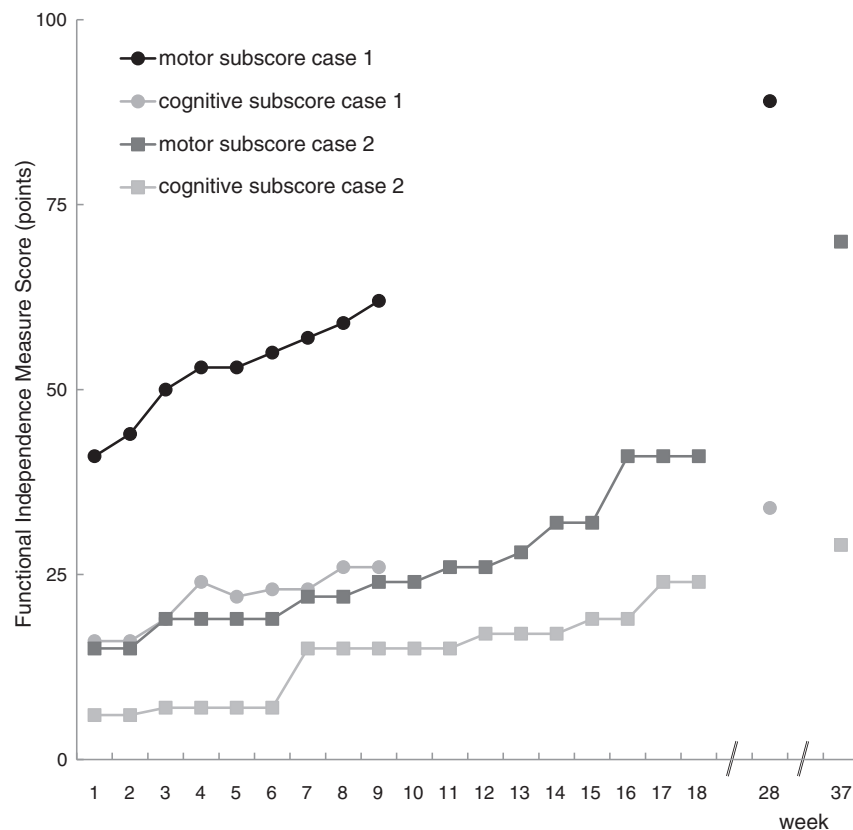


Fig. 2. Motor and cognitive subscores of the Functional Independence Measure scale for both cases of frontal alien hand syndrome over the course of neurological rehabilitation and follow-up.

3. Discussion

The frontal alien hand syndrome is a rare clinical condition and data upon its response to rehabilitation and long-term outcome are scarce. Here we report two cases of frontal alien hand syndrome due to dominant, e.g. left, anterior cerebral artery infarction. Both patients presented with a right-sided hemiparesis, which was most pronounced at the lower limb, non-fluent speech production with speech hesitation and intact speech comprehension, and an alien hand syndrome of the dominant, e.g. right, hand with impulsive grasping, groping and compulsive manipulation of environmental objects in the presence of frontal release signs. The involuntary movements of the right hand interfered with bi-manual coordination in motor activities of daily life in both cases. Neither patient exhibited denial of ownership of the right upper limb. Based on clinical presentation, the alien hand syndrome to be found in both patients was classified as frontal type according to Feinberg and coworkers [1]. The frontal type of alien hand can be clearly distinguished from the callosal type of alien hand syndrome [1–3]. Callosal alien hand syndrome usually affects the non-dominant hand and is characterized by inter-manual conflict in the presence of other clinical features, such as apraxia, tactile anomia, agraphia, visual anomia, neglect and alexia, with the latter commonly summarized as callosal disconnection syndrome [9–11].

The frontal type of alien hand syndrome has been found to be associated with lesions of the supplementary motor area, anterior cingulate gyrus, medial prefrontal cortex and anterior corpus callosum [12,13]. The stroke-afflicted brain lesions in our two cases comprised the anterior corpus callosum, anterior cingulate gyrus, supplementary motor area and the medial frontal cortex (see Fig. 1). Non-fluent speech production with speech hesitation is well-known after lesions of the supplementary motor area and its neural connections to Broca's area [11,13]. Frontal release signs, such as enhanced grasp and palmo-mental reflexes, are frequently found after lesions of both the medial frontal cortex and

supplementary motor area [12]. The lesions responsible for the frontal alien hand syndrome – under discussion here – have not been well localized. Impulsive grasping, groping and compulsive manipulation of objects have been described not only after lesions of the medial frontal lobe (including the supplementary motor area) of the dominant (left) hemisphere with or without involvement of the corpus callosum [6,12,14,15], but also after lesions of the left anterior corpus callosum alone [3]. A systematic study found these clinical signs to occur in about 8% of consecutive patients admitted to a neurological ward and in 70% of those who had damage to medial frontal areas [16]. In contrast, lesions of the posterior body of the corpus callosum and splenium may cause inter-manual conflict, somatosensory deficits, tactile anomia, agraphia, alexia, neglect and visual anomia [9–11,17]. Based on these data it appears reasonable that the clinical symptoms of the frontal alien hand syndrome arise from structural and functional damage to the secondary motor areas of the medial frontal lobe (of the dominant hemisphere) and its interhemispheric connections.

Both patients made a good clinical recovery during several weeks of neurological rehabilitation and thereafter (Fig. 2). Seven and nine months after symptom onset, respectively, the frontal alien hand syndrome had resolved completely in both patients. This observation highlights the favourable long-term outcome of frontal alien hand syndrome. Literature data regarding the prognosis of frontal type alien hand are scarce and incongruent. Some reports state no relevant improvement of impulsive grasping, groping and compulsive manipulation of objects after up to 12 months of follow-up [1,3,12,18], while others concluded significant symptom relief over a follow-up of 6 months [3,19]. Given its rareness, the question of what specific therapeutic strategy may be best to overcome the neurological handicap resulting from frontal alien hand syndrome is still unanswered. Some authors have seen growing anger and frustration in affected individuals, which tainted rehabilitative efforts and warranted cognitive and neuropsychological interventions [12]. Experience with pharmacological

treatment is limited to platelet aggregation inhibitors or anticoagulants given to prevent further cerebro-vascular incidents. Both patients under discussion here showed a gradual improvement of compulsory grasping and groping as well as bimanual motor actions in daily life activities over time. During the rehabilitation period ergotherapy and physiotherapy included behavioural strategies to suppress the unwanted behaviour of the right hand and compensate deficits in bimanual motor actions. In particular, patients were instructed to suppress the unwanted groping and grasping of the right hand and to actively involve both hands in bimanual tasks. Bimanual tasks, such as loading the toothbrush with paste, dressing the upper body, eating with cutlery, reading and folding a newspaper, were actively trained with constant feedback by therapists. However, both patients appeared to be unable to retain these strategies and transfer them in daily life activities outside the therapy sessions. Both patients' care-givers reported a gradual improvement of the alien hand signs and symptoms during the follow-up period after discharge.

In conclusion, the present set of data extends our current knowledge upon the frontal alien hand syndrome by demonstrating that it may have a favourable long-term outcome. This information is of relevance to both physicians and affected individuals.

Conflict of interest

On behalf of all authors, the corresponding author states that there is no conflict of interest.

References

- [1] Feinberg TE, Schindler RJ, Flanagan NG, Haber LD. Two alien hand syndromes. *Neurology* 1992;42:19–24.
- [2] Brainin M, Seiser A, Matz K. The mirror world of motor inhibition: the alien hand syndrome in chronic stroke. *J Neurol Neurosurg Psychiatry* 2008;79:246–52.
- [3] Goldberg B, Bloom KK. The alien hand sign. Localization, lateralization and recovery. *Am J Phys Med Rehabil* 1990;69:228–38.
- [4] Medical Research Council. Aids to examination of the peripheral nervous system. London: Her Majesty's Stationary Office; 1976.
- [5] Bohannon R, Smith M. Interrater reliability of a modified Ashworth scale of muscle spasticity. *Phys Ther* 1987;67:206–7.
- [6] Goldenberg G, Laimgruber K, Hermsdörfer J. Imitation of gestures by disconnected hemispheres. *Neuropsychologia* 2001;39:1432–43.
- [7] Schenkenberg T, Bradford DC, Ajax ET. Line bisection and unilateral visual neglect in patients with neurologic impairment. *Neurology* 1980;30:509–17.
- [8] Hamilton BB, Granger CV, Sherwin FS, Zielezny M, Tashman JS. A uniform national data system for medical rehabilitation. In: Fuhrer MJ, editor. *Rehabilitation outcomes: analysis and measurement*. Baltimore, MD: Brookes; 1987. p. 137–47.
- [9] Giroud M, Dumas R. Clinical and topographical range of callosal infarction: a clinical and radiological correlation study. *J Neurol Neurosurg Psychiatry* 1995;59:238–42.
- [10] Lausberg H, Göttert R, Münssinger U, Boegner F, Marx P. Callosal disconnection syndrome in a left-handed patient due to infarction of the total length of the corpus callosum. *Neuropsychologia* 1999;37:253–65.
- [11] Watson RT, Heilman KM, Bowers D. Magnetic resonance imaging (MRI, NMR) scan in a case of callosal apraxia and pseudoneglect. *Brain* 1985;108:535–6.
- [12] Kikkert MA, Ribbers GM, Koudstaal PJ. Alien hand syndrome in stroke: a report of 2 cases and review of the literature. *Arch Phys Med Rehabil* 2006;87:728–32.
- [13] Geschwind DH, Iacoboni M, Mega MS, Zaidel DW, Cloughesy T, Zaidel E. Alien hand syndrome: interhemispheric motor disconnection due to a lesion of the midbody of the corpus callosum. *Neurology* 1995;45:802–8.
- [14] McNabb AW, Carroll WM, Mastalgia FL. Alien hand and loss of bimanual coordination after dominant anterior cerebral artery territory infarction. *J Neurol Neurosurg Psychiatry* 1988;51:218–22.
- [15] La Plane D, Talairach J, Meininger V, Bancaud J, Orgogozo JM. Clinical consequences of corticectomies involving the supplementary motor area in man. *J Neurol Sci* 1977;34:301–14.
- [16] De Renzi E, Barbieri C. The incidence of the grasp reflex following hemispheric lesions and its relation to frontal damage. *Brain* 1992;115:293–313.
- [17] Degos JD, Gray F, Louarn F, Ansquer JC, Poirier J, Barbizet J. Posterior callosal infarction. Clinicopathological correlations. *Brain* 1987;110:1155–71.
- [18] Goldberg G, Meyer NH, Togliu JU. Medial frontal cortex infarction and the alien hand sign. *Arch Neurol* 1981;38:683–6.
- [19] Chan JL, Ross ED. Alien hand syndrome: influence of neglect on the clinical presentation of frontal and callosal variants. *Cortex* 1997;33:287–99.