

Primary clinical manifestation of systemic amyloidosis in the central nervous system

Anetta Lasek-Bal¹, Michał Holecki², Anita Czapska³, Aleksandra Karuga¹, Jan Duława²

¹ Department of Neurology, Medical University of Silesia, University Hospital No. 7, The Upper-Silesian Medical Centre, Katowice, Poland

² Department of Internal Medicine and Metabolic Diseases, Medical University of Silesia, University Hospital No. 7, The Upper-Silesian Medical Centre, Katowice, Poland

³ Department of Radiology, Medical University of Silesia, University Hospital No. 7, The Upper-Silesian Medical Centre, Katowice, Poland

A 67-year-old male patient was admitted to the Department of Neurology, Medical University of Silesia, because of progressive weakness of the left limbs persisting for several days. The patient's relatives reported memory disturbances that had started a few months earlier. The patient had a history of untreated cardiac arrhythmia and a neurological event of unknown origin (12 months earlier, he experienced right arm weakness that resolved spontaneously 3 days after the onset). Moreover, he experienced disorientation, and neurological examination on admission revealed left limb paresis and ataxia. A neuropsychological examination revealed cognitive impairment in memory and visual spatial orientation. A transcranial Doppler ultrasound showed reduced cerebrovascular reactivity to changes in partial CO₂ pressure. Magnetic resonance imaging (MRI) of the head showed heterogeneous lesions corresponding to intracranial hemorrhages in the course of amyloid angiopathy (FIGURE 1). Other diagnostic procedures did not reveal any

neurological symptoms or abnormalities. A preliminary diagnosis of cerebral amyloid angiopathy (CAA) according to the Boston criteria¹ was established, and the patient was transferred to the Department of Internal Medicine for further diagnostic workup. A biopsy of oral and rectum mucosa was nonspecific; however, a biopsy of the abdominal fat tissue suggested amyloid deposits. Serum immunofixation revealed an abnormal ratio of lambda and kappa light chains. Scintigraphy with ¹²³I-labeled serum amyloid P component (SAP) showed abnormal SAP levels in the kidney. The patient was diagnosed with amyloidosis and treated with bortezomib.

The term "amyloidosis" is used to describe hyaline eosinophilic extracellular deposits in various tissues. The clinical presentation is nonspecific and may vary depending on the site of deposition. Neurological involvement is observed in about 20% of the cases, and the median duration of neuropathic symptoms before the diagnosis of amyloidosis is 2 years.² CAA is a cerebrovascular

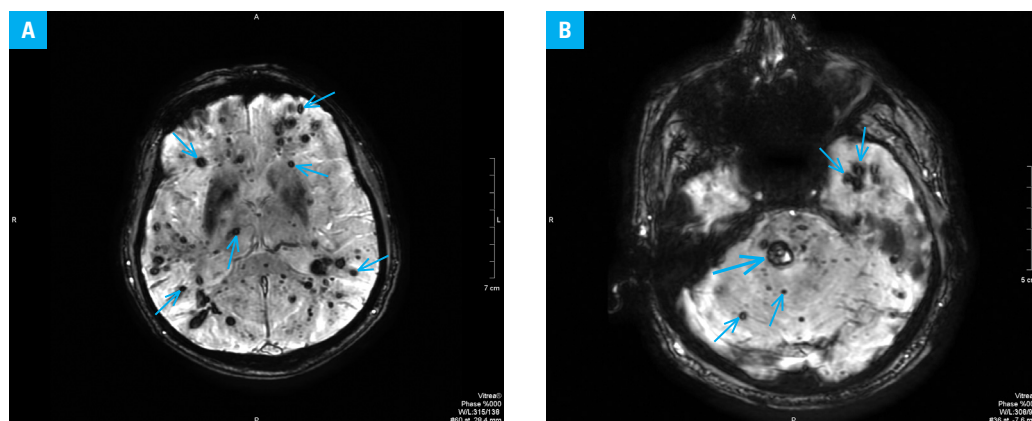


FIGURE 1 **A** – numerous low-signal intensity foci representing multiple old microhemorrhages (small arrows); **B** – numerous low-signal intensity foci representing disseminated old microhemorrhages (large arrow, subacute hemorrhage; small arrows, foci of old microhemorrhages)

Correspondence to:

Anetta Lasek-Bal, MD, PhD, Oddział Neurologii, Samodzielny Publiczny Szpital Kliniczny Nr 7, Śląski Uniwersytet Medyczny, Górnośląskie Centrum Medyczne im. Prof. Leszka Gieca, ul. Ziłowa 45/47, Katowice, Poland, phone: +48-32-359-83-06, fax: +48-32-202-95-92, e-mail: alasek@gcm.pl

Received: January 19, 2014.

Revision accepted:

January 23, 2014.

Published online: January 24, 2014.

Conflict of interest: none declared.

Pol Arch Med Wewn. 2014;

124 (3): 138-140

Copyright by Medycyna Praktyczna,

Kraków 2014

disease in which amyloid is deposited in the leptomeningeal, cortical, and subcortical arteries as well as in the capillaries. Most individuals with CAA are asymptomatic but they can present cognitive impairment and other neurological deficits caused by vascular wall amyloid deposition leading to hemorrhage.³ Amyloidosis results in intracranial hemorrhages in 15% to 20% of the patients aged over 60 years.⁴ An MRI scan of the hemorrhages in patients with CAA needs to be differentiated with hemorrhages due to hypertension, brain changes in posterior reversible encephalopathy syndrome, or, rarely, hemorrhagic metastases.

In our case, which is quite unique, amyloidosis initially occurred in the central nervous system without systemic manifestation. Cognitive deterioration, left limb weakness, and previously undiagnosed neurological symptoms were caused by amyloid pathology in the central nervous system. MRI of the head suggested CAA as the main etiology of the hemorrhage, which prompted further investigation. Of note, we did not observe neuropathy, which is the most characteristic neurological symptom of amyloidosis. The final diagnosis was based on abdominal fat biopsy and SAP scintigraphy, which allowed to initiate treatment before systemic manifestations of amyloidosis occurred.

REFERENCES

- 1 Renard D, Castelnovo G, Wacogne A, et al. Interest of CSF biomarker analysis in possible cerebral amyloid angiopathy cases defined by the modified Boston criteria. *J Neurol*. 2012; 259: 2429-2433.
- 2 Viswanathan A, Greenberg SM. Cerebral amyloid angiopathy in the elderly. *Ann Neurol*. 2011; 70: 871-880.
- 3 Skeik N, Porten BR, Delgado Almandoz JE, et al. A unique case report of cerebral amyloid angiopathy with literature review. *Ann Vasc Surg*. 2013. doi: 10.1016/j.avsg.2013.12.001.
- 4 Salzman K. Stroke. In: *Diagnostic Imaging: Brain*. Osborn A, ed. Salt Lake City, Utah: Amirsys Publishing, Inc.; 2010: 172-175.