

## Patient report

Ahmet Anık, Gönül Çatlı, Ayhan Abacı, Uluc Yiş, Hale Ören, Handan Güleriyüz, Sefa Kızıldağ and Ece Böber\*

# A novel activating *ABCC8* mutation underlying neonatal diabetes mellitus in an infant presenting with cerebral sinovenous thrombosis

**Abstract:** Neonatal diabetes mellitus is a rare clinical condition, which develops most commonly secondary to mutations in *KCNJ11* and *ABCC8* genes encoding ATP-sensitive K<sup>+</sup> channels. Patients are typically diagnosed with hyperglycemia-related symptoms in the first 6 months of life and rarely with ketoacidosis. In this article, we report an infant who presented with focal clonic convulsion and thereafter was diagnosed with neonatal diabetes mellitus and thrombi in cerebral venous sinus. In this patient, after a molecular analysis of the *ABCC8* gene revealed a novel heterozygous missense mutation (p.D424V), a successful transition from insulin to sulfonyleurea treatment was made.

**Keywords:** *ABCC8* gene; cerebral venous sinus thrombosis; neonatal diabetes mellitus.

\*Corresponding author: **Ece Böber**, MD, Professor, Division of Pediatric Endocrinology, Department of Pediatrics, Faculty of Medicine, Dokuz Eylül University, Balçova-Izmir, 35340 Turkey, Phone: +90 232 4126076, Fax: +90 232 4126001, E-mail: ece.bober@deu.edu.tr

**Ahmet Anık, Gönül Çatlı and Ayhan Abacı:** Division of Pediatric Endocrinology, Department of Pediatrics, Faculty of Medicine, Dokuz Eylül University, Izmir, Turkey

**Uluc Yiş:** Division of Pediatric Neurology, Department of Pediatrics, Faculty of Medicine, Dokuz Eylül University, Izmir, Turkey

**Hale Ören:** Division of Pediatric Hematology and Oncology, Department of Pediatrics, Faculty of Medicine, Dokuz Eylül University, Izmir, Turkey

**Handan Güleriyüz:** Division of Pediatric Radiology, Department of Radiology, Faculty of Medicine, Dokuz Eylül University, Izmir, Turkey

**Sefa Kızıldağ:** Division of Medical Biology and Genetics, Faculty of Medicine, Dokuz Eylül University, Izmir, Turkey

## Introduction

Neonatal diabetes mellitus (NDM) is a monogenic disease, which is encountered with hyperglycemia in the first 6 months of life and has an incidence of 1:260,000 (1). NDM can be permanent (PNDM) or transient (TNDM). PNDM is encountered most commonly by mutations in the *KCNJ11* and *ABCC8* genes coding ATP-sensitive K<sup>+</sup> (K<sub>ATP</sub>) channels in pancreatic β cells, and TNDM develops frequently as a result of paternal uniparental disomy of chromosome 6q24 (2).

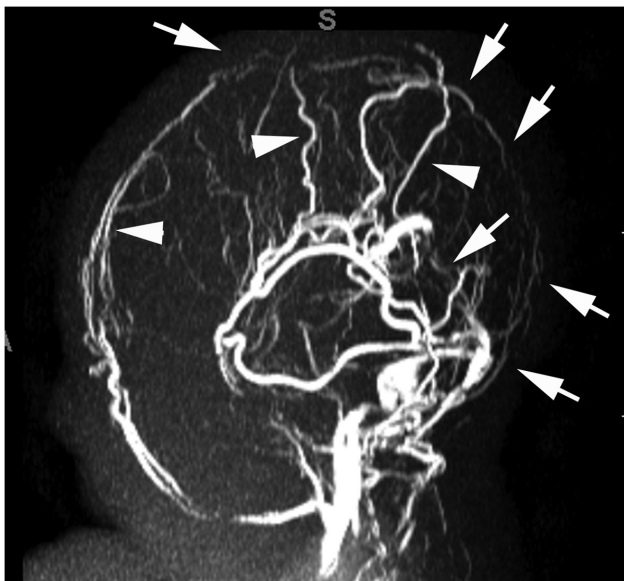Diabetic ketoacidosis (DKA) may develop in some patients at the time of diagnosis (3, 4). Hyperglycemia and ketoacidosis result in a tendency for thrombosis in patients with diabetes mellitus (5). However, cerebral venous sinus thrombosis (CVST) has not been reported in diabetic neonates and infants in the absence of ketoacidosis (non-DKA). In this article, the case of an infant who was admitted with focal convulsion and diagnosed with non-DKA NDM and CVST is presented. Molecular analysis of the patient revealed a novel heterozygous missense mutation [p.Asp424Val (p.D424V)] in the *ABCC8* gene.

## Case report

A 2-month-old male infant presented to the emergency department with a focal clonic seizure in his right arm lasting for 2 min, which then recovered spontaneously. He had no other complaints despite a venous glucose level of 722 mg/dL. His medical history revealed that he was born at term by cesarean section after an uneventful pregnancy, with a birth weight of 2450 g, and he was on breastfeeding. There was no consanguinity between the parents, and no history of diabetes in the family as well. On physical examination, his weight

was 4500 g (−0.57 SDS), height was 57 cm (0.15 SDS), and head circumference was 39 cm (−0.13 SDS). He was conscious and active with findings of mild dehydration, such as dry mouth and tongue, but no other pathologic finding in the physical examination. Laboratory analysis revealed normal complete blood count (hemoglobin 10.8 g/dL, hematocrit 32.2%), blood chemistry (BUN 9 g/dL, creatinine 0.6 mg/dL, AST 15 U/L, ALT 30 U/L), electrolyte levels and hyperglycemia without acidosis (pH 7.39, pCO<sub>2</sub> 39 mm Hg and HCO<sub>3</sub> 24 mmol/L). Urine dipstick analysis showed glycosuria without ketonuria. At the time of diagnosis, HbA<sub>1c</sub> was 7.7% (60.6 mmol/mol) (normal value <6%), insulin was 3.3 μIU/mL and C-peptide was 1.07 ng/mL (normal value 0.9–7.1 ng/mL). Treatment was started with intravenous regular insulin (0.05 IU/kg per hour) and a rehydration solution.

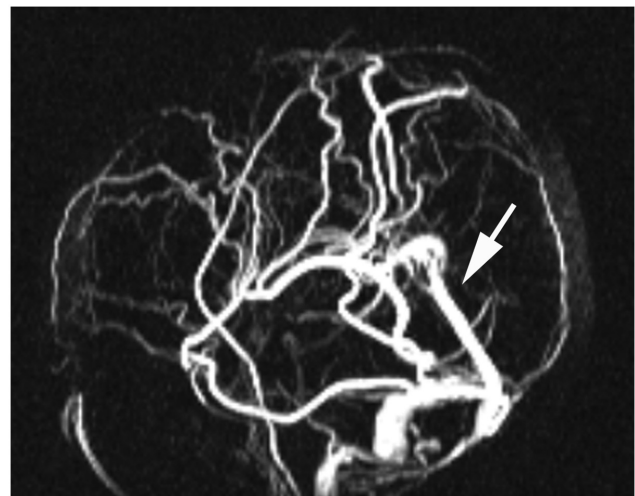
Due to the focal onset of secondary generalized seizures, phenytoin was initiated, and then as the seizures continued phenobarbital was added. In brain computed tomography scan, an image with increased density in the straight sinus, which might be consistent with thrombosis, was detected, and brain magnetic resonance imaging (MRI) revealed signs of diffusion limitation and ischemia. In the MRI venography, the patient had thrombosis in the superior sagittal sinus, right lateral sinus and sinus rectus with normal and patent cerebral arteries (Figure 1). In the electroencephalography (EEG), frequent and asynchronous sharp and spike wave discharges, which were originating from different



**Figure 1** Sagittal view of an MR venography minimum intensity projection (MIP) image showing thrombosis of the superficial and deep dural venous sinuses (arrows) and collateral veins (arrowheads).

localizations of both hemispheres, were detected. On the second day of follow-up, the patient was switched to oral feeding and normoglycemia was maintained by subcutaneous neutral protamine Hagedorn insulin injections (0.4 IU/kg per day) in three divided doses. Because of the cerebral sinus thrombosis, subcutaneous enoxaparin injections of 1.5 mg/kg per dose 12 hourly were started. Results of the laboratory tests performed to rule out hereditary thrombophilia (active protein C resistance, prothrombin mutation, antithrombin activity, von Willebrand factor antigen, protein C, protein S and homocysteine level, lupus anticoagulant, factor V and VIII levels, anticardiolipin IgM and IgG) were within normal limits. Results of his coagulation tests were within normal limits, except a high D-dimer level (3.4 mg/L, normal value <0.5 mg/L). Abdominal MRI showed a normal image of the pancreas. In the control MRI venography performed on the seventh day of enoxaparin treatment, no sign of regression was observed and enoxaparin was continued. Two weeks after the presentation to the emergency department, a repeat EEG revealed normal findings. After the first month of enoxaparin treatment, repeat MR venography demonstrated the recanalization of the left lateral sinus and straight sinus, but the superior sagittal sinus and right lateral sinus were seen as still thrombosed (Figure 2). Enoxaparin treatment was continued with a single dose of 1.5 mg/kg.

The patient was re-evaluated for transition to sulfonylurea after the genetic diagnosis of NDM due to *ABCC8* mutation was made. He was on insulin treatment with a dose of 0.4 IU/kg per day, and baseline HbA<sub>1c</sub> and fasting C-peptide levels were 6.5% and 1.54 ng/mL, respectively.



**Figure 2** Sagittal view of a first month MR venography MIP image showing recanalization of the straight sinus (arrow) and already thrombosed sagittal dural venous sinuses.

Glibenclamide was gradually stepped up from 0.05 mg/kg per day, and insulin was totally tailed off after 4 days of glibenclamide treatment. In the first month of the treatment, the patient became normoglycemic with a glibenclamide dose of 0.1 mg/kg per day and his HbA<sub>1c</sub> level was 5.6% (37.6 mmol/mol).

## Molecular genetic analysis

To investigate the etiology of the proband's neonatal diabetes, after obtaining informed consent from the parents, genomic DNA from peripheral blood leukocytes was extracted from the index patient and her parents using standard methods.

The coding regions and intron/exon boundaries of the *ABCC8*, *KCNJ11* and *INS* genes were amplified by polymerase chain reaction (primers available on request). Single-strand sequencing was carried out using standard methods on an ABI3730 capillary sequencer (Applied Biosystems, Warrington, UK), and sequences were compared with published sequences (NM\_000352.2, NM\_000525 and NM\_000207.2) using the Mutation Surveyor software v. 3.24 (SoftGenetics, State College, PA, USA).

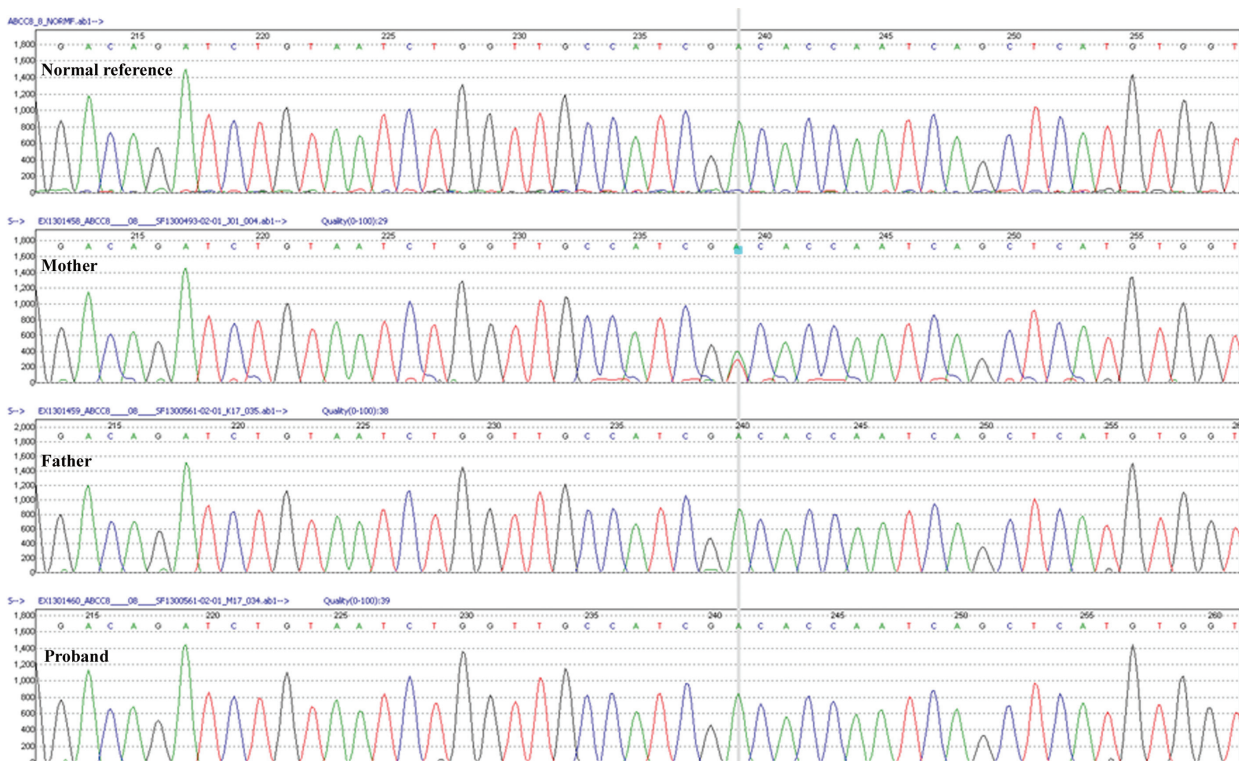
## Results

A novel heterozygous missense mutation p.D424V (c.1271A>T) was identified in the proband's *ABCC8* gene (Figure 3). This aspartic acid residue at codon 424 is conserved across species, and mutation testing in the parents has shown that the p.D424V mutation has arisen de novo.

## Discussion

Neonatal diabetes mellitus (NDM) patients generally present with intrauterine growth retardation, hyperglycemia, glycosuria, osmotic polyuria, severe dehydration, failure to thrive and, less frequently, ketoacidosis (3, 4). The most important cause of neurological deterioration in cases with diabetes mellitus is brain edema, which develops secondary to DKA. Rosenbloom (6) reported that, in 10% of DKA patients, neurological deterioration developed with cerebral complications other than brain edema, such as cerebral thrombosis, central nervous system infections or hemorrhages.

Although it is known that hyperglycemia causes a tendency to thrombosis (7), as far as we know, CVST



**Figure 3** Electropherograms showing the heterozygous *ABCC8* mutations identified in the proband. A black arrow point to the c.1271A>T mutation, which results in the substitution of valine by aspartic acid at codon 424 (p.D424V). The parents do not carry the p.D424V *ABCC8* mutation.

development has not been reported until this time in NDM patients without ketoacidosis. Various mechanisms have been proposed for hypercoagulability in non-DKA in type 1 and type 2 DM. It has been proposed that the prothrombotic state in type 2 DM might be related to decreased endogenous fibrinolysis activity secondary to increased plasminogen activator inhibitor-1 level (8). Romano et al. (9) showed endothelial dysfunction in newly diagnosed type 1 DM (T1DM) children and adolescents, as reflected by the high circulating levels of von Willebrand factor and tissue-plasminogen activator. Similarly, it was reported that thrombin-antithrombin complex, prothrombin fragment 1+2, plasminogen factor VII coagulation activity and D-dimer levels were increased in T1DM patients with microvascular complications (10, 11). Rodrigues et al. (12) reported that fibrinogen levels were higher in adult T1DM patients. In addition, systemic inflammation in DM patients may be another contributing factor for platelet reactivity (5), and increased plasma levels of inflammatory mediators (CD40 ligand, tumor necrosis factor- $\alpha$  and C-reactive protein) have been found in T1DM patients (9, 13). Acute hyperglycemia in non-diabetic individuals may also activate the coagulation system by increased factor VII activity, thrombin-antithrombin complex and soluble tissue factor levels (14). CVST has been rarely reported in the newborn period and early infancy, and antenatal risk factors (preeclampsia, maternal diabetes mellitus, chorioamnionitis) and acute systemic diseases of the patients (sepsis, dehydration, asphyxia, meningitis, cardiac defects) are detected in the etiology of patients, which present particularly in the newborn period (15). It is also known that, apart from these factors, prothrombotic aberrations can increase the tendency for CVST (16–18). CVST is a multifactorial disease, which, in many of cases, manifests as a result of prothrombotic risk factors with the underlying disease (15). American College of Chest Physicians Evidence-Based Clinical Practice Guidelines recommend at least 3 months' anticoagulation treatment in children with CVST by using unfractionated heparin or low-molecular-weight heparin (LMWH) (19). Although thrombosis and neonatal diabetes might also be present coincidentally, the exclusion of antenatal risk factors and the elimination of hereditary thrombophilia etiologies has given rise to the idea that, in this case, cerebral venous sinus thrombosis might be associated with hypercoagulability related to hyperglycemia. Treatment was started at

a dose of 1.5 mg/kg 12 hourly LMWH (enoxaparin) for 10 days, and then the dose was decreased to 1.5 mg/kg once a day.

While 70% of TNDM patients have genetic and epigenetic aberrations at the TNDM locus on chromosome 6q24, causing an overexpression of two imprinted genes, *PLAGL1/ZAC* (pleiomorphic adenoma gene-like 1/zinc finger protein that regulates apoptosis and cell cycle arrest) and *HYMAI* (hydantidiform mole-associated and imprinted transcript), the most common causes of PNDM are heterozygous activating mutations in the *KCNJ11* (OMIM 601374) and *ABCC8* (OMIM 600509) genes, which encode the KIR6.2 and SUR1 subunits of the  $K_{ATP}$  channel (2, 20). *ABCC8* is a large 39-exon gene encoding a 1582 amino acid protein and, currently, approximately 50 different *ABCC8* activating mutations leading to NDM have been defined. Although those mutations may be inherited dominantly or recessively, approximately 50% of them develop de novo (20). In the present case, the heterozygous missense mutation determined in the *ABCC8* gene is a de novo mutation. The vast majority of channelopathies respond well to sulfonylurea treatment (21). Rafiq et al. (22) were able to successfully switch to sulfonylurea treatment in 23 (85%) of 27 cases with *ABCC8* mutation. In the present case, a novel heterozygote p.D424V mutation was defined, and successful switching from insulin to sulfonylurea treatment was performed. As it has responded to sulfonylurea treatment, it is therefore likely that the p.D424V mutation is pathogenic. However, the gold standard method, functional characterization of the mutation in the gene, could not be performed.

In conclusion, despite the absence of DKA, in patients with NDM, hyperglycemia may result in CVST.  $K_{ATP}$  channel mutations are the most frequent causes of NDM, especially in PNDM, and should be investigated in NDM cases by performing molecular analysis, and transition to sulfonylurea treatment is usually successful in these patients.

**Acknowledgments:** Genetic testing was provided by the Molecular Genetics Laboratory at the University of Exeter Medical School with funding from the Wellcome Trust to Professors Andrew Hattersley and Sian Ellard (<http://www.diabetesgenes.org>).

Received June 28, 2013; accepted November 22, 2013; previously published online January 27, 2014

## References

1. Slingerland AS, Shields BM, Flanagan SE, Bruining GJ, Noordam K, et al. Referral rates for diagnostic testing support an incidence of permanent neonatal diabetes in three European countries of at least 1 in 260,000 live births. *Diabetologia* 2009;52:1683–5.
2. Greeley SA, Tucker SE, Naylor RN, Bell GI, Philipson LH. Neonatal diabetes mellitus: a model for personalized medicine. *Trends Endocrinol Metab* 2010;21:464–72.
3. Abacı A, Razi CH, Ozdemir O, Hızlı S, Kışlal F, et al. Neonatal diabetes mellitus accompanied by diabetic ketoacidosis and mimicking neonatal sepsis: a case report. *J Clin Res Pediatr Endocrinol* 2010;2:131–3.
4. Polak M, Cave H. Neonatal diabetes mellitus: a disease linked to multiple mechanisms. *Orphanet J Rare Dis* 2007;2:12.
5. Vazzana N, Ranalli P, Cuccurullo C, Davi G. Diabetes mellitus and thrombosis. *Thromb Res* 2012;129:371–7.
6. Rosenbloom AL. Intracerebral crises during treatment of diabetic ketoacidosis. *Diabetes Care* 1990;13:22–33.
7. Funk SD, Yurdagul A Jr., Orr AW. Hyperglycemia and endothelial dysfunction in atherosclerosis: lessons from type 1 diabetes. *Int J Vasc Med* 2012;2012:569654.
8. Nordt TK, Bode C. Impaired endogenous fibrinolysis in diabetes mellitus: mechanisms and therapeutic approaches. *Semin Thromb Hemost* 2000;26:495–501.
9. Romano M, Pomilio M, Vigneri S, Falco A, Chiesa PL, et al. Endothelial perturbation in children and adolescents with type 1 diabetes: association with markers of the inflammatory reaction. *Diabetes Care* 2001;24:1674–8.
10. Giusti C, Schiaffini R, Brufani C, Pantaleo A, Vingolo EM, et al. Coagulation pathways and diabetic retinopathy: abnormal modulation in a selected group of insulin dependent diabetic patients. *Br J Ophthalmol* 2000;84:591–5.
11. Reverter JL, Reverter JC, Tassies D, Rius F, Monteagudo J, et al. Thrombomodulin and induced tissue factor expression on monocytes as markers of diabetic microangiopathy: a prospective study on hemostasis and lipoproteins in insulin-dependent diabetes mellitus. *Am J Hematol* 1997;56:93–9.
12. Rodrigues TC, Snell-Bergeon JK, Maahs DM, Kinney GL, Rewers M. Higher fibrinogen levels predict progression of coronary artery calcification in adults with type 1 diabetes. *Atherosclerosis* 2010;210:671–3.
13. Santilli F, Basili S, Ferroni P, Davi G. CD40/CD40L system and vascular disease. *Intern Emerg Med* 2007;2:256–68.
14. Lemkes BA, Hermanides J, Devries JH, Holleman F, Meijers JC, et al. Hyperglycemia: a prothrombotic factor? *J Thromb Haemost* 2010;8:1663–9.
15. Yang JY, Chan AK, Callen DJ, Paes BA. Neonatal cerebral sinovenous thrombosis: sifting the evidence for a diagnostic plan and treatment strategy. *Pediatrics* 2010;126:e693–700.
16. deVeber G, Monagle P, Chan A, MacGregor D, Curtis R, et al. Prothrombotic disorders in infants and children with cerebral thromboembolism. *Arch Neurol* 1998;55:1539–43.
17. deVeber G, Andrew M, Adams C, Bjornson B, Booth F, et al. Cerebral sinovenous thrombosis in children. *N Engl J Med* 2001;345:417–23.
18. Heller C, Heinecke A, Junker R, Knofler R, Kosch A, et al. Cerebral venous thrombosis in children: a multifactorial origin. *Circulation* 2003;108:1362–7.
19. Monagle P, Chalmers E, Chan A, deVeber G, Kirkham F, et al. Antithrombotic therapy in neonates and children: American College of Chest Physicians Evidence-Based Clinical Practice Guidelines (8th edition). *Chest* 2008;133:887S–968S.
20. Edghill EL, Flanagan SE, Ellard S. Permanent neonatal diabetes due to activating mutations in *ABCC8* and *KCNJ11*. *Rev Endocr Metab Disord* 2010;11:193–8.
21. Rubio-Cabezas O, Klupa T, Malecki MT. Permanent neonatal diabetes mellitus – the importance of diabetes differential diagnosis in neonates and infants. *Eur J Clin Invest* 2011;41:323–33.
22. Rafiq M, Flanagan SE, Patch AM, Shields BM, Ellard S, et al. Effective treatment with oral sulfonylureas in patients with diabetes due to sulfonylurea receptor 1 (*SUR1*) mutations. *Diabetes Care* 2008;31:204–9.