

Modified target cancellation in hemispatial neglect

Sashank Prasad, Aaron L Berkowitz

► The supplementary video to this paper is available online. To watch it please visit the journal online (<http://dx.doi.org/10.1136/practneurol-2013-000799>).

Department of Neurology, Brigham and Women's Hospital, Harvard Medical School, Boston, Massachusetts, USA

Correspondence to

Dr Aaron L Berkowitz, Department of Neurology, Brigham and Women's Hospital, 75 Francis Street, Boston, MA 02115, USA; aberowitz3@partners.org

Published Online First
27 January 2014

A 70-year-old woman developed left hemispatial neglect following a right parietal haemorrhage (figure 1A). On a standard target cancellation task, she neglected 6/10 left-sided stimuli (figure 1B,C and see online supplementary video). However, on a modified target cancellation task (erasing targets rather than crossing them out), she neglected only 3/10 stimuli (figure 1D,E and see online supplementary video). In the modified target cancellation task, stimuli are removed from ipsilesional space, facilitating detection of those stimuli remaining in contralesional space.¹ Together, these tasks provide evidence that hemispatial neglect phenomena arise from both impaired deployment of attention towards contralesional space and impaired ability to disengage attention from ipsilesional space.²

Contributors Both authors contributed to the conception, drafting and revision of the manuscript, and approved the final submitted version for publication.

Competing interests AB receives royalties from Clinical Pathophysiology Made Ridiculously Simple (Medmaster, Inc) and The Improvising Mind (Oxford University Press).

Patient consent Obtained.

Provenance and peer review Not commissioned; externally peer reviewed.

REFERENCES

- 1 Mark VW, Kooistra CA, Heilman KM. Hemispatial neglect affected by non-neglected stimuli. *Neurology* 1988;38:1207–12011.
- 2 Posner MI, Walker JA, Friedrich FJ, *et al*. Effects of parietal injury on covert orienting of attention. *J Neurosci* 1984;4:1863–74.

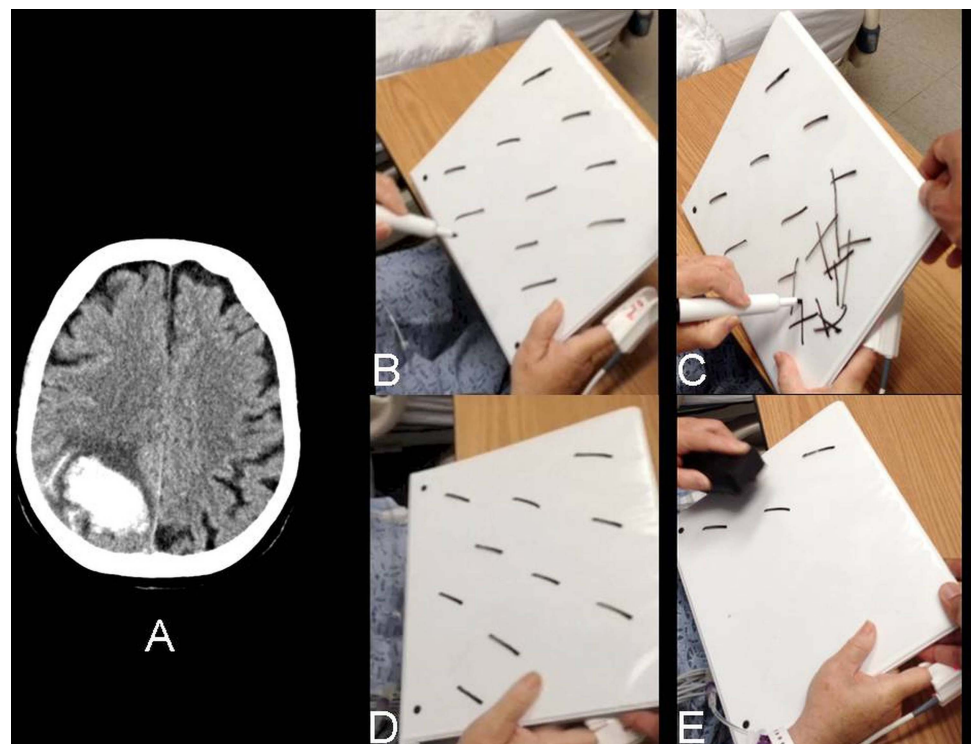


Figure 1 Standard and modified target cancellation tasks in hemispatial neglect. (A) CT scan of head showing a right parietal haemorrhage. (B, C) Standard target cancellation task. (D, E) Modified target cancellation task, in which the patient erases each line that is detected. See the online supplementary video. Used with permission from Modern Neurology.



To cite: Prasad S, Berkowitz AL. *Pract Neurol* 2014;14:277.