

of small bowel showed several serosal granulomas containing fragments of refractile plastic, which were also identified as polypropylene. Granulomas containing identical polypropylene material were also present in the hepatic capsule. Starch granules, possibly derived from glove powder, were found in the granulomas at both sites. No granulomas were found in sections from other organs.

Comment

This child died from the sequelae of small bowel infarction. There was unequivocal histopathological evidence of embolism caused by plastic splinters restricted to tissue supplied by the coeliac axis. Furthermore, the syringe used to perfuse the umbilical artery catheter was made from material identical with that found in the emboli, showing a causal association. This is supported by the finding that after insertion of umbilical artery catheters neonates who died of necrotising enterocolitis had higher levels of plasticiser in their bowels than similar infants dying from other causes.² If a repetition of this tragedy is to be avoided manufacturers must make greater efforts to minimise particulate contamination and the use of filters in intravenous lines should be considered.

We thank Professor D A Long of the molecular spectroscopy unit, University of Bradford, for performing the laser raman spectroscopy.

- 1 Backhouse CM, McCullum C. Particles in PT: cause for concern? *British Journal of Parenteral Therapy* 1986;7:136-43.
- 2 Hillman LS, Goodwin SL, Sherman WR. Identification of plasticizers in neonatal tissues after umbilical artery catheters and blood products. *N Engl J Med* 1975;292:381-6.

(Accepted 9 December 1987)

Royal Sussex County Hospital, Brighton BN2 5BE

A J CANT MD, MRCP, paediatric registrar, Trevor Mann Baby Unit
W LENNEY, MD, MRCP, consultant paediatrician, Trevor Mann Baby Unit
N KIRKHAM, MRCPATH, consultant pathologist

Cranial diabetes insipidus after upper gastrointestinal haemorrhage

Isolated impairment of posterior pituitary function with normal anterior pituitary function after haemorrhagic shock is most unusual but has been reported in obstetric patients. We describe a patient who developed cranial diabetes insipidus after a profound gastrointestinal haemorrhage.

Case report

A previously well, asymptomatic 65 year old man was admitted with haematemesis of acute onset after two days of melaena. He was not taking any drugs and denied taking alcohol. He was drowsy, pale, and shocked with a pulse of 120/min and systolic blood pressure of 80 mm Hg. Haemoglobin concentration was 54 g/l, but blood urea and glucose and serum electrolyte and calcium concentrations were normal. He was given three units of whole blood and 4% dextrose-saline one litre 12 hourly. Two hours after admission his systolic blood pressure was 100 mm Hg; thereafter it was maintained above 100 mm Hg. Gastroscopy showed a gastric ulcer, which was shown to be benign on histological examination of mucosal biopsy specimens.

Twenty four hours later he was haemodynamically stable but confused and dehydrated; nasogastric aspirate was free of blood. Urine output was more than three litres in the first 24 hours and six litres in the next 12 hours. He complained of severe thirst. His serum sodium concentration had risen to 170 mmol/l and chloride concentration to 115 mmol/l. Blood urea concentration was 6.5 mmol/l, potassium 4.9 mmol/l, and glucose 5.9 mmol/l and serum calcium 2.1 mmol/l. Serum osmolality was 340 mmol/kg and urine osmolality 150 mmol/kg. Diabetes insipidus was diagnosed, and desmopressin 20 µg administered intranasally caused a prompt reduction in urine output with a sharp rise in urine osmolality to 620 mmol/kg. With continued use of desmopressin 10 µg twice daily, all his symptoms, including complaints of thirst subsided, serum electrolyte concentrations and osmolality returned to normal. Repeat endoscopy six weeks later showed that the ulcer had healed completely. Radiographs of the chest and skull, results of visual perimetry, and computed tomograms of the head were normal. Anterior pituitary function was normal: serum free thyroxine concentration 12 pmol/l (normal range 8.2-24.0 pmol/l), serum prolactin 172-300 mIU/l (normal range <460 mIU/l), plasma cortisol 395 nmol/l at 0900 and 200 nmol/l at 2400, urinary free cortisol 210 nmol/24 h (normal range 100-370 nmol), and random growth hormone 4.2-19 mU/l (normal stimulated value >15 mU/l). Stimulation of the anterior pituitary gland by thyrotrophin releasing hormone and luteinising hormone releasing hormone yielded normal responses.

The patient continued taking desmopressin and remained symptomatic with normal serum electrolyte concentrations. Two years later anterior pituitary function was normal, but an eight hour water deprivation test showed failure to concentrate urine: urine osmolality was 289 mmol/kg and serum osmolality 299 mmol/kg, associated with a weight loss of 1.6 kg (2.9% of body weight). Plasma immunoreactive vasopressin was undetectable (<0.3 pmol/l) after eight hours.¹ Administration of desmopressin 2 µg intramuscularly caused a prompt rise of urine osmolality to 795 mmol/kg, confirming the diagnosis of cranial diabetes insipidus.

Comment

This patient showed persistent partial cranial diabetes insipidus without any clinical or biochemical evidence of dysfunction of the anterior pituitary gland. The abnormality clearly developed immediately after his haematemesis, when he was hypotensive. We were unable to find any cause for the diabetes insipidus other than hypovolaemic hypotension. Cranial diabetes insipidus has been reported after postpartum haemorrhage, temporarily after coronary artery bypass surgery, and after cardiorespiratory arrest.^{2,5} To our knowledge no case of persistent disease has been reported after haemorrhagic shock other than severe postpartum haemorrhage. Our patient's abnormality probably resulted from selective neuronal damage in the supraoptic and paraventricular areas of the hypothalamus while he was hypotensive. Hypernatraemia, polyuria, and intense thirst should alert clinicians to the possibility of cranial diabetes insipidus after haemorrhagic shock.

- 1 Rooke P, Baylis PH. A new sensitive radioimmunoassay for plasma arginine vasopressin. *J Immunol* 1982;3:115-31.
- 2 Collins ML, O'Brien P, Cline A. Diabetes insipidus following obstetric shock. *Obstet Gynecol* 1979;53(suppl):16-7S.
- 3 Baylis PH, Milles JJ, London DR, Butt WR. Postpartum cranial diabetes insipidus. *Br Med J* 1980;280:20.
- 4 Kuan P, Messenger JC, Ellestad MH. Transient central diabetes insipidus after aortocoronary bypass operations. *Am J Cardiol* 1983;52:1181-3.
- 5 Rothschild M, Shinkman L. Diabetes insipidus following cardiorespiratory arrest. *JAMA* 1977;238:620-1.

(Accepted 9 December 1987)

Sunderland District General Hospital, Sunderland SR4 7TP

L S P WICKRAMASINGHE, MRCP, DGM, senior registrar, department of medicine for the elderly and general medicine
B I CHAZAN, MD, FRCP, consultant physician, department of medicine and endocrinology
A R MANDAL, FRCP, consultant physician, department of medicine for the elderly

Department of Medicine, University of Newcastle upon Tyne, Newcastle upon Tyne NE1 7RU

P H BAYLIS, MD, FRCP, reader in endocrinology

Department of Medicine for the Elderly, Ryhope General Hospital, Sunderland SR2 01Y

IAIN RUSSELL, MB, CHB, senior house officer

Correspondence to: Dr Wickramasinghe.

Increasing doses of naloxone hydrochloride by infusion to treat pain due to the thalamic syndrome

The opioid antagonist naloxone hydrochloride has been used for several years to treat pain resulting from the thalamic syndrome with variable results.¹ We describe two cases in which previous treatments had failed and a course of naloxone infusions at weekly intervals, during which the dose was steadily increased, successfully relieved pain for up to six months.

Patients, methods, and results

In this unit a series of weekly naloxone infusions was offered to outpatients with the thalamic syndrome. At each infusion the dose was increased by 0.4 mg or 0.8 mg until roughly 12 mg was reached, and this dose was given for a further two weeks. The naloxone was added to 500 ml of compound sodium lactate (Hartmann's solution) and given intravenous infusion over three hours into a peripheral vein. Electrocardiograms and blood pressure were monitored throughout,^{1,2} although no exceptional changes have been observed in any patient in this district given naloxone for pain relief.

Case 1—A 56 year old man with mild hypertension sustained a cerebrovascular event in 1980 after which he had a mild right facial weakness and mild right hemiparesis. In 1981 he presented to this clinic with shooting pains affecting the right side of his body. He was successfully treated with sodium valproate and amitriptyline for three years. In 1984 the pain recurred and was worse and he also complained of hyperaesthesia of the right side of his body. Treatment with haloperidol and clomipramine was unsuccessful, and a transcutaneous nerve stimulator provided only temporary relief. In January 1985 he started a course of naloxone infusions; this resulted in partial improvement, which was maintained for six months. A second course of infusions gave greater relief for a further six months, and a third course gave him complete relief from pain for another six months. The pain then recurred and he started a fourth course of treatment. Results were equally good.

Case 2—A 49 year old obese woman taking the oral contraceptive pill presented in 1981 with a right hemiparesis. She made a partial recovery but was left with a constant nagging pain in her right arm and leg. After being seen in several departments and by several practitioners she presented to this clinic and started a course of naloxone infusions, which resulted in considerable but not complete improvement during the treatment and for the next four months.

Comment

The thalamic syndrome, first described in 1906,³ is a rare but severely disabling complication of cerebrovascular events. It often produces severe pain, usually dysaesthetic or shooting. Concentrations of endogenous opioids in cerebrospinal fluid are increased in patients with the syndrome, and naloxone is believed to act by antagonising the effect of these opioids, especially in the region of the locus coeruleus.⁴ Single doses of naloxone have been shown to be of great benefit in 54% of patients studied, their effect lasting for from four days to two and a half years.¹ Our cases indicate that increasing both the duration of treatment and the total dose of naloxone improves pain relief but does not increase the duration of the beneficial effect.

1 Budd K. The use of the opiate antagonist naloxone in the treatment of intractable pain. *Neuropeptides* 1985;5:419-22.

2 Cuss FM, Colaco CB, Baron JH. Cardiac arrest after reversal of opiates with naloxone. *Br Med J* 1984;288:363-4.

3 Dejerine J, Roussy G. Le syndrome thalamique. *Rev Neurol (Paris)* 1906;14:521-32.

4 Strahlendorf HK, Strahlendorf JC, Barnes CD. Endorphin mediated inhibition of locus coeruleus neurons. *Brain Res* 1980;191:284-8.

(Accepted 22 December 1987)

Pain Relief Unit, Guest Hospital, Dudley DY1 4SE

D A A RAY, FFARCS, registrar in anaesthetics

Y M A TAI, FFARCS, DOBSTRCOG, consultant anaesthetist

Correspondence to: Dr Tai.

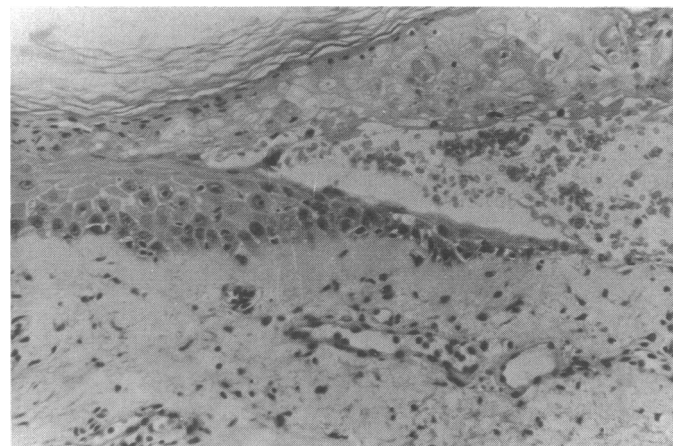
Toxic epidermal necrolysis occurring during treatment with trimethoprim alone

Trimethoprim is increasingly being used to treat infections of the urinary tract. After reports that trimethoprim is as effective and has fewer side effects when used alone as when combined with sulphamethoxazole (as co-trimoxazole) trimethoprim alone has increasingly been used to treat infections of the urinary tract. We report a case of toxic epidermal necrolysis occurring during treatment with trimethoprim alone. To the best of our knowledge this is the first published report of this side effect of this drug.¹

Case report

A 74 year old woman with senile dementia was treated with trimethoprim 200 mg twice daily because of a urinary infection with *Escherichia coli*. She was not taking any other drugs. On the third day of treatment she developed an extensive erythematous eruption. The inflamed skin stripped off to leave large eroded areas, and in other areas there were flaccid blisters. Nickolsky's sign was present. She had severe mucosal ulceration and mild conjunctival inflammation. Apart from recurrent infections of the urinary tract, which had been treated with antibiotics including co-trimoxazole, she had no relevant medical history.

Toxic epidermal necrolysis was suspected, and she was admitted for prophylactic treatment, rehydration, intensive nursing on a continuous fluidisation bed, and analgesia to keep her comfortable. A skin biopsy (figure) confirmed the diagnosis; the specimen showed a subepidermal split and complete necrosis of the separated epidermis, which was invaded by mononuclear cells. A mild



Skin biopsy specimen showing subepidermal split with complete necrosis of separated epidermis and mononuclear dermal infiltrate consistent with toxic epidermal necrolysis.

mononuclear perivascular infiltrate was present in the upper dermis.² Coexistent staphylococcal infection was excluded by culture of blood, urine, stools, and skin swabs. Full blood count, urea and electrolyte concentrations, autoimmune profile, and results of direct and indirect epidermal fluorescence were all normal. Oral steroids were not given; supportive treatment alone resulted in a gradual but complete recovery.

Comment

Toxic epidermal necrolysis was first described in 1956 as a blistering syndrome causing epithelial shearing with its attendant clinical complications.³ It has a mortality of 10-40%.⁴ Many drugs have been implicated as a cause, including sulphonamides, penicillins, derivatives of pyrazolone, and barbiturates. When toxic epidermal necrolysis has occurred with co-trimoxazole the sulphonamide component has been thought responsible. In view of our report some of these cases may have been due to the trimethoprim component of co-trimoxazole. We think that trimethoprim should be added to the list of drugs capable of causing toxic epidermal necrolysis and that doctors should be alerted to this complication, especially as trimethoprim is widely used.

Since we reported this case to the Committee on Safety of Medicines in August 1987 it has received four reports of epidermal necrolysis associated with trimethoprim; whether these were cases of toxic epidermal necrolysis is not known. The manufacturer of the drug used in this case and two other manufacturers have not received any other reports of this complication.

We thank Dr L Temple, consultant histopathologist, for supplying the photomicrograph.

1 Anonymous. Co-trimoxazole or just trimethoprim. *Drug Ther Bull* 1986;24:17-9.

2 Amon RB, Dimond RL. Toxic epidermal necrolysis. Rapid differentiation between staphylococcal and drug-induced disease. *Arch Dermatol* 1975;111:1433-7.

3 Lyell A. Toxic epidermal necrolysis: an eruption resembling scalding of the skin. *Br J Dermatol* 1956;68:355-61.

4 Rasmussen J. Toxic epidermal necrolysis. *Med Clin North Am* 1980;64:901-20.

(Accepted 23 December 1987)

Epsom District Hospital, Epsom, Surrey KT18 7EG

C NWOKOLO, MB, MRCP, medical registrar

L BYRNE, MB, BS, house officer

K J MISCH, MB, MRCP, consultant dermatologist

Correspondence to: Dr Nwokolo.