



## Case Report

# Successful Hybrid Management of Extensive Thromboembolism of the Innominate Trunk, Right Subclavian Artery, Bilateral Common Carotid Artery, and Pulmonary Embolism

*Emiliano Chisci, Leonardo Ercolini, Eugenio Romano, Nicola Troisi, and Stefano Michelagnoli, Florence, Italy*

Symptomatic acute carotid occlusion demands treatment, but the exact treatment to be provided in the case of acute occlusion of 3 supra-aortic vessels is not well established. Herein, we describe the successful emergency hybrid management of a massive thromboembolic occlusion of the right subclavian artery, common carotid artery, and innominate trunk, associated with left arm hemiparesis, motor aphasia, and confusion, and extensive pulmonary embolism. The diagnostic work-up and the hybrid surgical strategy adopted are described. Neurologic symptoms had completely regressed at discharge and the patient was free of any complications at the 3-month follow-up.

Vascular surgeons deal with symptomatic atherosclerotic lesions at the carotid bifurcation, sometimes at the origin of the common carotid artery (CCA), and even tandem lesions, relatively frequently.<sup>1–6</sup> In contrast, thromboembolic occlusion of the supra-aortic vessels is very rare.<sup>7</sup> It is recognized that symptomatic carotid occlusion needs to be treated promptly, although to date there is a lack of consensus regarding techniques and timing.<sup>8–10</sup>

Herein, we report the successful hybrid management of a massive thromboembolic occlusion of 3 of 4 supra-aortic vessels, in a patient presenting to the emergency room (ER) with left arm hemiparesis,

motor aphasia, and confusion. The diagnostic work-up and the surgical strategy adopted are described.

## CASE REPORT

An 84-year-old man was admitted to the ER with acute onset of right arm pain and reduced functioning of the hand, associated with paresthesia lasting 3 hr. The patient's history included hypertensive cardiopathy, dyslipidemia, chronic obstructive pulmonary disease, mild chronic kidney disease, nicotine abuse, and chronic atrial fibrillation. He was taking atenolol, chlorthalidone, allopurinol, and finasteride. Although he had chronic atrial fibrillation, he was not under either anticoagulation or antiplatelet therapy. His clinical examination was remarkable because of the absence of right arm pulses and the spontaneous complete regression of his arm pain and the functional deficit of his hand after admittance to the ER. In the patient's hand paresthesia persisted. An acute right arm cardioembolic ischemia was hypothesized. A few minutes after his initial clinical assessment, the patient suffered from acute onset of left arm hemiparesis, motor aphasia, and confusion (National Institutes of Health Stroke Scale (NIHSS) = 3). A color Doppler ultrasound (CDU) scan revealed complete thrombotic occlusion of the right subclavian artery and the right CCA with a floating thrombus at the level of the bulb. Moreover, the

Department of Surgery, Vascular and Endovascular Surgery Unit, San Giovanni di Dio Hospital, Florence, Italy.

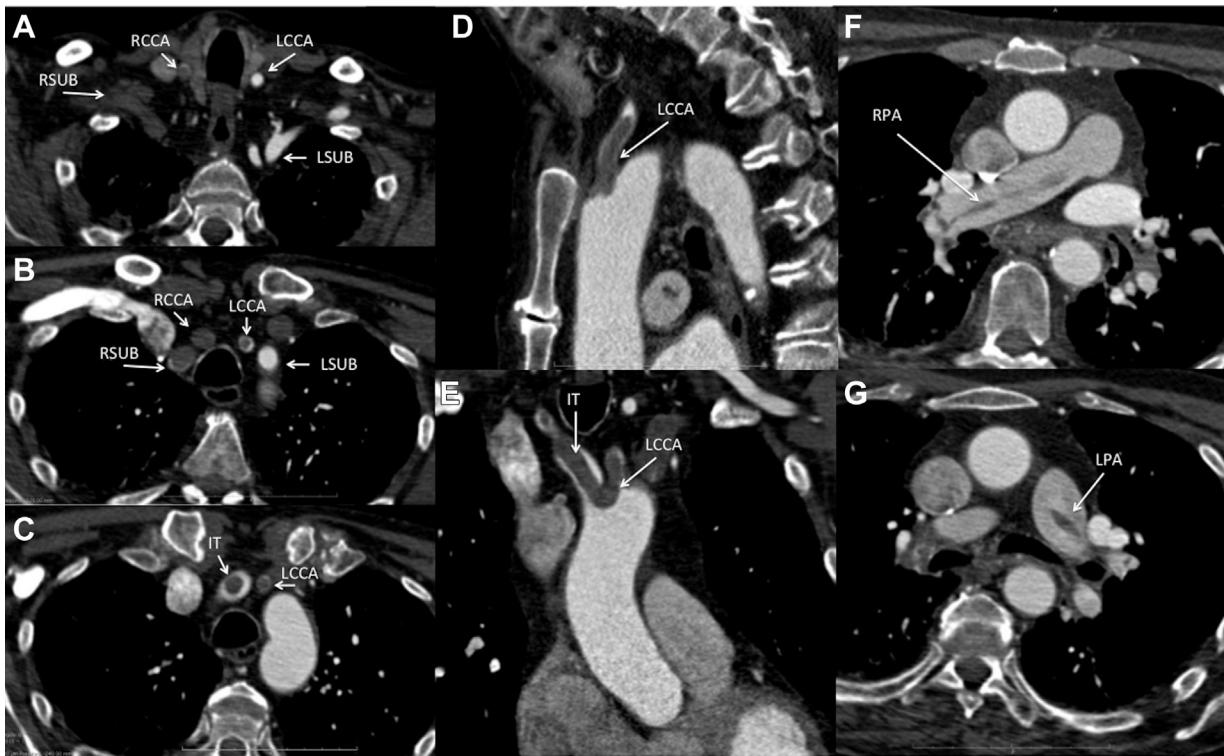
Correspondence to: Emiliano Chisci, MD, Department of Surgery, Vascular and Endovascular Surgery Unit, San Giovanni di Dio Hospital, via Torregalli, 3, 50124 Florence, Italy; E-mail: [emiliano.chisci@asf.toscana.it](mailto:emiliano.chisci@asf.toscana.it)

Ann Vasc Surg 2014; ■: 1–5

<http://dx.doi.org/10.1016/j.avsg.2013.12.035>

© 2014 Elsevier Inc. All rights reserved.

Manuscript received: October 15, 2013; manuscript accepted: December 29, 2013; published online: ■ ■ ■.

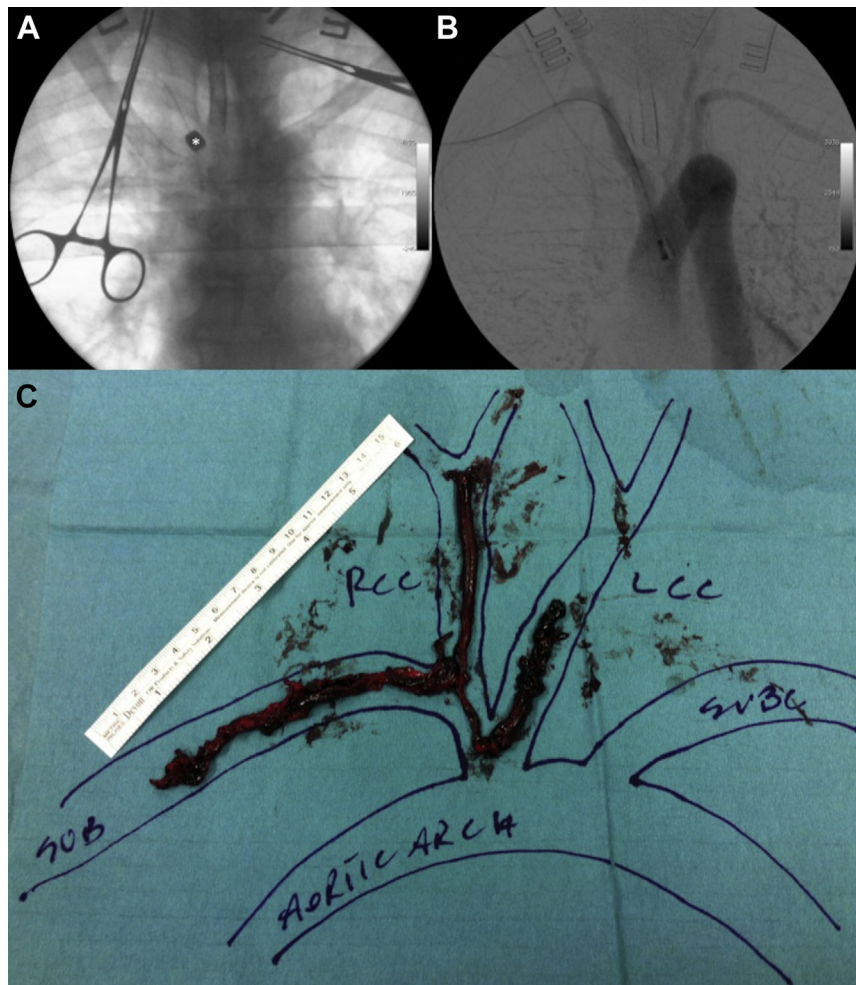


**Fig. 1.** Axial (A–C) and coronal (D–E) computed tomography sections showing extensive thrombus with occlusion of the RSUB, RCCA, IT, and origin of the LCCA, with a patent LSUB. (E) This shows details of the V-occlusion of the LCCA and IT. Large pulmonary

emboli are shown in (F) and (G) (RPA and LPA). IT, innominate trunk; LCCA, left common carotid artery; LPA, left pulmonary artery; LSUB, left subclavian artery; RCCA, right common carotid artery; RPA, right pulmonary artery; RSUB, right subclavian artery.

demodulated (biphasic) flow in the left CCA prompted suspicion of its proximal occlusion. The left subclavian artery was patent. The only direct flow to the brain found at CDU was detected in the left vertebral artery. Occlusive deep vein thrombosis (DVT) of the left popliteal vein was also diagnosed. Immediate intravenous weight-adjusted (70 IU/kg) heparin sodium was started, preceded by a 5000 IU bolus. An emergency computed tomography angiogram (CTA) was necessary to plan therapy. The CTA confirmed the presence of extensive thromboembolism of the innominate trunk, right subclavian artery, and bilateral CCA, as well as concomitant pulmonary embolism (Fig. 1). No recent brain lesions were present. At CTA, the patient had persistent left hemiparesis, while his aphasia and confusion had resolved, giving an improved NIHSS score of 1. The neurologists and vascular surgeons present decided together to operate and surgically remove the huge amount of thrombus from the supra-aortic vessels. The patient consented to the intervention proposed and was therefore taken to an operating theatre equipped with a C-arm for fluoroscopically assisted thromboembolectomy. Surgery commenced 190 min after the time last known well. The procedure consisted of simultaneous surgical exposure of the distal right brachial

artery and both carotid bifurcations by 3 vascular surgeons. The first thromboembolectomy was in the left CCA. The internal (ICA) and external carotid arteries were clamped and a transversal incision was made in the bulb. Through this carotid bulb access, an over-the-wire Fogarty balloon embolectomy catheter was advanced in a retrograde manner into the CCA and then into the arch, under fluoroscopic guidance. Some CCA thrombi were removed under fluoroscopic guidance. Extensive flushing of the CCA was performed. The same procedure was then performed at the right carotid bifurcation. The clot present on the right side was occluding the entire CCA and innominate trunk. After 45 min both carotid pulses were restored. The third step was fluoroscopically assisted thromboembolectomy of the right subclavian and axillary arteries. After clot removal the brachial pulse was restored. Through this arteriotomy, a 5F introducer sheath was placed in a retrograde manner and a pigtail catheter advanced into the arch. A completion angiogram demonstrated the patency of the supra-aortic branch vessels (Fig. 2). The 3 arteriotomies were finally sutured (6–0 polypropylene) after further extensive flushing. The fluoroscopy and the procedure took 5 and 110 min, respectively. A shunt was not used because the patient had both carotid arteries blocked



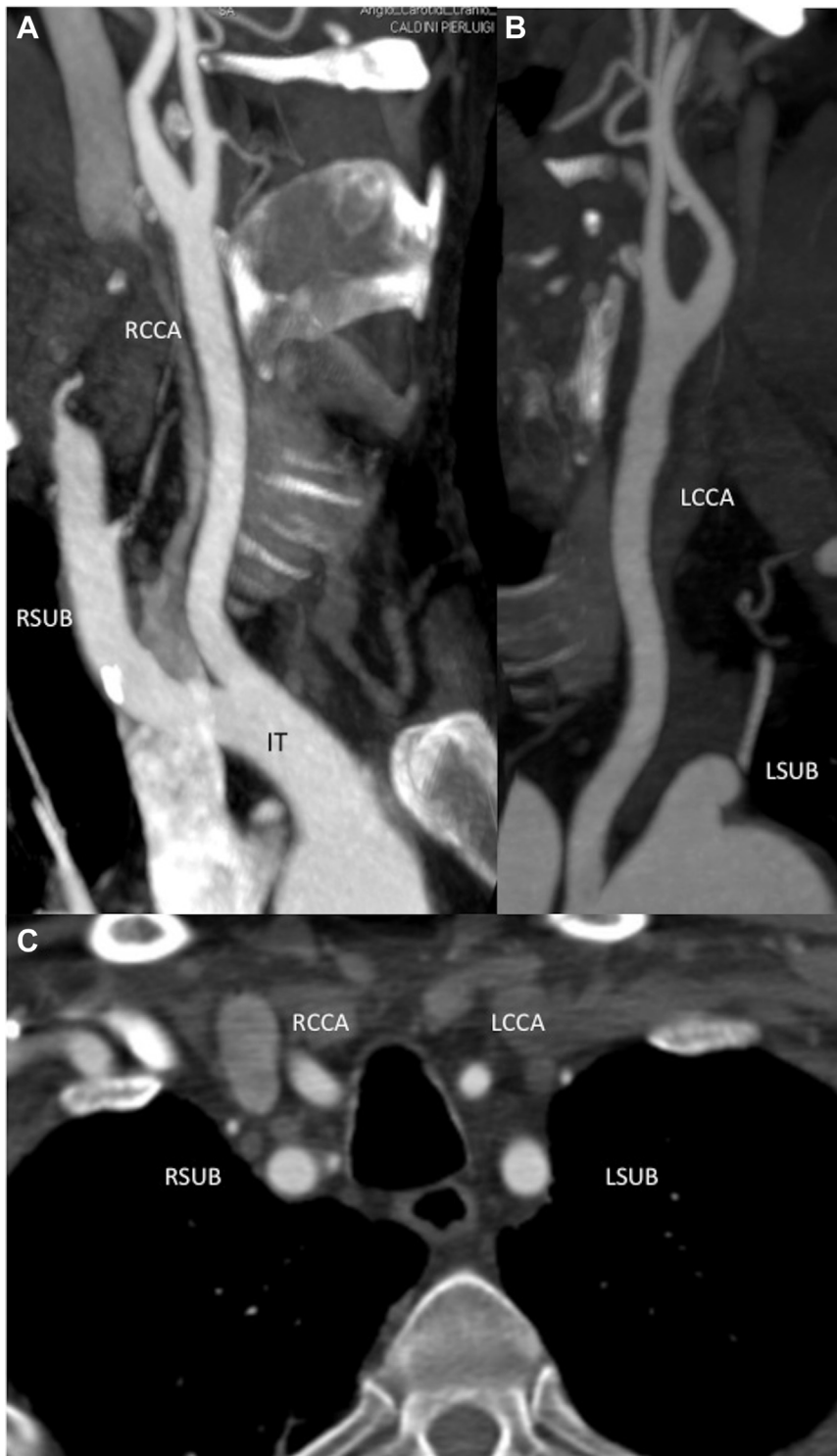
**Fig. 2.** Intraoperative pictures. **(A)** Fluoroscopically assisted thromboemblectomy of the right subclavian and axillary arteries. The Fogarty balloon (\*) and the vascular clamps positioned at the carotid bulbs are

shown. **(B)** Completion angiography demonstrating the patency of all supra-aortic branch vessels. **(C)** Removed clots arranged as they were located at the level of the supra-aortic vessels before hybrid surgery.

by the thrombus. The quantity of contrast agent (Iopromide 370 mg/mL) was 15 mL. After the procedure the patient was transferred to the intensive care unit, with extubation taking place on the first postoperative day, and was transferred to a general ward 2 days later. The patient underwent diagnostic tests for coagulopathy and right-to-left cardiac shunt (transesophageal echocardiogram with bubble study) and a CTA of the abdomen and thorax. All results were negative. The patient recovered completely from all neurologic signs, although a small ischemic lesion in the subcortical right parietal area was found at postoperative brain CTA. Moreover, the CTA showed the patency of all supra-aortic vessels and almost complete regression of the pulmonary embolism (Fig. 3). Discharge was on postoperative day 13, on warfarin. At the 3-month follow-up, the patient was doing well and living independently.

## DISCUSSION

Successful hybrid management of extensive thromboembolism of the supra-aortic vessels has never previously been reported in literature. One recently published case of extensive thromboembolic material involving the proximal aorta and brachiocephalic artery resulted in a major stroke and then death.<sup>7</sup> The etiopathogenesis of the pulmonary embolism in our case was DVT. Regarding the aortic arch embolism, 2 possible explanations can be postulated: (1) paradoxical embolism or (2) embolism from an untreated atrial fibrillation. Nevertheless, no right-to-left shunting was found by transesophageal echocardiogram with a bubble study or by angio-CT scan of the thorax and abdomen. Moreover, no further



**Fig. 3.** Postoperative axial and coronal (A–C) computed tomography sections showing patency of all supra-aortic vessels. IT, innominate trunk; LCCA, left common carotid

artery; LSUB, left subclavian artery; RCCA, right common carotid artery; RSUB, right subclavian artery.

cardiac abnormalities were found. It could be speculated that there was a right-to-left cardiac shunt that allowed for the passage of the thrombus under

particular conditions (i.e., prolonged and powerful Valsalva's maneuver), which were not reproducible during clinical tests especially during the bubble



study. Regarding the second hypothesis, we can assume that a large cardiac embolus, originating from the left atrium, stopped at the origin of the innominate trunk and the left CCA, then thrombus formation spread, especially at the level of the right carotid axis. This second explanation would be possible without the coexistence of a pulmonary embolism. In our opinion, we can honestly say that the patient's minor stroke was a cryptogenic stroke. Moreover, the literature is not conclusive on this issue.<sup>11–14</sup> This article suggests a therapeutic strategy for such an extensive thromboembolic scenario. In our opinion, hybrid surgery was the only possible solution. A purely endovascular approach to the acute carotid and innominate trunk thrombosis would have prompted concern regarding the risk of thrombus embolization during treatment. The intraluminal manipulation of guides and catheters, in association with thrombolysis, can cause the fragmentation of clots and subsequently increase the risk of distal intracerebral vessel occlusion. We believe that purely endovascular attempts to remove clots should be avoided and that surgical neck exploration, ICA clamping, and fluoroscopically assisted retrograde thromboembolectomy represent the only way to effectively protect the brain. Extensive flushing of the CCA to minimize the risk of embolization of debris from the CCA, as well as full anticoagulation therapy, was also important in achieving this aim. Thrombolysis was deemed inappropriate for the prompt resolution of this situation because of the large amount of thrombus. Full heparinization was necessary, even if postreperfusion hemorrhagic transformation in the brain can represent a risk. Furthermore, we need to protect the patient's pulmonary circulation from clot propagation, as large pulmonary emboli were occluding the main branches of the pulmonary arteries.

Symptomatic carotid lesions benefit from prompt intervention.<sup>9,10</sup> The preoperative work-up demands a fast protocol, including CTA and CDU scans and evaluation by a vascular surgeon and a neurologist, to identify patients who can safely undergo emergency surgical treatment.

In this case, the treatment was really hyperacute (<4 hr). We strongly believe that in similar cases, where extensive thrombus is blocking the origin of the main efferent cerebral vessels, surgery needs

to be performed as early as possible, as an emergency procedure, because of the very high risk of embolization.

In summary, we believe that the hybrid procedure described herein, performed in a hyperacute timeframe, offers a safe and effective option for stroke prevention in the case of acute massive thromboembolism of the supra-aortic cerebral vessels.

## REFERENCES

1. Sfyroeras GS, Karathanos C, Antoniou GA, et al. A meta-analysis of combined endarterectomy and proximal balloon angioplasty for tandem disease of the arch vessels and carotid bifurcation. *J Vasc Surg* 2011;54:534–40.
2. Hass WK, Fields WS, North RR, et al. Joint study of extracranial carotid occlusions, II: arteriography, techniques, sites and complications. *JAMA* 1968;201:961–8.
3. Collice M, D'Angelo V, Arenò O. Surgical treatment of common carotid occlusion. *Neurosurgery* 1983;12:515–24.
4. Belkin M, Mackey WC, Pessin MS, et al. Common carotid artery occlusion with patent internal and external carotid arteries: diagnosis and surgical management. *J Vasc Surg* 1993;17:1019–28.
5. Daly C, Rodriguez HE. Carotid artery occlusive disease. *Surg Clin North Am* 2013;93:813–32.
6. Klonaris C, Kouvelos GN, Kafeza M, et al. Common carotid artery occlusion treatment: revealing a gap in the current guidelines. *Eur J Vasc Endovasc Surg* 2013;46:291–8.
7. Okiwelu N, Joshi P, Passage J. Extensive clot propagation involving the aorta and brachiocephalic artery: unusual consequence of paradoxical embolism. *Eur J Cardiothorac Surg* 2014;45:757–8.
8. Rahme R, Abruzzo TA, Ringer AJ. Acute ischemic stroke in the setting of cervical carotid occlusion: a proposed management strategy. *World Neurosurg* 2011;76:S60–5.
9. Capoccia L, Sbarigia E, Speziale F, et al. The need for emergency surgical treatment in carotid-related stroke in evolution and crescendo transient ischemic attack. *J Vasc Surg* 2012;55:1611–7.
10. Leseche G, Alsac JM, Houbbalah R, et al. Carotid endarterectomy in the acute phase of stroke-in-evolution is safe and effective in selected patients. *J Vasc Surg* 2012;55:701–7.
11. Kouskov OS, Nichols DJ, O'Hearn DJ. Paradoxical arterial embolism involving both upper extremities in a patient with pulmonary embolism and a patent foramen ovale. *Clin Appl Thromb Hemost* 2011;17:98–101.
12. Rahman A, Jayasinghe R, Rajendran S. Paradoxical embolism via a patent foramen ovale: an important mechanism of cryptogenic strokes. *Circ Cardiovasc Imaging* 2008;1:9–10.
13. Furlan AJ, Jauss M. Patent foramen ovale and cryptogenic stroke: the hole story. *Stroke* 2013;44:2676–8.
14. Thaler DE, Saver JL. Cryptogenic stroke and patent foramen ovale. *Curr Opin Cardiol* 2008;23:537–44.